

**COMPARATIVE SOFT TISSUE MORPHOLOGY OF THE  
EXTANT HOMINOIDEA, INCLUDING MAN**

Thesis submitted in accordance with the requirements of the University of Liverpool

for the degree of Doctor of Philosophy

by

Sally Gibbs

**VOLUME II**

Hominid Palaeontology Research Group, Department of Human Anatomy and Cell  
Biology, The University of Liverpool, PO Box 147, Liverpool, L69 3BX

March 1999

### 3.4 UPPER LIMB AND SHOULDER GIRDLE

#### 3.4.1 MUSCLES

##### 3.4.1.1 Shoulder

###### *Deltoid*

In all apes and *Homo* the deltoid takes origin from the lateral third of the superior clavicular border, the lateral margin of the clavicle and the whole length of the inferior border of the scapular spine<sup>35, 89, 106</sup>. The acromial fibres may be absent in *Homo* as a variant<sup>106</sup>. In both species of *Pan*<sup>73, 88, 89, 108</sup> and *Pongo*<sup>86, 93</sup> deltoid has fibres of origin from the infraspinous fascia; in *Pan* also from the intermuscular septa with teres minor and major<sup>3</sup> and in *Pongo* also from the supraspinous fascia<sup>3, 93</sup>.

Deltoid is fused with the clavicular part of pectoralis major in 6/7 *Pan*<sup>3, 11, 23, 35, 63, 96</sup>, and with triceps in 2/3 *Pan*<sup>3, 38</sup>. The muscle is fused with brachialis in 3/4 *Pan*<sup>23, 38, 88</sup>, *Gorilla*<sup>82</sup>, and *Pongo*<sup>3</sup>. Fusion with neighbouring muscles occurs as a variant in *Homo*<sup>106</sup>.

In all apes and *Homo* the deltoid components converge to a tendon, inserting onto the region occupied in *Homo* by the deltoid tuberosity<sup>106</sup> on the lateral side of the middle of the humerus<sup>11, 35, 89</sup>. In no ape does it extend below the middle of the humeral shaft<sup>35</sup>. The insertion is more elongated in *Hylobates* than in great apes<sup>35</sup>.

In *Homo*, *Pan paniscus* and *Gorilla* the deltoid is innervated by the axillary (circumflex) nerve<sup>73, 82, 106</sup>.

##### 3.4.1.2 Arm

###### 3.4.1.2.1 Ventral

## *Biceps brachii*

In all apes and *Homo* biceps brachii has a double origin<sup>3, 73, 82, 89, 106</sup>, while in *Hylobates* the muscle may have only a single head<sup>72</sup>.

In great apes and *Homo*, the *short head* originates from the coracoid process of the scapula with coracobrachialis<sup>3, 73, 82, 93, 106</sup>. The origin is also shared with the coracohumeral ligament and the pectoralis abdominalis (3.3.1.1) in *Gorilla*<sup>82</sup>. The short head of *Hylobates* takes origin from the lesser tuberosity of the humerus, the proximal part of the bicipital groove and the medial intermuscular septum<sup>35, 44</sup>. This corresponds to a septal head<sup>46</sup>, which presents as a third bicipital head in 1/10 *Homo*, extending from the humerus to the belly of biceps<sup>53, 106</sup>.

The origin of the *long head* in all apes and *Homo* is from the region of the supraglenoid tubercle<sup>73, 82, 93, 106</sup>. However, in 1/6 *Pongo* where the supraglenoid tubercle is absent, the long head originates from the anterior surface of the scapula and the synovial sheath of the shoulder joint<sup>89</sup>. The long head in *Hylobates* originates from the apex of the glenoid fossa<sup>35</sup>.

In all apes and *Homo* the two bellies unite distally, inserting onto the radial tuberosity on the proximal radius<sup>3, 44, 73, 82, 88, 89, 93, 106</sup>. The unusual short head of *Hylobates* additionally inserts fleshily into the interfascicular septa of flexor digitorum superficialis, having an intimate relationship with the fasciculi of digits III and IV<sup>44</sup>, and the tendon of insertion also merges with the intermuscular fascia giving origin to flexor carpi radialis<sup>44</sup>.

The bicipital aponeurosis, blending with the fascia over the flexor muscles of the forearm and passing to the ulna, is absent from *Pongo*<sup>89, 93</sup>, while in African apes the aponeurosis is smaller than in *Homo*<sup>73, 82, 88, 115</sup>.

Innervated by a branch of the musculocutaneous nerve in all apes and *Homo*<sup>35, 50, 73, 82, 88, 89, 106</sup>.

### *Brachialis*

In all apes and *Homo* brachialis originates from the distal half of the anterior humerus<sup>3, 73, 82, 89, 93, 106</sup>, extending further proximally in *Pongo*<sup>89</sup>. In *Homo*, *Gorilla* and *Pongo* it also takes origin from the intermuscular septa<sup>3, 82, 106</sup>. In 1/5 *Pongo* the origin is split into two parts from the anteromedian and anterolateral surfaces of the humerus respectively, which then fuse distally<sup>89</sup>. Brachialis is fused with coracobrachialis in great apes<sup>3, 82, 89</sup>. This origin is distal to the insertion of the deltoid in *Homo*<sup>106</sup>, *Pan*<sup>3, 88</sup> and 1/5 *Pongo*<sup>93</sup>, interdigitates with this insertion in *Gorilla*<sup>82</sup> and 1/5 *Pongo*<sup>93</sup>, and lies proximal to this insertion in 3/5 *Pongo*<sup>3, 89</sup>.

In *Pan*, brachialis embraces a fascial band to pectoralis major<sup>88</sup>. In the right arm of a specimen of *Pan*, two 6 mm wide fleshy slips leave the centre of the anterior aspect of brachialis and ran distally to join the posterior aspect of biceps near its tendon of insertion<sup>115</sup>. Such slips are recorded as rare anomalies in *Homo*<sup>106, 115</sup>.

Insertion in great apes and *Homo* is into the ulnar tuberosity, on and distal to the coronoid process<sup>3, 73, 82, 88, 89, 93, 106</sup>. Some fibres in *Gorilla* and *Pongo* insert into the capsule of the elbow joint<sup>82, 89</sup>, and in *Pongo* it is continuous with the ligament binding the humerus and ulna<sup>3</sup>. In African apes there is a fasciculus from the proximolateral margin of brachialis to the fascia of the forearm<sup>82, 83, 88</sup>.

It is innervated by the musculocutaneous nerve in all apes and *Homo*<sup>35, 50, 73, 82, 88, 89, 106</sup>, in addition by the radial nerve in *Homo* and *Gorilla*<sup>35, 82, 106</sup> and also by the median nerve in *Gorilla*<sup>35, 82</sup>.

### *Coracobrachialis*

In all apes and *Homo* coracobrachialis originates from the coracoid process of the scapula<sup>3, 23, 63, 73, 82, 50, 88, 89, 106</sup>, in all but *Hylobates* along with the short head of biceps brachii<sup>3, 11, 23, 63, 82, 88, 89, 106, 112, 113</sup>. In African apes, and as a variation in *Homo*, it sends fibres to the intermuscular septum<sup>35, 88, 106</sup>, and in *Pan* alone to dorsoepitrochlearis<sup>23, 88</sup>.

A single muscle in *Homo*<sup>106</sup>, 3/15 *Pan*<sup>22, 63, 104</sup>, 1/5 *Gorilla*<sup>82</sup> and *Hylobates*<sup>35, 72</sup> it has two parts as a variation in *Homo*<sup>61</sup>, in 5/15 *Pan*<sup>3, 11, 23, 35, 88</sup> and in 4/5 *Pongo*<sup>35, 81</sup>. Three parts have been noted in 1/5 *Gorilla*<sup>35</sup>. The primitive coracobrachialis possessed 3 heads; coracobrachialis longus, brevis and medius<sup>112, 113</sup>. The brevis head of the muscle has disappeared in all apes and *Homo*<sup>35, 88, 89</sup>, except in a rudimentary form in *Gorilla*<sup>35</sup>. The single-headed coracobrachialis results from fusion of the medius and longus heads<sup>112, 113</sup>. In great apes coracobrachialis is fused with brachialis<sup>3, 82, 89</sup>, and in *Pan* alone with triceps<sup>3</sup>.

In all apes and *Homo* with the exception of *Gorilla*<sup>35, 50, 82</sup> and *Hylobates*<sup>35, 50</sup>, the musculocutaneous nerve passes through an interval in the muscle<sup>11, 14, 23, 35, 50, 73, 88, 89, 106</sup>.

In all apes and *Homo* the insertion of coracobrachialis is onto the medial surface of the humerus<sup>3, 23, 35, 50, 73, 82, 89, 96, 106</sup>, extending anteriorly in *Homo* and African apes<sup>23, 73, 82, 106</sup>. The insertion extends further distally in *Pan* and *Pongo*, attaining

the medial supracondyloid ridge<sup>3, 38</sup>, almost to the medial condyle<sup>38</sup>, which is a variation in *Homo*<sup>106</sup>. In *Pan* as part of a double insertion it may send muscular fibres into the brachial fascia<sup>23</sup>, while in *Pongo* it may insert additionally into the tendon of latissimus dorsi<sup>3</sup>.

In all apes and *Homo*, branches of the musculocutaneous nerve innervate coracobrachialis<sup>35, 50, 82, 88, 89, 106</sup>, with the exception of 1/3 *Gorilla*<sup>50</sup> and 1/2 *Hylobates*<sup>50</sup>. Branches of the median nerve also innervate coracobrachialis in *Pan*<sup>88</sup>.

#### 3.4.1.2.2 Dorsal

##### *Anconeus*

This is a small muscle, present in all apes and *Homo*<sup>3, 11, 35, 37, 73, 82, 93, 106, 115</sup>.

In *Homo* and great apes it originates from the dorsal surface of the lateral epicondyle of the humerus<sup>73, 82, 93, 106</sup>, additionally in *Homo* from the radial collateral ligament<sup>106</sup>.

In *Pan*, *Pongo* and *Hylobates* anconeus appears to be a continuation of the triceps<sup>3, 35, 73, 93</sup>. Anconeus was blended with fibres of extensor carpi ulnaris in *Hylobates*<sup>35</sup> and variably so in *Homo*<sup>106</sup>.

In *Homo* and great apes it inserts onto the dorsal ulna<sup>73, 82, 93, 106</sup>, extending laterally in *Gorilla*<sup>82</sup>.

Innervated by the radial nerve in *Homo*, *Pan paniscus* and *Gorilla*<sup>73, 82, 106</sup>, or by the ulnar nerve in *Pan*<sup>115</sup>.

### *Dorsoepitrochlearis*

In all apes, and in *Homo* when present, dorsoepitrochlearis originates from the tendon of latissimus dorsi<sup>4, 5, 7, 8, 17, 19, 24, 28, 34, 36, 38, 39, 42</sup>, in apes from the anteromedial aspect<sup>5, 10, 34, 38</sup>, 2.5 cm (*Pan, Gorilla, Pongo, Hylobates*<sup>15</sup>) to 5 cm (*Pan*<sup>5</sup>) before the insertion. It may originate from the junction of the belly and tendon in *Pan* and *Pongo*<sup>4, 36, 37, 45</sup>. In *Gorilla* it also takes origin from the lateral scapular border with the long head of triceps<sup>34</sup>.

A muscular dorsoepitrochlearis is present in around 5% of *Homo*<sup>3, 22</sup>, although a fibrous slip is usually present<sup>42, 45</sup>.

The muscle is described as being pierced by the ulnar nerve in *Gorilla* and *Pongo*<sup>6, 8</sup>. It receives fibres from coracobrachialis in *Pan*<sup>24, 36</sup>, but not *Pongo*<sup>37</sup>. Fibres of pronator teres arise from the inferior part of dorsoepitrochlearis in *Pan*<sup>5</sup>, while the distal part of dorsoepitrochlearis inserts into the intermuscular septum from which pronator teres arises in *Homo*<sup>5</sup>.

The insertion in all apes is into the medial humeral condyle<sup>4, 5, 10, 19, 24, 28, 34, 36, 38, 39, 45</sup>, in *Homo* and all apes into the medial intermuscular septum between the condyle and coracobrachialis<sup>15, 19, 36, 38</sup>. In *Homo* and great apes the insertion is connected with the long head of triceps<sup>5, 26, 42</sup>, and this forms the primary insertion in *Homo*, when present<sup>42</sup>.

Nerve supply in all apes (no information for *Homo*) is from a branch of the radial nerve<sup>5, 15, 28, 34, 38, 45</sup>, described in *Pan* and *Gorilla* as giving rise to the branch to the long head of triceps<sup>5, 34</sup>. Although dorsoepitrochlearis takes origin from latissimus

dorsi, it shares its nerve supply with triceps, and can be considered as a part of the latter muscle<sup>15, 28, 34, 45</sup>.

### *Triceps brachii*

In all apes and *Homo* triceps has three heads of origin<sup>3, 35, 63, 82, 89, 93, 106</sup>, while a 4th head is a frequent variation in *Homo*<sup>56</sup>.

The *long head* in all apes and *Homo* originates from the lateral border of the scapula adjacent to the glenoid fossa<sup>3, 38, 82, 89, 106</sup>, with a more distally extended origin in apes than in *Homo*<sup>35</sup>, involving a quarter to almost all of the border in *Pan*<sup>35, 63, 73, 88, 115</sup>, a third to a half in *Gorilla*<sup>35</sup> and *Hylobates*<sup>35</sup>, and a half in *Pongo*<sup>35, 89, 93</sup>. In *Pan* the long head also takes origin from the intermuscular septa<sup>3</sup>. An additional origin from the capsule of the shoulder joint is a rare variation in *Homo*<sup>106</sup>.

The *lateral head* in *Homo*, *Pan* and *Pongo* originates from the humerus just inferior to the humeral head and the insertion of teres minor<sup>3, 73, 88, 89, 93, 106</sup>. In *Homo* and *Pan* it also originates from the lateral intermuscular septum<sup>3, 106</sup>, and in *Pan* alone from the distal part of the capsule of the shoulder joint<sup>88</sup>.

The *medial head* in great apes and *Homo* originates further distally than the lateral head, on the posterior humerus distal to the insertion of teres major<sup>73, 82, 88, 89, 93, 106</sup>. In *Homo*, *Pan* and *Pongo*<sup>3, 93, 106</sup> it originates additionally from the intermuscular septum. The humeral origin is situated further proximally in *Pan* than in *Gorilla*<sup>35, 82</sup>.

Triceps is continuous with the anconeus in *Pan*<sup>38</sup> and *Pongo*<sup>89</sup>, and continuous with the deltoid in *Pan*<sup>63</sup>. The dorsoepitrochlearis is associated with the triceps muscle in great apes and as a variation in *Homo*<sup>5, 26, 38, 42</sup>. See 3.5.1.1.3 for further details.



The conjoined heads in great apes and *Homo* insert onto the proximal end of the ulnar olecranon<sup>73, 82, 88, 93, 106</sup>, in *Pan* and *Pongo* also giving fibres to the posterior wall of the elbow joint capsule<sup>88, 89</sup> and in *Homo* and African apes expanding to the fascia of the forearm<sup>23, 82, 106</sup>.

Innervated by the radial nerve in all apes and *Homo*<sup>35, 73, 82, 88, 89, 106</sup>. Part of the triceps is innervated by a branch of the ulnar nerve in *Pan*<sup>11</sup>.

### 3.4.1.3 Forearm

#### 3.4.1.3.1 Ventral

##### 3.4.1.3.1.1 Superficial layer

###### *Flexor carpi radialis*

In great apes and *Homo* flexor carpi radialis takes origin from the medial humeral epicondyle<sup>3, 82, 89, 93, 106</sup>. In all apes, and as a variation in *Homo*<sup>106</sup>, there is an additional origin from a fibrous septum attached to the oblique line of the radius, medial to the insertion of pronator teres<sup>3, 23, 27, 28, 35, 54, 82, 88, 89, 93, 115</sup>. In *Homo* and *Pan* there is an additional origin from the intermuscular septum<sup>3, 106</sup>, which in *Hylobates* also receives the insertion of the short head of biceps brachialis<sup>44</sup>. In *Pongo* alone there is an additional origin from the ulna in common with pronator teres<sup>93</sup>.

In great apes flexor carpi radialis may be fused with flexor digitorum superficialis<sup>82, 88, 89</sup>, and in *Pan* and *Pongo* with pronator teres<sup>88, 89</sup>.

Insertion in all apes and *Homo* is onto the palmar surface of the base of MII<sup>3, 23, 35, 82, 88, 89, 93, 106, 115</sup>. Further insertion to the palmar surface of the base of MIII is present

in *Homo*<sup>106</sup>, 5/10 *Pan*<sup>35, 88, 115</sup>, *Gorilla*<sup>35, 82</sup>, 3/7 *Pongo*<sup>35, 89</sup> and the single described *Hylobates*<sup>35</sup>. In African apes, and *Homo* as a variant, the insertion may display an extra tendon to the trapezium<sup>82, 106, 115</sup>.

Innervated by the median nerve in great apes and *Homo*<sup>82, 88, 89, 106</sup>.

### *Flexor carpi ulnaris*

In all apes and *Homo* flexor carpi ulnaris has a humeral origin from the medial epicondyle, and an ulnar origin from the olecranon and the superior two-thirds of the posterior ulnar surface<sup>3, 35, 73, 82, 88, 89, 93, 106</sup>. The aponeurotic origin from the posterior ulna may extend in *Pongo* almost to the distal end of the bone<sup>93</sup>. In all except *Hylobates* fibres also originate from the antebrachial fascia<sup>3, 82, 93</sup> and in *Homo*, *Pan*, and *Pongo* from the intermuscular septa<sup>3, 106</sup>. In *Pan* there may be a slip from the annular ligament<sup>23</sup>.

Insertion in all apes and *Homo* is onto the pisiform<sup>3, 23, 35, 73, 82, 88, 89, 93, 106</sup>. A double insertion may be present in *Pan* and *Gorilla*<sup>22, 23</sup>, and the insertion extends to the base of MV in *Homo* and *Pan paniscus*<sup>73, 106</sup>.

Relative to flexor carpi radialis, flexor carpi ulnaris is larger in *Pan* than in *Homo*<sup>69</sup>. The pisiform is also larger in *Pan*<sup>88</sup>. In *Pan* and *Pongo* flexor carpi ulnaris gives origin to some fibres for flexor digitorum superficialis<sup>23, 89, 93</sup>.

The muscle is supplied in all apes and *Homo* by the ulnar nerve<sup>11, 35, 73, 82, 88, 89, 106</sup>.

The ulnar nerve passes between the two heads in all apes<sup>23, 35, 82, 88, 89</sup>, with the exception of 1/5 *Pongo* in which it runs along the deep surface of the muscle<sup>93</sup>, as it does in *Homo*<sup>106</sup>.

### *Flexor digitorum superficialis*

In all apes and *Homo* flexor digitorum superficialis takes origin from the medial humeral epicondyle<sup>3, 14, 23, 35, 64, 82, 88, 89, 93, 106</sup>, and with the exception of 1/3 *Gorilla*, also from the coronoid process of the ulna<sup>23, 35, 63, 82, 88, 89, 106</sup>. The radial origin is present in all apes and *Homo*, with the exception of 2/13 *Pan*<sup>33, 62</sup> and as a variation in *Homo*<sup>56, 106</sup>. In *Homo* and African apes the humeroulnar head also takes origin from the intermuscular septum<sup>3, 23, 63, 106</sup>, and in *Homo* alone from the medial collateral ligaments of the elbow<sup>106</sup>.

It forms four tendons in all apes and *Homo*<sup>3, 35, 52, 89, 106</sup>.

The tendon for digit II in all apes and *Homo* arises from the humeroulnar head<sup>3, 23, 35, 63, 88, 89, 93, 106</sup>, with the exception of 1/13 *Pan*<sup>83</sup>, 1/6 *Pongo*<sup>89</sup> and *Hylobates*<sup>35</sup>, in which it arises from the radial head.

The tendon for digit III arises from the radial head in all apes and *Homo*<sup>3, 23, 35, 52, 63, 89, 93, 106</sup>, with the exception of *Homo*<sup>106</sup>, 1/13 *Pan*<sup>23</sup> and 1/6 *Pongo*<sup>93</sup> in which it arises from the humeroulnar head.

The tendon for digit IV originates from the radial head in all apes and *Homo*<sup>23, 35, 106</sup> except *Hylobates*, in which it arises from the ulnar head<sup>35</sup>, and *Homo*<sup>106</sup>, 1/13 *Pan*<sup>88</sup> and 1/6 *Pongo*<sup>89, 93</sup> in which it originates from the humeroulnar head.

The tendon for digit V in all apes and *Homo* is produced by the humeroulnar head<sup>23, 35, 88, 89, 93, 106</sup>. In general, the tendons in apes are more split than in *Homo*.

In *Pan*, the tendons for digits II, III and IV also receive fibres from flexor carpi radialis<sup>63</sup>, those for digits IV and V take origin from the intermuscular septum<sup>63</sup>, and that for digit III additionally from the brachial fascia<sup>63</sup>. Flexor digitorum superficialis

is fused with flexor carpi radialis in great apes<sup>82, 88, 89, 93</sup> and fused with flexor pollicis longus in *Gorilla*<sup>82</sup>. Flexor digitorum superficialis was also fused with flexor carpi ulnaris in *Pan* and *Pongo*<sup>88, 89, 93</sup>. A slip may connect flexor digitorum superficialis with flexor digitorum profundus for digits II and IV in *Pan*<sup>23</sup>. The tendon for digit II in 1/3 *Gorilla* is a separate muscle originating from the coronoid process<sup>82</sup>. In *Pan* this tendon may have two distinct heads with an incomplete tendinous intersection<sup>11, 63</sup>, which can be present as a variation in *Homo*<sup>63</sup>.

Many gibbons have flexor digitorum superficialis muscles that are slightly larger than flexor digitorum profundus, a condition not noted in great apes<sup>103</sup>.

Innervated by the median nerve in great apes and *Homo*<sup>82, 88, 89, 106</sup>.

#### *Palmaris longus*

When present, in all apes palmaris longus originates from the medial humeral epicondyle<sup>3, 63, 82, 93, 106</sup>. In *Homo* and *Pongo* the origin extends to the intermuscular septa<sup>93, 106</sup>.

Palmaris longus is present in 19/28 *Pan*<sup>11, 12, 13, 14, 23, 27, 28, 35, 45, 52, 83, 88, 104, 115</sup>, in 6/19 *Gorilla*<sup>45, 82, 104</sup>, all *Pongo*<sup>3, 14, 22, 27, 28, 35, 71, 93, 104</sup>, and all *Hylobates*<sup>25, 104</sup>. In *Homo*, the incidence of absence of palmaris longus is given as between 3.9% and 20.4%<sup>12, 56, 65</sup>.

Palmaris longus is fused with flexor carpi radialis and pronator teres in *Gorilla*<sup>82</sup>. A slender muscle, in *Pongo* it has been described as separating into three slips inserting into abductor pollicis brevis, the palmar fascia and flexor digiti minimi brevis<sup>27, 28</sup>.

In great apes and *Homo*, palmaris longus inserts into the deep fascia of the forearm<sup>3, 38, 93, 106</sup>, including an aponeurotic attachment to the radius, extending into the radial

carpal ligaments<sup>63, 82</sup>. The human attachment to the palmar aponeurosis is represented in *Pan* and *Pongo* by insertion into the palmar fascia<sup>3, 63, 93, 106</sup>.

Innervated by a branch of the median nerve in *Homo* and great apes<sup>82, 89, 106, 115</sup>.

### *Pronator teres*

In all apes and *Homo* pronator teres originates from the medial humeral epicondyle<sup>3, 12, 82, 88, 106</sup>. In *Homo*, *Pan* and *Pongo* it also takes origin from the medial intermuscular septum<sup>3, 88, 106</sup>. In *Homo*<sup>106</sup>, 5/9 *Pan*<sup>35, 62, 88</sup>, 1/4 *Gorilla*<sup>35, 82</sup>, and 3/7 *Pongo*<sup>35, 89, 93</sup> there is an ulnar origin from the coronoid process, which is absent from *Hylobates*<sup>35</sup>. The ulnar head may be absent from *Homo*<sup>106</sup>. In *Gorilla* there may be an additional origin from the capsule of the humeroulnar joint<sup>82</sup>, in 1/9 *Pan* from the distal part of the tendon of dorsoepitrochlearis<sup>11</sup>, and in *Pongo* from the radius<sup>3</sup>.

In *Pan*, and as a variation in *Homo*<sup>77, 88</sup>, the ulnar head is fused with flexor digitorum superficialis, while in *Pan* the proximal fibres insert into the supinator muscle<sup>88</sup>. In *Pan* and *Pongo*, the humeral head is fused with flexor carpi radialis<sup>3, 88, 89</sup>.

Insertion in all apes and *Homo* is to the middle of the lateral surface of the radius<sup>3, 11, 35, 82, 89, 93, 106, 115</sup>, extending anteriorly in *Hylobates*<sup>35</sup>.

Innervation of pronator teres is via the median nerve in great apes and *Homo*<sup>11, 13, 14, 23, 35, 82, 88, 89, 93, 106</sup>, and via the ulnar nerve in *Gorilla*<sup>82</sup>. The nerve in each case passes through an interval between the humeral and ulnar heads<sup>11, 13, 14, 35, 82, 88, 89, 93,</sup>

106

#### 3.4.1.3.1.2 Deep layer

### *Flexor digitorum profundus*

In all apes and *Homo* flexor digitorum profundus originates from the proximal two-thirds of the anterior ulnar surface and the interosseous membrane<sup>3, 11, 23, 35, 63, 73, 82, 88, 93, 103, 106</sup>. In *Homo* and *Gorilla* the origin extends proximally to the medial aspect of the coronoid process<sup>35, 103, 82, 106</sup>, while in *Hylobates* and *Homo* as a variation, the muscle attaches to the medial humeral condyle<sup>35, 103, 106</sup>. Fibres of origin from the aponeurosis of flexor carpi ulnaris are present in *Homo*, *Pan* and *Pongo*<sup>88, 89, 106</sup>, also attaching to deep fascia in *Pongo*<sup>89</sup>. In all apes, there is an additional bony origin from the proximal two-thirds of the anterior radial surface<sup>3, 23, 35, 63, 73, 82, 93, 103</sup>, in great apes extending to the intermuscular septum<sup>3, 63, 82</sup>.

The radial part (humeroradial in *Hylobates*<sup>35</sup>) corresponds to the flexor pollicis longus of *Homo*<sup>106</sup>. In those great apes in which a true flexor pollicis longus is not present, this radial part inserts onto the distal phalanx of digit II<sup>3, 22, 35, 38, 63, 73, 93</sup>, occasionally inserting in addition onto digit I<sup>22, 35</sup>. In *Hylobates*, the radial part also inserts onto digit III<sup>35</sup>.

The ulnar part in all apes and *Homo* inserts onto the bases of the distal phalanges of digits IV and V<sup>3, 11, 23, 35, 52, 63, 73, 82, 88, 93, 106</sup> and in great apes and *Homo* also onto digit III<sup>3, 23, 35, 52, 63, 73, 82, 88, 93, 106</sup>. *Homo* and *Pan* alone share an insertion of this ulnar part onto digit II<sup>23, 106</sup>. Slips may connect the terminal tendons of digits III and IV, or IV and V in *Homo*<sup>106</sup> and *Pan*<sup>52, 63</sup>.

Innervation in all apes and *Homo* is jointly from branches of the median nerve and the ulnar nerve<sup>11, 35, 73, 82, 88, 89, 106</sup>.

### *Flexor pollicis longus*

In African apes and *Homo* flexor pollicis longus originates from the anterior radius and the interosseous membrane<sup>3, 19, 35, 66, 82, 88, 106</sup>. In *Homo*<sup>106</sup> the origin is from the middle half of the radius, and in *Pan* from almost the whole length<sup>88</sup>. In *Pan* it also takes origin from the intermuscular septum<sup>3</sup>, in *Gorilla* and *Pongo* from the carpus<sup>19, 35</sup> and in the African apes it may originate from the palmar fascia<sup>38, 40, 52, 115</sup>.

A slender muscle<sup>10, 19, 82</sup>, in all apes it is usually attached to the flexor digitorum profundus<sup>11, 13, 14, 22, 23, 35, 38, 82, 92, 104</sup>, but is independent in *Homo*<sup>106</sup>, 1/43 *Pan*<sup>52</sup> and 2/9 *Pongo*<sup>14</sup>. In these apes it may appear to arise from the areolar tissue between flexor digitorum superficialis and flexor digitorum profundus<sup>10</sup>. A long flexor tendon to the pollex from flexor digitorum profundus is absent from 13/43 *Pan*<sup>19, 45, 66, 92, 104</sup>, 11/23 *Gorilla*<sup>7, 12, 35, 45, 66</sup>, 3/9 *Pongo*<sup>13, 14, 27, 28, 45, 89</sup> and as a variation in *Homo*<sup>106</sup>.

In great apes and *Homo* the muscle inserts onto the base of the distal phalanx of the pollex<sup>10, 23, 35, 38, 40, 82, 88, 104, 106, 115</sup>. An additional tendon from flexor pollicis longus to digit II may be present in *Pan*<sup>3, 11, 35, 88, 115</sup>, 1/5 *Hylobates*<sup>45</sup> and as a variation in *Homo*<sup>35, 63, 115</sup>.

McMurrich<sup>64</sup> and Keith<sup>45</sup> conclude that when absent, the flexor pollicis longus should be regarded as still undifferentiated from the radial element of flexor profundus. Gradually the portion associated with the thumb increases, and dissociates from the part belonging to digit II until the pollical portion grows large enough to be a true flexor pollicis longus<sup>35</sup>.

Innervated by the median nerve in *Homo* and African apes<sup>11, 82, 106</sup>. In *Homo* and *Pan*, the innervation is by one, or frequently two branches from the anterior interosseous branch of the median nerve<sup>11, 66, 106</sup>.

### *Pronator quadratus*

In great apes and *Homo* pronator quadratus takes origin from the distal anterior part of the ulna<sup>3, 23, 73, 82, 88, 89, 93, 106</sup>.

A small thin muscle<sup>12, 35, 82</sup>, the direction of the muscle fibres is more oblique in Asian apes than in African apes, and least oblique of all in *Homo*<sup>12, 23, 35, 82</sup>. It forms two layers in *Pan*<sup>23</sup>, and two parts in *Gorilla*, in which the distal part is smaller and more oblique, and the proximal part is larger and less oblique<sup>82</sup>.

Insertion in great apes and *Homo* is to the distal anterior radius<sup>3, 73, 82, 88, 89, 93, 106</sup>. In *Pan* pronator quadratus inserts in addition into the joint capsule of the wrist and onto the ridge of the trapezium<sup>23</sup>.

Innervated by anterior interosseous branches of the median nerve in *Homo*, *Pan paniscus*, *Gorilla* and *Pongo*<sup>73, 82, 89, 106</sup>, but by the posterior interosseous branch of the radial nerve in *Hylobates*<sup>35</sup>.

### 3.4.1.3.2 Dorsal

#### 3.4.1.3.2.1 Superficial group

### *Brachioradialis*

This muscle originates in all apes and *Homo* from the lateral supracondylar crest of the humerus and the intermuscular septum<sup>3, 35, 73, 82, 88, 89, 90, 93, 106, 115</sup>, originating more distally in *Homo*<sup>106</sup> and *Hylobates*<sup>90</sup> than in the great apes<sup>13, 14, 35, 90, 115</sup>.



The muscle is fused with brachialis anticus in both species of *Pan*<sup>35</sup> and *Hylobates*<sup>35</sup>, and with coracobrachialis in *Pongo*<sup>3</sup>. In the latter it also gives origin to flexor carpi radialis<sup>93</sup>.

Insertion in all except *Hylobates* is onto and above the lateral surface of the radial styloid process<sup>3, 35, 73, 82, 88, 89, 93, 115</sup>. The insertion in *Hylobates* does not reach the styloid process<sup>35, 90</sup>, although still on the anterolateral surface of the radial shaft, extending further proximally than in all except *Pongo*<sup>35, 89, 90</sup>.

The muscle is innervated by the radial nerve in *Homo* and great apes<sup>73, 82, 89, 90, 106,</sup>

115

#### *Extensor carpi radialis brevis*

In all apes and *Homo* extensor carpi radialis brevis originates by a common head with the other extensor muscles from the lateral humeral epicondyle<sup>3, 73, 82, 88, 89, 90,</sup>

<sup>93, 106</sup>. In *Homo*, *Pan* and *Pongo* it also takes origin from the radial collateral

ligament<sup>35, 88, 89, 90, 106</sup> and in *Homo* and *Pongo* from the intermuscular septum<sup>3, 89,</sup>

<sup>106</sup> *Pan* has a origin from the fascia over extensor digitorum<sup>88</sup>, and *Pongo* from the fascia over supinator<sup>3</sup>.

In *Homo*<sup>106</sup> and *Pan*<sup>3</sup> the muscle becomes tendinous about midway down the forearm, while in *Gorilla*<sup>82</sup> and *Pongo*<sup>3, 93</sup> this point is much nearer the wrist. Fusion of this muscle with extensor carpi radialis longus is present in 22% of *Homo*<sup>105</sup>, and in occasional specimens of *Pan*<sup>3, 88</sup>, *Pongo*<sup>3</sup> and *Hylobates*<sup>90</sup>. In all apes and *Homo* the muscle runs deep to abductor pollicis longus<sup>82, 90, 93, 106</sup>.

The insertion is onto the dorsoradial base of MIII in all apes and *Homo*<sup>3, 73, 82, 88, 89,</sup>

<sup>90, 93, 106</sup>, while additional insertion to MII is present in *Gorilla*<sup>82</sup> and *Hylobates*<sup>48</sup> to

MII alone in *H.pileatus*<sup>90</sup>, and as a variant in 1.5-32% of *Homo*<sup>43, 82, 90, 105, 106, 109-114</sup>.

Additional insertion to MI is occasionally present in *Pongo*<sup>71</sup> and as a rare variation in *Homo*<sup>90</sup>.

Innervated by branches of the radial nerve in *Homo*, *Pan paniscus* and *Gorilla*<sup>35, 73, 82, 106</sup>, specifically the posterior interosseous branch of the radial nerve in *Homo*<sup>106</sup>.

#### *Extensor carpi radialis longus*

This muscle originates in all apes and *Homo* from the lateral supracondylar crest, and the lateral intermuscular septum as far as the lateral humeral epicondyle<sup>3, 35, 73, 82, 88, 89, 90, 93, 106</sup>.

In all apes and *Homo* the muscle runs with extensor carpi radialis brevis, and is crossed by the pollical extensor tendons<sup>3, 35, 82, 88, 89, 93, 106</sup>. The tendinous part of the muscle is longer than the fleshy part in all except *Pongo*<sup>35, 82, 93</sup>. Fusion of this muscle with extensor carpi radialis brevis is present in 22% of *Homo*<sup>105</sup>, and in occasional specimens of *Pan*<sup>3, 88</sup>, *Pongo*<sup>3</sup> and *Hylobates*<sup>90</sup>.

In all apes and *Homo* it inserts onto the dorsolateral aspect of the base of MII<sup>3, 35, 73, 82, 88, 89, 90, 93</sup>, occasionally extending to the proximal centimetre of the shaft in *Pan*<sup>88</sup>.

An accessory tendon to MI is present in 4.5- 12.5% of *Homo*<sup>35, 90, 56, 109-114</sup>, and has been found in 4/8 *Hylobates*<sup>35, 90</sup>. *Homo* may also have an accessory attachments to the carpus or the radius; these are not found in other apes<sup>90</sup>.

Innervated by the radial nerve in all apes and *Homo*<sup>35, 73, 82, 88, 89, 106</sup>.

### *Extensor carpi ulnaris*

In all apes and *Homo* extensor carpi ulnaris originates from the lateral humeral epicondyle and the ulna<sup>3, 35, 73, 82, 89, 90, 93, 106</sup>.

The muscle in all apes and *Homo* inserts onto the ulnar surface of the base of MV<sup>3, 35, 73, 82, 89, 90, 93, 106</sup>.

The metacarpal insertion is onto the ulnar aspect of the dorsal surface in African apes<sup>82, 90</sup>, the ulnar surface in *Homo* and *Hylobates*<sup>90, 106</sup>, and the ulnar aspect of the volar surface in *Pongo*<sup>90</sup>. A prolongation to the first phalanx of digit V has been found in a single specimen of *Pan*<sup>62</sup>, which is present in less than 10% of *Homo*<sup>56, 60, 62, 109-114</sup>.

Innervated by branches of the radial nerve in *Homo*, *Pan paniscus* and *Gorilla*<sup>73, 82, 106</sup>.

### *Extensor digiti minimi*

In all apes and *Homo* with the exception of *Pan*, extensor digiti minimi originates from the intermuscular septum<sup>35, 82, 88, 89, 90, 93, 106</sup>. In all except *Hylobates*<sup>35</sup> and occasionally in *Gorilla*<sup>35</sup> the bony origin is from the lateral humeral epicondyle with extensor digitorum<sup>2, 73, 89, 93</sup>. An ulnar origin may be present in *Homo*, *Pan* and Asian apes<sup>63, 90</sup>.

Absence of the entire muscle has been reported in 2-5% of *Homo*<sup>56</sup>, 3★/31 *Pan*<sup>3, 11</sup> and 1/23 *Pongo*<sup>90</sup>.

Insertion in all apes and *Homo* is to the dorsal aponeurosis of digit V<sup>2, 11, 13, 62, 63, 73, 90, 106</sup>, although *Pongo* shows an additional tendon to digit IV in 20/23 cases<sup>2, 3, 14, 35</sup>.

89, 90, 93, and this is present in 6-11% of *Homo*<sup>56, 79, 90, 106, 109-114</sup>, 5/31 *Pan*<sup>23, 90</sup>, and 1/14 *Gorilla*<sup>90</sup>.

Restriction to digit V is normal for *Homo* (89-94%), *Pan* (73%), *Gorilla* (93%) and *Hylobates* (12/12)<sup>90</sup>.

Innervated by branches of the radial nerve in *Homo*, *Pan paniscus* and *Gorilla*<sup>73</sup>,  
82,106

### *Extensor digitorum*

In all apes and *Homo* extensor digitorum originates from the lateral humeral epicondyle<sup>3, 63, 73, 88, 89, 93, 106</sup>. *Homo*, *Pan*, and *Pongo* share an origin from the intermuscular septa<sup>3, 63, 88, 89, 106</sup>, *Pan* and *Pongo* from the interosseous membrane<sup>3</sup>,<sup>63, 88, 89</sup> and great apes occasionally show a double origin from the radius and ulna<sup>63</sup>,<sup>89, 90, 93</sup>, more commonly the ulna alone in Asian apes<sup>2, 90, 93</sup>. *Homo* alone has an origin from the ligaments of the elbow<sup>106</sup>, but shares with *Pan* an origin from the antebrachial fascia<sup>3, 88, 106</sup>.

The tendon for digit IV sends a slip to that for digit V in *Homo*<sup>106</sup>, African apes<sup>3, 11, 23, 35</sup>,<sup>63, 73, 82, 88, 90</sup> and *Hylobates*<sup>35</sup>, and sends a slip to that for digit III in *Homo* and great apes<sup>3, 11, 83, 90, 106</sup>. A connection between digits III and II in *Homo* is weak, and may be absent<sup>58</sup>. These interconnections may constrain independent extension of the digits<sup>106</sup>.

The insertion of the muscle is by tendons into the bases of the proximal phalanges of digits II to V in all apes and *Homo*<sup>2, 3, 14, 52, 63, 73, 82, 88, 89, 90, 103, 106</sup>, although the tendon to digit V is absent from approximately 27% of *Homo*<sup>39, 63, 105</sup> and occasionally absent from *Pan*<sup>90, 104</sup> and Asian apes<sup>90, 93</sup>. The insertion in great apes

may extend to the middle or distal phalanges<sup>3, 73, 82, 88, 93</sup>. While *Homo* shows an insertion into the capsules of the metacarpophalangeal joints<sup>106</sup>, *Pan* and *Pongo* share an insertion into the interphalangeal joints<sup>88, 93</sup>.

Innervated by branches of the radial nerve in *Homo*, *Pan paniscus*, and *Gorilla*<sup>73, 82,</sup>

106

### 3.4.1.3.2.2 Deep group

#### *Abductor pollicis longus*

In all apes and *Homo* abductor pollicis longus originates from the dorsal ulna, interosseous membrane and dorsal radius<sup>3, 63, 73, 82, 88, 90, 93, 106</sup>. *Pan* and *Pongo* also show an origin from the intermuscular septum<sup>3, 63</sup>.

The muscle is variably fused with abductor pollicis longus at origin in all apes and *Homo*<sup>3, 20, 23, 25, 35, 52, 76, 78, 79, 82, 87, 88, 97, 105, 106, 115</sup>.

The insertion of this muscle is complex and variable. In all apes and *Homo*, there is always an insertion to the base of MI<sup>2, 11, 35, 38, 52, 63, 73, 78, 82, 89, 90, 93, 103, 104</sup>.

An insertion to the trapezium is present in around 58% of *Homo*<sup>78, 90</sup>, 39/39 *Pan*<sup>3, 10, 11, 23, 35, 62, 63, 73, 88, 90, 104, 115</sup>, 11/19 *Gorilla*<sup>82, 90</sup>, 17/23 *Pongo*<sup>2, 10, 35, 90, 93</sup> and 12/15 *Hylobates*<sup>10, 35, 90</sup>.

A radial sesamoid bone, which is usually absent from *Homo*<sup>90, 115</sup> and *Gorilla*<sup>57</sup>, forms a point of insertion in 11/39 *Pan*<sup>3, 10, 23, 35, 88, 90, 115</sup>, 1/19 *Gorilla*<sup>90</sup>, 6.5/23 *Pongo*<sup>35, 89, 90</sup>, and 10/15 *Hylobates*<sup>10, 35, 90</sup>.

From the literature, the most common pattern of insertion is to all three osseous structures in *Hylobates*, and to MI and the trapezium in great apes and *Homo*.

Insertion onto all 3 structures never occurs in *Homo* or *Gorilla*<sup>90</sup>, while insertion onto MI alone never occurs in *Pan*<sup>90</sup>. Additionally, insertion onto the scaphoid bone has been reported in *Pan*<sup>10, 38</sup>.

	<i>Homo</i>	<i>Pan</i>	<i>Gorilla</i>	<i>Pongo</i>	<i>Hylobates</i>
MI, trapezium, sesamoid	-	28%	-	15%	47%
MI, trapezium	58%	72%	58%	59%	27%
MI, sesamoid	-	-	5%	13%	20%
MI	37-42%	-	37%	13%	6%

**Table 3.4.1. Variation in the osseous insertion of abductor pollicis longus in hominoids.**

Innervated in *Homo*, *Pan paniscus* and *Gorilla* by branches of the radial nerve<sup>73, 82, 106</sup>.

#### *Extensor indicis*

In all apes and *Homo* extensor indicis originates from the dorsal ulna<sup>3, 63, 73, 82, 90, 93, 106</sup>. *Homo* and Asian apes share an additional origin from the interosseous membrane<sup>3, 90, 93, 106</sup>. Origins from the distal radius and the intermuscular septum have been described in *Pan* and *Pongo*<sup>3, 88, 93</sup>.

It has been described as small or absent in great apes<sup>7, 22, 34, 47, 49, 55, 70, 90</sup>, but is rarely absent from *Homo*<sup>31, 56, 98, 105</sup>.

In addition to dorsal aponeurotic digital insertions, all apes except *Gorilla* occasionally show slips to the dorsal aspect of the base of the 1st phalanges<sup>3, 35, 63, 93</sup>. Extensor indicis in *Gorilla* has been described as inserting onto the dorsal hamate and the capitate<sup>82</sup>.

The insertion of extensor indicis is fairly complex. The most common pattern of insertion in *Homo* and African apes is digit II alone<sup>3, 23, 35, 38, 63, 73, 82, 88, 90, 106, 108</sup>, in *Pongo* digits II and III<sup>3, 25, 89, 90</sup>, and in *Hylobates* digits II, III and IV<sup>25, 90</sup>.

	<i>Homo</i>	<i>Pan</i>	<i>Gorilla</i>	<i>Pongo</i>	<i>Hylobates</i>
II, III, IV, V	-	-	-	5%	7.5%
II, III, IV	very rare	4%	-	11%	92%
II, III	5-13%	21%	-	66%	-
II, IV	-	4%	-	-	-
III	-	4%	-	13%	-
II	87-95%	68%	100%	5%	-

Table 3.4.2. Variations in the insertion of extensor indicis in hominoids. Adapted from data in <sup>90</sup>.

Innervated by the radial nerve in *Homo*, *Pan paniscus* and *Gorilla*<sup>73, 82, 106</sup>, specifically by the posterior interosseous branch of the radial nerve in *Homo*<sup>106</sup>.

### *Extensor pollicis brevis*

When present, in all apes and *Homo* extensor pollicis brevis originates from the distal radius<sup>3, 35, 88, 106</sup>, in African apes and *Homo* it also takes origin from the interosseous membrane and in African apes, and rarely in *Homo*, from the ulna distal to abductor pollicis longus<sup>3, 82, 88, 90, 106</sup>. The muscle is variably fused with abductor pollicis longus at origin in all apes and *Homo*<sup>3, 20, 23, 25, 35, 52, 76, 78, 79, 82, 87, 88, 97, 105, 106, 115</sup>. In *Pan*, the muscle also takes origin from the intermuscular septa<sup>3</sup>.

Extensor pollicis brevis is absent from 1-6% of *Homo*<sup>78, 105, 109-114</sup>, 6/14 *Pan*<sup>2, 11, 13, 47, 73, 90</sup>, 8/18 *Gorilla*<sup>2, 90</sup>, 3/6 *Pongo*<sup>2, 14, 90</sup> and 14/15 *Hylobates*<sup>90</sup>.

The insertion in *Homo* and *Gorilla* is to the base of the proximal phalanx of digit I<sup>35, 82, 90, 103, 106</sup>. In all apes, the muscle inserts onto the lateral base of MI<sup>3, 22, 23, 35, 38, 52, 82, 88, 89, 115</sup>.

Innervated by the radial nerve in *Homo* and *Gorilla*<sup>82, 106</sup>, specifically by the posterior interosseous branch of the radial nerve in *Homo*<sup>106</sup>.

Extensor pollicis brevis should perhaps apply only to the part of the muscle complex which inserts upon the phalangeal part of the thumb<sup>90</sup>, but Ziegler believes this is unreasonable in view of the general variability of muscle insertions<sup>115</sup>.

### *Extensor pollicis longus*

In all apes and *Homo* extensor pollicis longus originates from the proximodorsal ulna and the interosseous membrane<sup>2, 3, 11, 23, 73, 82, 88, 90, 93, 106</sup>. In *Pan* it also takes origin from the intermuscular septa<sup>3</sup>.

Extensor pollicis longus is absent from 1.5% of *Homo*<sup>78</sup>. Kohlbrügge concluded that extensor pollicis longus is smaller in great apes than in *Homo*<sup>49</sup>, but it is not true of all individuals, and the muscle can also be poorly developed in *Hylobates*<sup>91</sup>.

The muscle inserts onto the base of the distal phalanx of the pollex in all apes and *Homo*<sup>2, 3, 23, 38, 73, 82, 88, 89, 90, 93, 106, 115</sup>. All apes also show an insertion as an expansion or slip to the base of the proximal phalanx of the pollex<sup>11, 35, 82, 89, 90, 93, 115</sup>, and this occurs as a variant in *Homo*<sup>78</sup>. *Gorilla* occasionally has a slip to digit II<sup>35</sup>, and the tendon in *Pongo* may attain insertion via the capsule of the metacarpophalangeal joint<sup>90, 93</sup>.

Innervated by the radial nerve in *Homo*, *Pan paniscus* and *Gorilla*<sup>73, 82, 106</sup>, specifically by the posterior interosseous branch of the radial nerve in *Homo*<sup>106</sup>.

### *Supinator*

In all apes and *Homo* supinator originates from the supinator crest on the proximal ulna<sup>3, 73, 82, 90, 93, 106</sup>, and also (variably in *Pongo*) from the lateral humeral epicondyle<sup>73, 82, 90, 93, 106</sup>. An origin from the ligaments of the elbow joint is present in *Homo*<sup>106</sup>, *Gorilla*<sup>82</sup> and *Pongo*<sup>3</sup>.



Supinator comprises about 7% of total antebrachial musculature in great apes, 6% in hylobatids and less than 5% in *Homo*<sup>103</sup>. *Homo* is highly significantly different from hylobatids and great apes, but there appears to be no significant differences between apes<sup>103</sup>. In 1/7 *Pan*, rather than being embedded in the supinator muscle as in *Homo* and all other apes<sup>11, 13, 82, 88, 89, 90, 106</sup>, the posterior interosseous nerve was covered by fascia on the surface of the muscle<sup>35</sup>.

The insertion is onto the proximal radius in all apes and *Homo*, extending further distally in apes<sup>3, 73, 82, 88, 89, 90, 93, 106, 115</sup>.

In all apes and *Homo* the muscle is pierced and innervated by the deep branch of the radial nerve<sup>11, 35, 73, 82, 88, 89, 90, 106</sup>.

#### 3.4.1.4 Hand

##### 3.4.1.4.1 Hypothenar

The hypothenar musculature constitutes a similar percentage of the total hand musculature in *Homo* and *Pan*<sup>103</sup>.

##### *Palmaris brevis*

Data on palmaris brevis are sparse. In *Homo* and *Gorilla* the muscle originates from the annular ligament<sup>82, 106</sup>, and in *Homo* and both species of *Pan* from the palmar fascia<sup>13, 73, 106</sup><sup>35, 82</sup>. In *Gorilla* alone it also originates from the pisiform<sup>82</sup>.

It is absent from 1/5 *Pan*<sup>35</sup>, from 1/2 *Gorilla*<sup>35</sup> and from single specimens of *Pongo* and *Hylobates*<sup>35</sup>. In *Homo* and *Gorilla* the muscle is described as flat<sup>82, 106</sup>, although in *Gorilla* the muscle has a triangular apex at insertion, and the pisiform part is

almost longitudinal<sup>82</sup>. Raven comments that palmaris brevis appears to be a specialized split from abductor digiti minimi<sup>82</sup>.

In African apes and *Homo* it inserts onto the skin of the ulnar border of the palm<sup>73, 82, 106</sup>.

Innervation in *Homo*, *Pan paniscus* and *Gorilla* is via the superficial branch of the ulnar nerve<sup>73, 82, 106</sup>.

### *Abductor digiti minimi*

Abductor digiti minimi originates in all apes and *Homo* from the pisiform bone<sup>35, 73, 82, 88, 93, 106</sup>. In *Homo* alone it also takes origin from the pisohamate ligament and the tendon of flexor carpi ulnaris<sup>106</sup>.

*Pan* and *Pongo* differ in the proportions of the muscle; a short belly and long tendon is present in *Pan*, while in *Pongo* the muscle has a long belly and a short tendon<sup>89</sup>. In all it lies along the ulnar border of the palm<sup>35, 82, 88, 93, 106</sup>.

In all apes and *Homo* the muscle inserts onto the ulnar margin of the base of the proximal phalanx of digit V<sup>35, 73, 82, 88, 93, 106</sup>. In apes the insertion is blended with the insertion of flexor digiti minimi brevis<sup>35, 88</sup> which may occur as a variation in *Homo*<sup>106</sup>. The muscle also partly radiates into the extensor aponeurosis of digit V in *Homo* and *Pan paniscus*<sup>73, 106</sup> and inserts into the capsule of the metacarpophalangeal joint in *Gorilla*<sup>82</sup>.

Innervated by the ulnar nerve in *Homo*, *Pan paniscus* and *Gorilla*<sup>73, 82, 106</sup>.

### *Flexor digiti minimi brevis*

In all apes and *Homo* flexor digiti minimi brevis originates by a single head from the flexor retinaculum and the hamulus of the hamate bone<sup>35, 73, 82, 88, 93, 106</sup>. In all apes the origin is closely blended with that of opponens digiti minimi<sup>35, 82, 88</sup>.

Flexor digiti minimi brevis may be absent from *Homo*<sup>106</sup>.

Insertion in all apes and *Homo* is onto the palmar surface of the base of the proximal phalanx of digit V in common with abductor digiti minimi<sup>11, 29, 35, 73, 82, 88, 93, 106</sup>, while in *Hylobates* it may send tendinous extensions to fibrous structures at the distal end of the proximal phalanx or base of the middle phalanx<sup>29, 35</sup> and a weak tendon may continue from the base of the middle phalanx into the pulp of digit V<sup>29</sup>. In *Gorilla* it also inserts into the capsule of the metacarpophalangeal joint, and has an aponeurotic expansion to the extensor tendon on the dorsal surface<sup>82</sup>.

Innervated by the ulnar nerve in *Homo*, *Pan paniscus* and *Gorilla*<sup>73, 82, 106</sup>.

### *Opponens digiti minimi*

In all apes and *Homo* opponens digiti minimi originates from the flexor retinaculum, and the hamulus of the hamate bone<sup>35, 73, 82, 88, 93, 106</sup>. The origin is blended with that of flexor digiti minimi brevis in all apes<sup>35, 82, 88</sup>.

The deep ulnar nerve and vessels pass over the dorsal surface of the muscle in all apes and *Homo*<sup>35, 106</sup>.

It crosses obliquely ulnarwards to insert onto the ulnar margin of MV in all apes and *Homo*<sup>35, 73, 82, 88, 93, 106</sup>, extending ventrally in *Gorilla*<sup>82</sup>.

Innervated by the ulnar nerve in *Homo*, *Pan paniscus* and *Gorilla*<sup>73, 82, 106</sup>.

### 3.4.1.4.2 Thenar

#### *Abductor pollicis brevis*

In all apes and *Homo* abductor pollicis brevis originates from the scaphoid tubercle and the radial superior aspect of the flexor retinaculum<sup>10, 23, 35, 73, 82, 88, 89, 106</sup>. Fibres of origin from the trapezium may be present in *Homo* and great apes<sup>2, 82, 93, 106</sup>.

The muscle divides into slips in 2/4 *Pan*<sup>10, 23, 82</sup> and *Gorilla*<sup>82</sup>, and may be reinforced by slips from flexor pollicis brevis in *Pan*<sup>23</sup> and *Hylobates*<sup>10</sup>. 23 10

The insertion in all apes and *Homo* is to the radial sesamoid bone and the proximal phalanx of the pollex<sup>10, 23, 35, 73, 82, 88, 93, 106</sup>, extending to the middle or distal phalanx in 2/6 *Pan*<sup>23, 35</sup>. The insertion may include MI in *Pan*<sup>2, 52</sup>, *Gorilla*<sup>82</sup>, and *Hylobates*<sup>35</sup>.

Innervation in all apes and *Homo* is via the median nerve<sup>10, 73, 82, 106</sup>, while *Gorilla* has additional innervation from a branch of the deep palmar ramus of the ulnar nerve<sup>82</sup>.

#### *Flexor pollicis brevis*

In *Homo* flexor pollicis brevis usually has two heads, a radial or superficial head, and an ulnar or deep head<sup>106</sup>.

The *radial head* in all apes and *Homo* originates from the flexor retinaculum<sup>73, 106, 107, 82, 88</sup> in *Homo* and great apes from the trapezium<sup>10, 73, 82, 88, 93, 103, 106</sup>, while Asian apes share an additional origin from the proximal end of MI<sup>10</sup>.

The radial head may be fused with opponens pollicis in *Gorilla*<sup>82</sup>, which occurs as a variation in *Homo*<sup>106</sup>.

When present, in great apes and *Homo* the *ulnar head* originates from the trapezoid<sup>10, 73, 93</sup>, from the capitate in *Homo* alone<sup>106</sup>, while in *Homo* and *Hylobates* it originates from ligaments in the vicinity of these bones<sup>35, 106</sup>. It additionally takes origin from the distal end of MI in all apes<sup>10, 35, 82, 88, 93, 103</sup>, extending to MII in *Pan paniscus* and *Hylobates*<sup>35, 73</sup>. African apes and *Hylobates* also share an origin from the flexor retinaculum<sup>88</sup>.

The ulnar head is absent from 3/12 *Pan*<sup>19, 23, 35</sup>, 1★/6 *Gorilla*<sup>19, 35</sup> and 1/5 *Hylobates*<sup>19</sup> and may be absent from *Homo* as a rare variation<sup>18</sup>.

As a consequence of the increase in size in adductor pollicis obliquus, the true ulnar head of the flexor pollicis brevis has become reduced in size and pressed into a deeper position in great apes<sup>6, 35</sup>. An ulnar head is found in all primates in which the thumb is truly opposable, with the exception of those in which the thumb is reduced, such as African apes, or modified such as *Hylobates*<sup>19</sup>. However an ulnar head is present in *Pongo*, even though the thumb in *Pongo* is more reduced than in African apes. Day and Napier suggest that as structural brachiators there is little need for special musculature for opposition in African apes<sup>19</sup>.

Insertion in all apes and *Homo* with the exception of *Pan* is to the radial sesamoid bone of the metacarpophalangeal joint of the thumb<sup>9, 82, 103, 106</sup>, and to the capsule of this joint in *Gorilla*, extending to MI itself<sup>82</sup>. Great apes share an insertion to the proximal phalanx of the thumb<sup>10, 73, 82, 88, 93, 103</sup>, extending to the distal phalanx in all apes<sup>9, 38, 52, 82, 103, 104</sup>. The ulnar head in *Gorilla* inserts onto the bases of MII and MIII, and the palmar ligaments<sup>82</sup>.

A dual innervation from the median and ulnar nerves is present in *Homo*, *Pan paniscus* and *Pongo*<sup>10, 35, 73, 106</sup>, the other apes obtaining innervation solely from the median nerve<sup>10, 11, 35, 82</sup>.

#### *Opponens pollicis*

In great apes opponens pollicis takes origin from the radial sesamoid bone<sup>10, 82</sup>, and in *Homo* and African apes from the tubercle of the trapezium<sup>10, 82, 88, 106</sup>. In addition *Homo* and *Pan* share an origin from the flexor retinaculum<sup>10, 22, 23, 73, 88, 106</sup>.

The muscle is small or absent in *Pan*<sup>19, 26, 63</sup> and *Pongo*<sup>10, 15</sup>, but described as strong in *Hylobates*<sup>10</sup>.

In all apes and *Homo* the muscle inserts onto the radial margin of MI<sup>10, 35, 73, 82, 88, 93, 106</sup>, extending ventrally in *Gorilla*<sup>82</sup>, and sending slips forward to the radial sides of the bases of the proximal and middle phalanges in *Hylobates*<sup>35</sup>.

#### **3.4.1.4.3 Digital**

##### *Accessory interosseous*

An accessory interosseous muscle is present in *Hylobates* and *Symphalangus*, originating from the first dorsal interosseous or from flexor pollicis brevis<sup>29, 30, 48, 95</sup>.

The accessory interosseous inserts onto the base and ventrolateral shaft of the second phalanx of digit II<sup>29, 40</sup>, sometimes with a small fleshy extension to the pulp of the digit<sup>29, 41</sup>. It may insert into the extensor expansion at or just distal to the proximal interphalangeal joint<sup>29, 95</sup>, and appears to have a more extensive insertion in *Hylobates* than in *Symphalangus*, reaching to the distal phalanx in *Hylobates*<sup>10, 48</sup>, but only to the distal end of the middle phalanx in *Symphalangus*<sup>48</sup>.

### *Dorsal interossei*

Four dorsal interossei are present in all apes and *Homo*<sup>11, 23, 35, 73, 82, 89, 93, 106</sup>.

The *first dorsal interosseous* has an origin from ulnar MI and radial MII in all apes and *Homo*<sup>10, 73, 82, 93, 106</sup>, with the exception of a single specimen of *Pan* in which the origin is entirely from MII<sup>11</sup>. The origin from MI is reduced in *Hylobates*<sup>10</sup>. The muscle extends dorsoproximally on MI in *Gorilla*<sup>82</sup>. In addition, in *Gorilla* the muscle takes origin from the triquetrum<sup>82</sup>, and in *Hylobates* from the trapezium<sup>10</sup>.

The *second dorsal interosseous* takes origin in great apes and *Homo* from ulnar MII and radial MIII<sup>73, 82, 93, 106</sup>, extending ventrally on MIII in *Gorilla*<sup>82</sup>, and dorsally on MII in *Pongo*<sup>93</sup>.

The *third dorsal interosseous* originates in great apes and *Homo* from ulnar MIII and radial MIV<sup>73, 82, 93, 106</sup>, extending dorsally on MIV in *Gorilla* and *Pongo*<sup>82, 93</sup>.

The *4th dorsal interosseous* originates in great apes and *Homo* from ulnar MIV and radial MV<sup>73, 82, 93, 106</sup>, extending dorsally on MV in *Gorilla* and *Pongo*<sup>82, 93</sup>.

The insertion of the dorsal interossei is to the proximal phalanges and dorsal aponeurosis of the digits in all apes and *Homo*<sup>10, 23, 29, 59, 73, 82, 93, 103, 106</sup>. The first dorsal interosseous inserts onto the radial margin of digit II, the second dorsal interosseous onto the radial side of digit III, the third dorsal interosseous onto the ulnar side of digit III and the fourth dorsal interosseous onto the ulnar side of digit IV in great apes and *Homo*<sup>59, 82, 93, 106</sup>. The fourth interosseous in *Pan* may also extend to the radial side of digit V<sup>59</sup>.

Innervated by the deep ramus of the ulnar nerve in *Homo*, *Pan paniscus* and *Gorilla*<sup>73, 82, 106</sup>.

### *Lumbricals*

Four lumbricals are present in all apes and *Homo*<sup>3, 23, 35, 73, 89, 93, 106</sup>. No further information for *Hylobates*. The origins of all the lumbricals are from the tendons of flexor digitorum profundus<sup>3, 11, 73, 88, 89, 94, 103, 106</sup>.

The *first lumbrical* originates in *Homo*, *Pan*, *Pongo* and *Hylobates* from the radial side of the tendon to digit II<sup>23, 35, 73, 89, 93, 106</sup> and also from the tendon of flexor pollicis longus in *Gorilla*<sup>82</sup>.

It runs under the palmar aponeurosis to insert onto the dorsal aponeurosis of digit II in great apes and *Homo*<sup>3, 73, 93, 106</sup>, including the dorsal surface of the proximal phalanx in *Gorilla* and *Pongo*<sup>3, 82</sup>.

The *second lumbrical* originates in *Homo*, *Pan*, *Pongo* and *Hylobates* from the radial side of the tendon to digit III<sup>3, 23, 35, 73, 89, 93, 106</sup>. This lumbrical in great apes, but not *Homo* or *Hylobates*, occasionally has a double origin<sup>11, 23, 73, 93</sup>, the other component in *Pan* and *Pongo* coming from the ulnar side of the tendon to digit II<sup>11, 23, 73, 93</sup>.

The first and second lumbricals in *Pan* are connected by a slip<sup>88</sup>, absent from *Pongo*<sup>89</sup>.

Insertion in great apes and *Homo* is to the dorsal aponeurosis of digit III<sup>3, 73, 93, 106</sup>, including the dorsal surface of the proximal phalanx in *Gorilla* and *Pongo*<sup>3, 82</sup>.

The *third lumbrical* originates in *Homo*, *Pan* and *Pongo* from the radial side of the tendon to digit IV<sup>3, 23, 73, 89, 93, 106</sup>. In all apes, including *Gorilla* and *Hylobates*, this muscle has a double origin<sup>3, 23, 35, 89, 93</sup>, unlike *Homo*<sup>106</sup>. The second part of the origin in *Pan* and *Pongo* comes from the ulnar side of the tendon to digit III<sup>3, 23, 73, 89,</sup>



The insertion in great apes and *Homo* is to the dorsal aponeurosis of digit IV<sup>3, 93, 106</sup>, including the dorsal surface of the proximal phalanx in *Gorilla* and *Pongo*<sup>3, 82</sup>.

The *fourth lumbrical* originates in *Homo*, *Pan* and *Pongo* from the radial side of the tendon to digit V<sup>35, 73, 89, 93, 106</sup>. In *Pan* alone, the origin may alternatively come from the ulnar side of the tendon to digit IV alone<sup>23, 35, 108</sup>, or as a double origin from both sources<sup>3, 11</sup>.

This lumbrical is the smallest in all apes, and is frequently absent from hylobatids<sup>103</sup>.

Thus, the first lumbrical has a single origin in *Homo* and great apes<sup>3, 23, 35, 82, 93, 106</sup>, the second may have, and the third lumbrical always has, a double origin in great apes<sup>3, 11, 23, 35, 82, 89, 93</sup>, and the fourth lumbrical may have a double origin in *Pan*<sup>3, 11</sup>.

The insertion of all these muscles in *Homo* is to the joint capsules of the metacarpophalangeal joints<sup>106</sup>, while in *Gorilla* they are described as extending to the ligaments of the proximal and intermediate phalanges of the digits<sup>82</sup>.

The first and second lumbricals are innervated by the median nerve and the third and fourth by the deep branch of the ulnar nerve in *Homo*, *Pan paniscus* and *Gorilla*<sup>73, 82</sup>,

106

#### *Palmar interossei*

Three palmar interossei are present in all apes and *Homo*<sup>22, 35, 82, 89, 93, 106</sup>. No further information available for *Hylobates*. Six or seven palmar interossei have been described for both species of *Pan*<sup>11, 23, 30, 35, 59, 73, 88</sup>, the extra muscles being palmar deviated portions of the second, third and fourth dorsal interossei<sup>11, 35, 59, 73, 88</sup>.

The *first palmar interosseous* in great apes and *Homo* originates from the ulnar side of MII, inserting onto the proximal phalanx and dorsal aponeurosis on the ulnar side of digit II<sup>11, 22, 23, 35, 73, 82, 93, 106</sup>.

The *second palmar interosseous* in great apes and *Homo* originates from the radial side of MIV, inserting onto the proximal phalanx and dorsal aponeurosis of digit IV<sup>11, 22, 23, 35, 73, 82, 93, 106</sup>.

The *third palmar interosseous* in great apes and *Homo* originates from the radial side of MV, inserting onto the proximal phalanx and dorsal aponeurosis of digit V<sup>11, 22, 23, 35, 73, 82, 93, 106</sup>.

In addition, all the interossei take origin from the intermuscular septa in great apes<sup>11, 82, 93</sup>. The muscles in *Gorilla* insert onto the capsules of the metacarpophalangeal joints<sup>82</sup>.

Innervated by twigs from the deep ramus of the ulnar nerve in *Homo*, *Pan paniscus* and *Gorilla*<sup>73, 82, 106</sup>.

### 3.4.2 VESSELS

#### 3.4.2.1 Arteries

##### 3.4.2.1.1 Axillary<sup>b</sup>

###### *Axillary*

The axillary artery enters the axilla below the brachial plexus in all apes<sup>32, 67</sup>, while in *Homo* the lateral and posterior cords of the brachial plexus run on the lateral side

of the artery<sup>106</sup>. The artery runs in front of the medial cord of the brachial plexus in *Homo*, *Gorilla* and *Pongo*<sup>67, 106</sup>.

The axillary artery lies in front of the radial nerve and behind the median nerve in *Homo* and *Pongo*<sup>67, 106</sup>, and is crossed by the ulnar nerve in *Homo* and *Pan*<sup>67, 106</sup>. In *Pan* the axillary artery lies in front of the median nerve<sup>74, 75</sup>.

The medial cutaneous nerve of the arm lies medial to the axillary artery in *Homo*<sup>106</sup>, while it is crossed by the medial cutaneous nerve of the arm in *Pan* and *Hylobates*<sup>67</sup>.

#### *Anterior and posterior circumflex humeral*

The anterior and posterior circumflex humeral arteries are independent branches from the axillary artery in *Homo*<sup>106</sup>, but arise in all apes from a common circumflex trunk<sup>23, 32, 67, 74, 75</sup>. The posterior circumflex may arise independently from the profunda brachii as a variant in *Homo*<sup>106</sup>.

The common circumflex trunk in *Pan* and Asian apes may also include the profunda brachii<sup>67, 74, 75</sup>, in African apes and *Hylobates* the circumflex scapular<sup>67</sup>, and in *Pan* and *Hylobates* also the subscapular artery<sup>67, 74, 75</sup>.

The posterior circumflex humeral is larger than the anterior circumflex humeral in *Homo* and African apes<sup>32, 67, 106</sup>.

#### **3.4.2.1.2 Brachial<sup>b</sup>**

##### *Brachial*

The brachial artery in *Homo* lies deep to the median nerve<sup>106</sup>, while in all apes the brachial artery passes superficial to this nerve, and is thus a superficial brachial artery<sup>32, 67, 74, 75, 88</sup>.

Its terminal branches, the radial and ulnar arteries, are present in all apes and *Homo*<sup>12, 23, 32, 67, 89</sup>.

Apart from those branches described below, the brachial artery also gives off a nutrient artery to the humerus in *Homo* and *Gorilla*<sup>67, 106</sup>, muscular branches to the biceps and brachialis in *Homo* and all apes<sup>32, 67, 88</sup> and also to the coracobrachialis in *Homo* and African apes<sup>32, 67, 106</sup>, but not in *Pongo*<sup>89</sup>. Muscular branches to teres major, latissimus dorsi and dorsoepitrochlearis are present in *Pongo*<sup>89</sup>, and to triceps in *Pan* and Asian apes<sup>67, 88, 89</sup>.

#### *Profunda brachii*

Originates in *Homo*, 2/3 *Pan*, and sometimes in *Hylobates*, from the brachial artery<sup>23, 32, 67, 74, 75, 88, 106</sup>, but usually in all apes from the axillary artery<sup>67, 74, 75</sup>.

#### *Superior ulnar collateral*

Originates in *Homo* and African apes from the brachial artery<sup>32, 67, 106</sup>, but in Asian apes and as a variant in *Homo*, from the profunda brachii<sup>67, 106</sup>.

#### *Inferior ulnar collateral*

Originates from the brachial artery above the elbow joint in all apes and *Homo*<sup>32, 67, 74, 75, 106</sup>.

The inferior ulnar collateral artery winds round the posterior surface of the humerus in all apes and *Homo*<sup>67, 106</sup>.

The artery anastomoses with the superior ulnar collateral artery and the anterior ulnar recurrent artery in *Homo* and *Pongo*<sup>67, 106</sup>. In *Homo*, this artery also anastomoses

with the middle collateral branch of the profunda brachii and the posterior ulnar recurrent artery<sup>106</sup>.

### 3.4.2.1.3 Radial<sup>b</sup>

#### *Radial*

The radial artery enters the palm at the dorsum of the first interosseous space in *Homo* and African apes<sup>11, 32, 68, 88, 89, 106</sup>, whilst in Asian apes it enters the palm at the dorsum of the second interosseous space<sup>68, 89</sup>.

The branch of the radial artery called "*dorsalis pollicis*" is present in *Gorilla* and Asian apes<sup>68</sup>, but not in *Homo* or *Pan*<sup>68, 106</sup>.

#### *Radial recurrent*

Originates from the radial artery in *Homo*<sup>106</sup>, 1/3 *Pan*<sup>74, 75</sup>, *Gorilla*<sup>68</sup> and *Hylobates*<sup>68</sup> but from the end of the brachial artery in 2/3 *Pan*<sup>67, 68, 88</sup> and in *Pongo*<sup>67, 68, 74, 75, 88, 106</sup>.

#### *Palmar carpal*

No information for *Pan*.

Originates from the radial artery in *Homo* and Asian apes<sup>68, 106</sup>, but from the radial recurrent artery in *Gorilla*<sup>68</sup>.

#### *Superficial palmar*

In all apes and *Homo* except *Gorilla* this artery originates from the radial artery<sup>67, 68, 74, 75, 88, 89</sup>. In *Gorilla* it originates either from the brachial artery or the radial recurrent artery<sup>67, 68</sup>. It may be absent from *Hylobates*<sup>68</sup>.

In all apes and *Homo* the artery pierces the thenar muscles<sup>32, 68, 106</sup>, although as a variant in *Homo* and *Pan* it may pass over these muscles<sup>88, 106</sup>. In *Gorilla* and

*Hylobates* the artery ends in the thenar muscles<sup>68, 74, 75</sup>, while in *Homo*, *Pan* and *Pongo* the artery continues to complete the superficial palmar arch<sup>32, 68, 88, 89, 106</sup>.

### *Dorsal carpal*

No information for *Pan* or *Hylobates*.

The dorsal carpal artery is present in *Homo*, *Gorilla* and *Pongo*<sup>68, 106</sup>.

In *Homo* and *Gorilla* it anastomoses with the dorsal carpal branch of the ulnar artery<sup>68, 106</sup>.

### *Princeps pollicis*

*Princeps pollicis* is a branch of the radial artery in *Homo*, African apes and *Hylobates*<sup>68, 106</sup>. In *Pongo* the *princeps pollicis* is a branch of the superficial palmar arch<sup>68, 89</sup>.

In 1/2 *Hylobates* the *princeps pollicis* is the completing artery for the superficial palmar arch<sup>74, 75</sup>. This occurs as a rare variation in *Homo*<sup>16</sup>.

### *Radialis indicis*

Originates in *Homo* from the radial artery, or the *princeps pollicis*, or with the *princeps pollicis* from the first palmar metacarpal artery<sup>106</sup>. In African apes it springs from the first palmar metacarpal artery<sup>68</sup> and in Asian apes from the deep palmar arch<sup>68, 89, 106</sup>.

### 3.4.2.1.4 Ulnar<sup>b</sup>

#### *Ulnar artery*

Branches of the ulnar artery in the hand include a dorsalis pollicis branch in *Gorilla* and Asian apes<sup>68</sup> and in addition dorsalis indicis and dorsal metacarpal branches in *Gorilla* and *Pongo*<sup>68</sup>.

The digital supply of the ulnar artery involves digits IV and V in all apes and *Homo*<sup>68, 88, 106</sup>, extending to digit III in all except *Gorilla*<sup>68</sup>.

Branches of the ulnar artery contribute to both the superficial, and the deep palmar arches in all apes and *Homo*<sup>32, 68, 88, 89, 106</sup>.

#### *Anterior and posterior ulnar recurrent*

Originate from the brachial artery in all apes<sup>67, 68</sup> but from the ulnar artery in *Homo*<sup>106</sup>. As a variant in *Homo*, 1/2 *Pan* and in Asian apes, the anterior and posterior arteries originate from a common trunk, rather than as independent branches<sup>32, 67, 68, 74, 75, 89, 106</sup>.

#### *Common interosseous*

A common interosseous is present in *Homo* and *Pan*<sup>32, 67, 68, 106</sup>, being absent from all other apes<sup>67, 68, 74, 75</sup>.

In both *Homo* and *Pan* the artery may arise either from the ulnar<sup>32, 106</sup>, or from the brachial artery<sup>67, 68, 106</sup>.

### *Anterior interosseous*

The anterior interosseous artery is a branch of the brachial artery in all apes<sup>68, 74, 75, 88</sup>, with the exception of 2/3 *Pan*<sup>32, 67, 68</sup>, in which it arises from the common interosseous artery as in *Homo*<sup>106</sup>.

In *Hylobates* the anterior interosseous artery joins a large artery connecting the ulna and radial arteries near the wrist<sup>68</sup>.

### *Posterior interosseous*

The posterior interosseous artery is a branch of the common interosseous artery in *Homo* and *Pan*<sup>32, 68, 106</sup>, but of the brachial artery in *Gorilla* and Asian apes<sup>68, 74, 75</sup>.

### *Dorsal carpal*

A dorsal carpal branch of the ulnar artery is present in all apes and *Homo*<sup>68, 88, 89, 106</sup> with the exception of *Hylobates*<sup>68</sup>.

### *Palmar carpal*

No information for *Gorilla*.

A palmar carpal branch of the ulnar artery is present in *Homo*, *Pan* and Asian apes<sup>68, 89, 106</sup>.

### *Deep palmar*

A deep palmar branch of the ulnar artery is present in all apes and *Homo*<sup>68, 74, 75, 89, 106</sup>.

## **3.4.2.1.5 Anastomoses**



### *Deep palmar arch*

The deep palmar arch is formed mainly by the deep palmar ramus of the ulnar artery and completed by the radial artery in all apes and *Homo*<sup>32, 68, 88, 89, 106</sup>.

This radial completing branch may be the princeps pollicis in African apes<sup>68, 88</sup>, or the radialis indicis in 1/2 *Pongo*<sup>89</sup>. The radial contribution in *Hylobates* is slight, the main vessel being the deep palmar ramus of the ulnar artery<sup>68</sup>. Ikeda *et al.* give the radial contribution to the deep palmar arch in *Homo* and great apes as the first dorsal metacarpal artery<sup>42,43</sup>.

In *Gorilla* the deep palmar ramus divides into two branches, both of which anastomose with the radial artery<sup>68</sup>.

The deep palmar arch is very fine in *Pongo*<sup>68</sup>.

### *Palmar metacarpal*

The palmar metacarpal arteries in *Homo*, *Hylobates* and *Gorilla* originate from the deep palmar arch<sup>68</sup>, and in *Pan* directly from the radial artery<sup>68</sup>.

The arteries appear to be absent from *Pongo*<sup>68</sup>.

The hand of *Pongo* is peculiar in having most of the digits and digit I supplied by branches of the superficial palmar arch, whilst in other apes these common palmar digital arteries are reinforced by the palmar metacarpal arteries from the deep palmar arch<sup>68</sup>.

The palmar metacarpal arteries reach the second, third and fourth spaces in *Homo*, 1/2 *Pan* and *Gorilla*<sup>32, 68, 106</sup>, or the third and fourth spaces and medial side of digit V in 1/2 *Pan*<sup>32</sup>. The palmar metacarpals run in the second and third spaces in *Hylobates*<sup>68</sup>.

### *Superficial palmar arch*

The superficial palmar arch is formed mainly by the ulnar artery, completed by the superficial palmar ramus of the radial artery in all apes and *Homo*<sup>16, 32, 68, 74, 75, 88, 89</sup> with the exception of 1/2 *Hylobates* in which the completing artery is the princeps pollicis branch of the radial artery<sup>74, 75</sup>. This may occur as a rare variation in *Homo*<sup>16</sup>.

### *Common palmar digital*

The digital branches of the superficial palmar arch supply the adjacent sides of II to V in *Homo* and 1/2 *Pan*<sup>32, 106</sup>, of digits III to V in 1/2 *Pan*<sup>68</sup>, and of digits I to V in *Pongo*<sup>68, 89</sup>.

In *Gorilla*<sup>21, 68, 89</sup> and 1/2 *Hylobates*<sup>68</sup> where the superficial palmar arch is not defined, the ulnar artery supplies the medial side of the hand, and the adjacent sides of digits IV and V in *Gorilla*<sup>68</sup>, and of digits I to V in *Hylobates*<sup>68</sup>.

The digital arteries are reinforced by palmar metacarpal arteries from the deep palmar arch in all taxa except *Pongo*<sup>68, 106</sup>.

## **3.4.2.2 Veins<sup>b</sup>**

### **3.4.2.2.1 Superficial**

#### *Veins of the hand*

Veins from the radial side of the hand in *Gorilla* and *Pongo* do not directly join the cephalic vein<sup>82, 89</sup>. In *Gorilla*, these veins pass to the anteromedial side of the wrist, but no further information was given<sup>82</sup>. In *Pongo* these veins form a vessel which joins the cephalic vein in the upper forearm<sup>89</sup>, which is a frequent variation in *Homo*<sup>106</sup>.

### Cephalic

The cephalic vein, or lateral superficial vein<sup>100,101</sup>, is present in all apes and *Homo*<sup>12, 82, 88, 89</sup>.

In the majority of *Homo*, 1/6 *Pan* and in Asian apes the vein is “long”, extending from the radial side of the dorsal venous network to terminate in the infraclavicular region by piercing the clavipectoral fascia to enter the axillary vein<sup>80, 100, 101</sup>.

In 20-25% of *Homo*, 5/6 *Pan* and in *Gorilla*, the cephalic vein is “short”, being found only in the forearm<sup>80, 82, 88, 81, 86, 100, 101</sup>. In these African apes the vein extends from the radial side of the dorsal venous network to terminate by piercing the fascia in the cubital fossa to unite with the brachial vein<sup>82, 88, 100, 101</sup>.

The polymorphism in *Homo* can be interpreted as an intermediate condition between the “long” and “short” states, supported by the fact that in *Homo* the “short” lateral vein is usually accompanied by segments or networks representing the brachial portion of the vein<sup>101</sup>.

	N	Vein length (cm)	No. valves	Mean valve index	SD of index
<i>Homo</i>	29	48	8.8	0.18	0.04
<i>Pan</i>	4	23	4.7	0.22	0.08
<i>Gorilla</i>	1	20	2.0	0.10	-
<i>Hylobates</i>	5	40	6.2	0.15	0.02

Table 3.4.3. Valve indices for the cephalic veins in *Homo*, *Pan*, *Gorilla* and *Hylobates*. Mean valve index = Number of valves/vein length. Adapted from<sup>99</sup>.

### Basilic

The basilic vein, or medial superficial vein<sup>100,101</sup>, is present in *Homo*<sup>106</sup>, and absent from all apes<sup>12, 82, 88, 89, 100, 101, 106</sup> although variably so in *Gorilla*<sup>12</sup> and *Pongo*<sup>101</sup>.

### 3.4.2.2 Deep

#### *Brachial*

The brachial veins are present on each side of the brachial artery in *Homo*<sup>106</sup>. A single vein accompanies that part of the brachial artery which runs superficial to the median nerve in all apes and in 27% of *Homo*<sup>88, 100</sup>. This vein should be termed the “superficial brachial vein”<sup>100</sup>. In addition to the “superficial brachial vein”, *Gorilla* also possessed the deep continuation of the cephalic vein in the arm<sup>100</sup>. Raven found the brachial veins in *Gorilla* to be as in *Homo*<sup>82</sup>.

Tributaries of the deep veins of the arm included the veins accompanying the main arteries of the arm in all apes and *Homo*<sup>100</sup>.

A large perforating vein opened into the superficial brachial vein in *Hylobates*<sup>100</sup>.

#### *Ulnar*

Ulnar venae comitantes are present in the forearm in all apes and *Homo*<sup>12, 100, 106</sup>.

Tributaries of the ulnar venae comitantes included the veins accompanying the interosseous arteries, numerous muscular veins and also perforating veins in all apes and *Homo*<sup>100</sup>.

#### *Radial*

Radial venae comitantes are present in the forearm in all apes and *Homo*<sup>12, 100, 106</sup>.

Tributaries of the radial venae comitantes included numerous muscular veins and also perforating veins in all apes and *Homo*<sup>100</sup>.

### 3.4.2.2.3 Communicating

#### *Hand*

The medial side of the superficial dorsal venous network communicates with the deep ulnar venae comitantes at the wrist adjacent to the ulnar head in 16% of *Homo* and in great apes, but not in *Hylobates*<sup>100</sup>.

In *Homo* and 1/5 *Pan* forelimbs there were also perforators connecting the superficial dorsal veins on the radial side and the deep metacarpal vein in the first or second interosseous space<sup>100</sup>.

#### *Forearm*

The distal part of the radial forearm in *Homo* displayed numerous perforating veins<sup>100</sup>. In apes, this region showed one perforating vein in *Hylobates*, and one or two such veins in great apes, connecting the cephalic vein and the radial venae comitantes<sup>100</sup>.

A perforator connected the posterior forearm superficial veins and the deep muscular veins in *Pan*, *Pongo* and 4/6 *Hylobates* limbs, but not in *Gorilla*<sup>100</sup>.

In 1/5 *Pan* and 1/6 *Hylobates* forelimbs there was a perforator in the mid-forearm region which connected the cephalic vein and the deep veins<sup>100</sup>.

In *Homo*, 3/5 *Pan*, *Gorilla* and *Hylobates* there are one or two perforating veins in the cubital fossa<sup>89, 100, 106</sup>, while these veins are absent from the cubital fossa in 2/5 *Pan*<sup>100</sup> and in *Pongo*<sup>89, 100</sup>.

## *Arm*

In *Hylobates* a large perforator connected the cephalic vein to the superficial brachial vein, and in addition a perforator pierced the triceps muscle, connecting the cephalic vein to the deep veins within the muscle<sup>100</sup>.

Apart from those described in the above paragraphs, in *Homo* numerous perforating veins, variable in position and incidence, can be found along the length of the forelimb<sup>100, 106</sup>.

### **3.4.2.3 Lymphatics**

#### *Axillary lymph nodes*

No information for *Gorilla* or *Hylobates*.

Lateral and posterior axillary nodes are present in *Homo*, *Pan* and *Pongo*<sup>89, 106</sup>, while anterior axillary nodes, present in *Homo*<sup>106</sup>, are absent from *Pan* and *Pongo*<sup>89</sup>.

In *Homo*, central and apical axillary nodes are also present<sup>106</sup>.

#### *Infraclavicular lymph nodes*

No information for *Gorilla* or *Hylobates*.

These nodes are present in *Homo*, *Pan* and *Pongo*<sup>89, 106</sup>.

#### *Supratrochlear lymph nodes*

No information for *Gorilla* or *Hylobates*.

Present in *Homo*<sup>106</sup>, absent from *Pan* and *Pongo*<sup>89</sup>.

### 3.4.3 NERVES

#### 3.4.3.1 Brachial plexus

The brachial plexus consists of the ventral rami of the lower four cervical nerves and the first thoracic nerve in all apes and *Homo*<sup>32, 35, 50, 72, 84, 89, 106</sup>.

The fourth cervical nerve usually gives a branch to the fifth cervical in *Homo* and also in 2/5 *Pan*<sup>50, 72</sup>, *Gorilla*<sup>35, 72, 50</sup> and Asian apes<sup>35, 72, 89</sup>, while the second thoracic nerve frequently gives a branch to the first thoracic nerve in *Homo* and *Pongo*<sup>5, 17, 72, 85, 89, 106</sup>, always absent from African apes and *Hylobates*<sup>32, 35, 50, 72, 84, 102</sup>. However both are subject to variation in *Homo*<sup>106</sup>.

The most constant arrangement of the roots in *Homo* is as follows:

The fifth and sixth cervical nerves unite to form the upper trunk of the plexus. The eighth cervical and first thoracic nerves unite to form the lower trunk, while the seventh cervical nerve itself forms the middle trunk.

Each trunk splits into anterior and posterior divisions. The anterior divisions of the upper and middle trunks unite to form the lateral cord, the anterior division of the lower trunk forms the medial cord, and the posterior divisions of all three trunks unite to form the posterior cord<sup>106</sup>.

In *Pan*, two varieties have been found. In the first, the trunks are formed as in *Homo*<sup>72</sup>, while in the second, no true upper trunk is formed, as the fifth cervical nerve unites only with the anterior division of the sixth cervical nerve<sup>32, 88</sup>. In both of these cases, the posterior divisions of all the nerves form a posterior cord as in *Homo*<sup>32, 88</sup>, but the anterior divisions of all the trunks form a single large cord, which

Glidden and De Garis have called the "superolateral" cord<sup>32, 88</sup>. In these cases the musculocutaneous nerve may represent the lateral cord<sup>88</sup>.

In *Gorilla*, three varieties have been found. The first is identical to that found in *Homo*<sup>24 35</sup>. In the second, the trunks and cords are formed as in *Homo*, but the lateral and middle trunks continue to form a common cord, similar to the "superolateral" cord of *Pan*, which then bifurcates into two branches, a musculocutaneous-median trunk, and the ulnar nerve<sup>50</sup>. The third variety displays only two trunks, one from the fourth to sixth cervical nerves, and the second from the seventh to eight cervical nerves plus the first thoracic nerve. The middle trunk is thus absent. The lateral and middle cords are formed from the anterior divisions of these two trunks, and the posterior cord is formed as in *Homo*<sup>72</sup>.

Two varieties of brachial plexus have been described in *Pongo*. The first type is identical to that found in *Homo*<sup>35, 72</sup>. In the second type, there is no true upper trunk, as only the anterior divisions of the fifth and sixth cervical nerves unite. The middle and lower trunks and the cords are formed as in *Homo*<sup>89</sup>.

In *Hylobates*, the plexus has been found to be identical to that of *Homo*<sup>35, 50</sup>.

### 3.4.3.2 Spinal nerves

#### *Intercostobrachial*

The intercostobrachial nerve originates from the second thoracic nerve in *Homo*<sup>106</sup>, from the first and third thoracic, or only the second thoracic in *Part*<sup>72</sup>, from the first and second thoracic nerves in *Gorilla* and *Hylobates*<sup>72, 82</sup> and from the first and third thoracic nerves in *Pongo*<sup>72</sup>.



The intercostobrachial nerve communicates with the medial cutaneous nerve of the arm in *Homo* and 1/3 *Pan*<sup>89, 106</sup>, but not in 2/3 *Pan*<sup>89</sup> or *Pongo*<sup>89</sup>.

### 3.4.3.3 Branches of the brachial plexus<sup>b</sup>

#### 3.4.3.3.1 Supraclavicular

##### *Dorsal scapular*

No information for *Pan*, *Pongo* or *Hylobates*.

The dorsal scapular nerve arises from the fifth cervical nerve in *Homo* and *Gorilla*<sup>82, 106</sup>, with an additional branch from the fourth cervical nerve in *Gorilla*<sup>82</sup>.

##### *Long thoracic*

The long thoracic nerve consists of spinal components of the fifth to seventh cervical nerves in all apes and *Homo*<sup>32, 35, 72, 82, 88, 89, 106</sup>. The root from the seventh cervical nerve may be absent from *Homo*<sup>106</sup>, and is absent from *Gorilla* and 1/3 *Pongo*<sup>35, 82</sup>.

The origin may also include the fourth cervical nerve in *Pan* and *Pongo*<sup>35, 89</sup>.

The nerve innervates serratus anterior in *Homo*, *Gorilla* and *Pongo*<sup>35, 82, 88, 89, 106</sup>.

##### *Suprascapular*

The suprascapular nerve has its spinal origin from the fourth cervical nerve in *Gorilla*<sup>24, 35, 72, 82</sup>, from the fifth cervical in all apes and *Homo*<sup>11, 24, 32, 35, 48, 72, 82, 88, 89</sup>, and from the sixth cervical nerve in *Homo*<sup>72, 106</sup>, 2/6 *Pan*<sup>35, 72</sup>, 1/4 *Gorilla*<sup>72</sup>, 2/5 *Pongo*<sup>35, 72</sup> and 1/3 *Hylobates*<sup>72</sup>.

#### 3.4.3.3.2 Infraclavicular

#### 3.4.3.3.2.1 Pectoral

The lateral and medial pectoral nerves are derived from all the roots of the brachial plexus in all apes and *Homo*<sup>11, 32, 35, 72, 82, 106</sup>.

#### 3.4.3.3.2.2 Musculocutaneous

The musculocutaneous nerve originates in all except *Hylobates* from the lateral cord of the brachial plexus<sup>32, 72</sup>; from the fifth to seventh cervical nerves in *Homo*, *Pan*, 1/3 *Gorilla* and *Hylobates*<sup>13, 50, 82, 88, 106</sup>. In *Gorilla*, the origin may be from the fifth cervical or fourth and fifth cervical<sup>50</sup>.

The musculocutaneous nerve pierces coracobrachialis in *Homo* and great apes<sup>11, 12, 35, 50, 88, 89</sup>, but not in 1/3 *Gorilla*<sup>50</sup> or in *Hylobates*<sup>35, 50</sup>.

The muscular branches of the nerve supply coracobrachialis, biceps brachii and brachialis in all apes and *Homo*<sup>35, 50, 73, 82, 88, 89, 106</sup>. It did not supply coracobrachialis in 1/3 *Gorilla*<sup>50</sup> or 1/2 *Hylobates*<sup>50</sup>.

The musculocutaneous nerve produces the *lateral cutaneous nerve of the forearm* in all apes and *Homo*<sup>35, 82, 89</sup>.

#### 3.4.3.3.2.3 Medial cutaneous nerves

The medial cord of the brachial plexus supplied medial cutaneous nerves to the arm and forearm in all apes and *Homo*<sup>13, 32, 35, 106</sup>.

The *medial cutaneous nerve of the arm* was derived from the eighth cervical and first thoracic nerves in *Homo* and *Pan*<sup>13, 106</sup>, and from the second and third thoracic nerves in *Gorilla*<sup>82</sup>.

#### 3.4.3.3.2.4 Median

The spinal nerve components of the median nerve are the fifth to eighth cervical nerves, and the first thoracic nerve in all apes and *Homo*<sup>50, 72, 82, 106</sup>, extending to the second thoracic nerve in *Pongo*<sup>72</sup>. The fifth cervical nerve is a variable component in *Homo*<sup>106</sup>.

Muscular branches of the median nerve innervate abductor pollicis brevis, flexor digitorum profundus, flexor pollicis brevis and opponens pollicis in all apes and *Homo*<sup>11, 35, 73, 82, 89, 106</sup>, flexor carpi radialis, flexor digitorum superficialis, and pronator teres in all except *Hylobates*<sup>11, 13, 14, 23, 35, 82, 88, 89, 93, 106</sup> and palmaris longus in *Homo* and great apes<sup>82, 89, 115</sup>. Branches innervate coracobrachialis in *Pan*<sup>88</sup>, and brachialis and flexor indicis in *Gorilla*<sup>35, 82</sup>. The median nerve supplies two or three lateral lumbricals in *Homo*<sup>106</sup>, one or two lumbricals in *Pan* and *Pongo*<sup>88, 89</sup> and two lumbricals in *Gorilla* and *Hylobates*<sup>35, 82</sup>.

The digital branches innervate the lateral three and a half digits in *Homo* and African apes<sup>35, 82, 89, 106</sup> and two and a half digits in Asian apes<sup>35, 89</sup>, although the distribution varies in *Homo*<sup>106</sup>, and may do so in other hominoids.

It musculocutaneous pierces the coracobrachialis in *Homo* and great apes<sup>11, 12, 35, 50, 88, 89</sup>, but not in 1/3 *Gorilla*<sup>50</sup> or in *Hylobates*<sup>35, 50</sup>.

#### *Anterior interosseous*

The median nerve gives off an anterior interosseous nerve in all apes and *Homo*<sup>11, 82, 89, 106</sup>.

It innervates flexor digitorum profundus in all apes and *Homo*<sup>11, 82, 89, 106</sup>, flexor pollicis longus in *Homo* and *Pan*<sup>11, 106</sup>, and pronator quadratus in *Gorilla* and *Pongo*<sup>82, 89</sup>, but not in *Hylobates*<sup>35, 89</sup>.

#### 3.4.3.3.2.5 Ulnar

The ulnar nerve in all apes and *Homo* courses between the two heads of flexor carpi ulnaris<sup>35, 82, 88, 89, 106</sup>, with the exception of 1/5 *Pongo* in which it runs along the deep surface of the muscle<sup>93</sup>.

In *Gorilla* it is embedded in the substance of dorsoepitrochlearis<sup>12</sup>.

Muscular branches of the ulnar nerve innervate flexor carpi ulnaris, flexor digitorum profundus, adductor pollicis and the interossei in all apes and *Homo*<sup>11, 35, 73, 82, 88, 89, 106</sup>, the hypothenar muscles in *Homo*, *Pan* and *Pongo*<sup>88, 89, 106</sup>, palmaris brevis in *Homo*<sup>106</sup> and part of the triceps in *Pan*<sup>11</sup>. Innervation from the ulnar nerve to flexor pollicis brevis is present in 48% of *Homo* and in *Pongo*<sup>35, 106</sup>. It innervates the two inner lumbricals in *Homo* and Asian apes<sup>35, 89, 106</sup>, the innermost lumbrical in *Pan*<sup>35</sup> and three inner lumbricals in *Gorilla*<sup>35</sup>.

Cutaneous branches run to the skin of the dorsal surface of the forearm and hand in all apes and *Homo*<sup>35, 82, 89, 106</sup>.

The digital supply is to the medial one and a half digits in all apes and *Homo*, but may extend to two and a half digits in all except *Pan*<sup>12, 25, 33, 35, 36, 48, 51, 88, 89, 91, 106</sup>.

### 3.4.3.3.2.6 Radial

The radial nerve originates in all apes and *Homo* from the fifth to eighth cervical nerves, and the first thoracic nerve<sup>32, 72, 82, 88, 106</sup>. In *Pongo* it also involves the second thoracic nerve<sup>72</sup>.

The radial nerve pierces the supinator muscle in all except *Homo*, in which the posterior interosseous branch of the radial nerve pierces supinator<sup>35, 82, 88, 89, 90, 106</sup>.

There is a gangliform enlargement at the junction with the posterior interosseous nerve in *Homo* and *Pan*<sup>11, 106</sup>.

Muscular branches of the radial nerve innervate triceps brachii, extensor carpi radialis longus and supinator in all apes and *Homo*<sup>35, 82, 88, 89, 106</sup>, dorsoepitrochlearis in all apes but not in *Homo*<sup>11, 35, 82, 88, 89</sup>, brachioradialis in *Homo* and great apes<sup>73, 82, 89, 106</sup>, brachialis in *Homo* and *Gorilla*<sup>35, 82, 106</sup>, and extensor carpi radialis brevis in *Gorilla*<sup>82</sup>.

Cutaneous branches supply the skin of the dorsum of the forearm and hand in all apes and *Homo*<sup>12, 35, 82, 88, 89, 106</sup>.

The digital supply is to the lateral two and a half digits in *Homo* and *Gorilla*<sup>35, 82, 106</sup> and to the lateral one and a half digits in *Pan* and Asian apes<sup>35, 89</sup>.

#### *Posterior interosseous*

In 1/7 *Pan*, rather than being embedded in the supinator muscle as in *Homo* and all other apes<sup>11, 13, 82, 88, 89, 90, 106</sup>, the posterior interosseous nerve is covered by fascia on the surface of the muscle<sup>35</sup>.

In *Homo*, this branch of the radial nerve supplies extensor carpi radialis brevis, supinator, extensor digitorum, extensor digiti minimi, extensor carpi ulnaris, extensor pollicis longus, extensor indicis, abductor pollicis longus and extensor pollicis brevis<sup>106</sup>. It is described as supplying the same muscles in great apes as in *Homo*<sup>35, 89</sup>. Unlike other apes and *Homo*, in *Hylobates* the posterior interosseous nerve supplied pronator quadratus<sup>35</sup>.

In *Homo*<sup>106</sup>, but not in apes<sup>35, 82, 88, 89, 90</sup>, the posterior interosseous branch of the radial nerve pierces supinator rather than the radial nerve. There is a gangliform enlargement at the junction of the radial and posterior interosseous nerves in *Homo* and *Pan*<sup>11, 106</sup>.

#### 3.4.3.3.2.7 Axillary

The axillary nerve in all apes and *Homo* originates from the fifth and sixth cervical nerves<sup>11, 82, 72, 82, 106</sup>. It also includes the seventh cervical nerve in apes and as a variation in *Homo*<sup>11, 32, 72, 82, 106</sup>, in all apes also the eighth cervical nerve<sup>32, 72, 82</sup>, and in African apes also includes the first thoracic nerve<sup>32, 72</sup>.

A pseudoganglion on the branch to teres minor is usually present in *Homo* and *Pan*<sup>11, 35, 106</sup>, which is absent from Asian apes<sup>35</sup>. No information for *Gorilla*.

Muscular branches of the nerve supply teres minor in all apes and *Homo*<sup>35, 82, 88</sup>, deltoid in all except *Pongo*<sup>82, 88</sup> and subscapularis in *Gorilla* and *Pongo*<sup>35, 89</sup>. It also supplies teres major in *Gorilla*<sup>35</sup>.

The axillary nerve forms the *lateral cutaneous nerve of the arm* in all taxa except *Pongo*<sup>82, 88, 106</sup>.

### 3.4.3.3.2.8 Subscapular

#### *Subscapular*

The subscapular nerves originate from the fifth and sixth cervical nerves in all apes and *Homo*<sup>32, 72, 82, 88, 106</sup>. They also include the seventh cervical nerve in all apes<sup>82, 72</sup>, the eighth cervical in African apes and *Hylobates*<sup>72, 88</sup>, and the first thoracic nerve in African apes<sup>82, 72, 88</sup>.

The subscapular nerves are given off from the axillary nerve in *Gorilla* and Asian apes<sup>35, 72, 89</sup>.

#### *Thoracodorsal*

No information for *Pan*, *Pongo* or *Hylobates*.

The thoracodorsal nerve arises from the sixth, seventh and eighth cervical nerves in *Homo*<sup>106</sup>, and from the fifth, sixth and seventh cervical nerves in *Gorilla*<sup>82</sup>.

## BIBLIOGRAPHY

1. **Adachi**,B (1900): Anatomische Untersuchungen an Japanern. III. Muskelvarietaten. Z.Morphol.Anthropol. 2, p211-222.
2. **Aziz**,MA and **Dunlap**,SS (1986): The human extensor digitorum profundus muscle with comments on the evolution of the primate hand. Primates. 27(3). p293-319.
3. **Beddard**,FE (1893): Contributions to the anatomy of the anthropoid apes. Trans.Zool.Soc.Lond. 13, p177-218.
4. **Berry**,RJA and **Newton**,HAS (1908): A study of the superficial veins of the superior extremity in 300 living subjects. Anat.Anz. 33, p591-601.
5. **Birmingham**,A (1896): The nerve of Wrisberg. J.Anat.Phys. 30, p63-69.

6. **Bischoff, TLW** (1870): Beiträge zur Anatomie des *Hylobates leuciscus* and zu einer vergleichenden Anatomie der Muskeln der Affen und des Menschen. Abh.Bayer.Akad.Wiss.München. Math.Phys.Kl. 10, p197-297.
7. **Bischoff, TLW** (1880): Beiträge zur Anatomie des Gorilla. Abh.Bayer.Akad.Wiss. 13(3), p1-48.
8. **Bouchet, A** (1973): Contribution à l'étude anatomique de la veine céphalique du bras. C.R.Ass.Anat.154, p971-985.
9. **Brooks, HSJ** (1885-6): On the morphology of the intrinsic muscles of the little finger, with some observations on the ulnar head of the short flexor of the thumb. J.Anat.Phys. 20, p645-661.
10. **Brooks, HSJ** (1887): On the short muscles of the pollex and hallux of the anthropoid apes, with special reference to the opponens hallucis. J.Anat.Phys. 22, p78-95.
11. **Champneys, F** (1872): On the muscles and nerves of a chimpanzee (*Troglodytes niger*) and a cynocephalus anubis. J.Anat.Phys. 6, p176-211.
12. **Chapman, HC** (1878): On the structure of the gorilla. Proc.Zool.Soc.Lond. p385-394.
13. **Chapman, HC** (1879): On the structure of the chimpanzee. Proc.Zool.Soc.Lond. p52-63.
14. **Chapman, HC** (1880): On the structure of the orang outang. Proc.Zool.Soc.Lond. p160-174.
15. **Church, WS** (1861/2): On the myology of the orang utang (*Simia morio*). Nat.Hist.Review. 1, p510-516, 2, p89-94, p414-423.
16. **Coleman, SS and Anson, BJ** (1961): Arterial patterns in the hand based upon a study of 650 specimens. Surg.Gynecol.Obstet. 113, p409-424.
17. **Cunningham, DJ** (1877): Note on a connecting twig between the anterior divisions of the first and second dorsal nerves. J.Anat.Phys. 11, p539-540.
18. **Cunningham, DJ** (1887): The flexor pollicis brevis and the flexor brevis hallucis in Man. Anat.Anz. 2, p186-192.



19. **Day, MH** and **Napier, J** (1963): The functional significance of the deep head of flexor pollicis brevis in primates. *Folia Primatol.* 1, p122-134.
20. **Duckworth, WLH** (1904): Dissections of the upper limb of *Gorilla*, *Hylobates* and *Cynocephalus*. Studies from the Anthropological Laboratory, the Anatomy School, Cambridge. Cambridge University Press, Cambridge. 16, p91-97.
21. **Duckworth, WLH** (1915): Morphology and anthropology. 2nd ed. Cambridge University Press, Cambridge.
22. **Duvernoy, M** (1855-6): Des caractères anatomiques de grands singes pseudo-anthropomorphes. *Arch. Mus. Natl. Hist. Nat. (Paris)*. 8, p1-248.
23. **Dwight, T** (1895): Notes on the dissection and brain of the chimpanzee "Gumbo". *Mem. Boston Soc. Nat. Hist.* 5, p31-51.
24. **Eisler, P** (1890): Das Gefäß- und periphere Nervensystem des Gorilla. Tausch and Grosse, Halle.
25. **Eisler, P** (1895): Die Homologie der Extremitäten. *Abh. Naturforsch. Ges. Halle*. 19, p87-346.
26. **Embleton** (1864): Cited in Chapman (1879).
27. **Fick, R** (1895a): Vergleichend-anatomische Studien an einem erwachsenen Orang-utang. *Arch. Anat. Physiol. Anat. Abt.* p1-100.
28. **Fick, R** (1895b): Beobachtungen an einem zweiten erwachsenen Orang-Utang und einem Schimpanse. *Arch. Anat. Physiol. Anat. Abt.* p289-318.
29. **Fitzwilliams, DCL** (1910): The short muscles of the hand of the agile gibbon (*Hylobates agilis*), with comments on the morphological position and function of the short muscles of the hand of man. *Proc. Roy. Soc. Edinb.* 30, p202-218.
30. **Forster, A** (1916): Die Mm. contrahentes und interossei manus in der Säugetierreihe und beim Menschen. *Arch. Anat. Physiol.* 16, p215-230.

31. **Frohse, F** and **Fränkel, M** (1908): Die Muskeln des menschlichen Armes. In: Bardeleben, K (ed); Handbuch der Anatomie des Menschen. Part 2, section 2, p1-414. Gustav Fischer, Jena.
32. **Glidden, EM** and **De Garis, CF** (1936): Arteries of the chimpanzee. I. The aortic arch; II. Arteries of the upper extremity; III. The descending aorta; IV. Arteries of the lower extremity. *Am.J.Anat.* 58(2), p501-527.
33. **Gratiolet, LP** and **Alix, PHE** (1866): Recherches sur l'anatomie de *Troglodytes aubryi*, chimpanzé d'une espèce nouvelle. *Nouv.Arch.Mus.Natl.Hist.Nat.(Paris)*. 2, p1-264.
34. **Hartmann, R** (1886): Anthropoid apes. D.Appleton and Co. New York.
35. **Hepburn, D** (1892): The comparative anatomy of the muscles and nerves of the superior and inferior extremities of the anthropoid apes. *J.Anat.Phys.* 26, p149-186, 324-356.
36. **Höfer, W** (1892): Vergleichend-anatomische Studien über die Nerven des Armes und der Hand bei den Affen und dem Menschen. *Münchener Med.Abh.* 30(7:3), p1-106.
37. **Howell, AB** and **Straus, WL Jr** (1931): The brachial flexor muscles in primates. *Proc.U.S.Natl.Mus.* 80(13), p1-30.
38. **Humphry, GM** (1866/7): On some points in the anatomy of the chimpanzee. *J.Anat.Phys.* 1, p254-268.
39. **Humphry, GM** (1873): Lectures on the varieties in the muscles of man, II. *Brit.Med.J.* p51-54.
40. **Huxley, TH** (1864): Lectures on the structure and classification of the Mammalia. *Med.Times and Gaz.(Lond.)*. 1, p564-565.
41. **Huxley, TH** (1871): The anatomy of vertebrated animals. J and A Churchill, London.
42. **Ikeda, A**; **Matsumoto, S** and **Tanaka, H** (1988): Comparative anatomical study of arteriographs of the hand of primates - deep palmar arterial arches and their

- correlating arteries in Cercopithecidae, Pongidae and Hominidae. *Acta Anat.* 133(1), p30-34.
43. **Ikeda, A; Matsumoto, S; Yoshi, I and Ikeda, K** (1993): Comparative anatomical studies of arteriographs of the hand and foot in primates including man. *Kaibogaku Zasshi.* 68(3), p263-80.
44. **Jungers, WL and Stern, JT Jr** (1981): Preliminary electromyographical analysis of brachiation in gibbon and spider monkey. *Int.J.Primatol.* 2(1), p19-33.
45. **Keith, A** (1894): Notes on a theory to account for the various arrangements of the flexor profundus digitorum in the hand and foot of primates. *J.Anat.Phys.* 28, p335-339.
46. **Keith, A** (1896): A variation that occurs in the manubrium sterni of higher primates. *J.Anat.Phys.* 30, p275-279.
47. **Keith, A** (1899): On the chimpanzees and their relationship to the gorilla. *Proc.Zool.Soc.Lond.* p296-312.
48. **Kohlbrügge, JHF** (1890/91): Versuch einer anatomie des Genus *Hylobates*. Muskeln und periphere Nerven. Zoologische Ergebnisse einer Reise in Niederländisch Ost-Indien. 1, p211-354; 2, p138-206. E.J.Brill; Leiden.
49. **Kohlbrügge, JHF** (1897): Muskeln und Periphere Nerven der Primaten, mit besonderer Berücksichtigung ihrer Anomalien. *Verh. K.Akad.Wet.* Amsterdam. Section 2, 5(6), p1-246.
50. **Koizumi, M and Sakai, T** (1995): The nerve supply to coracobrachialis in apes. *J.Anat.* 186, p395-403.
51. **Kosinski, C** (1927): The cutaneous innervation of the dorsum of the human hand. *J.Anat.* 61, p509-511.
52. **Landsmeer, JMF** (1986): A comparison of fingers and hand in *Varanus*, opossum and primates. *Acta Morphol.Neerl.Scand.* 24, p193-221.
53. **Lane, WA** (1885): Supernumerary cervico-dorsal vertebra-bearing ribs, with vertebral and costal asymmetry; abnormal articulation in a sternum. *J.Anat.Phys.* 19, p266-273.

54. **Langer, C** (1879): Die Muskeln der Extremitäten des Orang als Grundlage einer vergleichend-anatomischen Untersuchung.  
Sitzungsber. Kaiserl. Akad. Wiss. Wien. Math. Naturwiss. Cl. 80, p177-222.
55. **Leche, W** (1900): Muskulatur. Bronn's Klassen und Ordnungen des Thierreichs. 6(5), (Säugethiere: Mammalia), p649-919.
56. **Le Double, F** (1897): Traité des variations du système musculaire de l'homme et de leur signification au point de vue de l'anthropologie zoologique, I et II.  
Librairie C. Reinwald, Paris.
57. **Le Minor, JM** (1994): The sesamoid bone of *Musculus abductor pollicis longus* (os radiale externum or prepollex) in primates. *Acta Anat.* 150(3), p227-231.
58. **Leslie, DR** (1954): The tendons on the dorsum of the hand. *Aust. N. Z. J. Surg.* 23, p253-256.
59. **Lewis, OJ** (1965): The evolution of the mm. interossei in the primate hand.  
*Anat. Rec.* 153, p275-288.
60. **Loth, E** (1912): Beiträge zur Anthropologie der Negerweichteile (Muskelsystem).  
*Stud. Forsch. Menschen-u. Völkerkunde, Stuttgart.* 9, p1-254.
61. **Lubosch, W** (1899): Ein *M. coraco antibrachialis* beim Menschen. *Morphol. Jahrb.* 27(2), p309.
62. **MacAlister, A** (1871): On some points in the myology of the chimpanzee and of the primates. *Ann. Mag. Nat. Hist.* 7(2), p341-351.
63. **MacDowell, EC** (1910): Notes on the myology of *Anthropopithecus niger* and *Papio-thoth ibeanus*. *Am. J. Anat.* 10, p431-460.
64. **McMurrich, JB** (1902-3): The phylogeny of the forearm flexors. *Am. J. Anat.* 2, p177-209.
65. **Machado, AB** and **DiDio, LJ** (1967): Frequency of the *musculus palmaris longus* studied *in vivo* in some Amazon indians. *Am. J. Phys. Anthropol.* 27, p11-20.
66. **Mangini, U** (1960): Flexor pollicis longus muscle. Its morphology and clinical significance. *J. Bone. Jt. Surg.* 42A, p467-470.

67. **Manners-Smith, T** (1910a): The limb arteries of primates (part 1). *J. Anat. Phys.* 44, p271-302.
68. **Manners-Smith, T** (1910b): The limb arteries of primates (part I cont.). *J. Anat. Phys.* 45, 23-64.
69. **Marzke, MW; Wullstein, KL and Viegas, SF** (1992): Evolution of the power ("squeeze") grip and its morphological correlates in hominids. *Am. J. Phys. Anthropol.* 89, p283-298.
70. **Mayer, JC** (1856): Zur Anatomie des Orang-utang und des Schimpansen. *Arch. Naturgesch.* 22(1), p279-304.
71. **Michäelis, P** (1903): Beiträge zur vergleichenden Myologie des *Cynocephalus babuin*, *Simia satyrus*, *Troglodytes niger*. *Arch. Anat. Phys. Anat. Abt.* p205-256.
72. **Miller, RA** (1934): Comparative studies upon the morphology and distribution of the brachial plexus. *Am. J. Anat.* 54(1), p143-175.
73. **Miller, RA** (1952): The musculature of *Pan paniscus*. *Am. J. Anat.* 91(2), p182-232.
74. **Müller, E** (1903): Beiträge zur Morphologie des Gefasssystems. I. Die Arterien des Menschen. *Anat. Hefte.* 22, p279-574.
75. **Müller, E** (1905): Beiträge zur Morphologie des Gefasssystems. II. Die Arterien des Säugetiere. *Anat. Hefte.* 27, p73-241.
76. **Muller, T** (1959): Variations in the abductor pollicis longus and extensor pollicis brevis in the South African Bantu. *S. Afr. J. Lab. Clin. Med.* 5, p56-62.
77. **Nebotcegarra, J; Reinadelatorre, F and Perezberruezo, J** (1994): Accessory fasciculi of the human pronator teres muscle - incidence, morphological characteristics and relation to the median nerve. *Anat. Anz.* 176(3), p223-227.
78. **Parsons, FG and Robinson, A** (1899): Eighth report of the Committee of Collective Investigation of the Anatomical Society of Great Britain and Ireland for the year 1897-1898. *J. Anat. Phys.* 33, p189-203.

79. **Pira, A** (1913): Beiträge zur Anatomie des Gorilla. I. Das Extremitätenmuskelsystem. *Morphol. Jahrb.* 47, p309-354.
80. **Platzer, W** (1971): The blood vessels of the chimpanzee. In: Bourne, GH(ed); Behaviour, growth, and pathology of chimpanzees. Karger, Basel; p325-348.
81. **Primrose, A** (1900): The anatomy of the orang-outang. Univ. of Toronto Studies. Anat. series 1, p1-94.
82. **Raven, HC** (1950): Regional anatomy of the Gorilla. In: Gregory, WK(ed); The anatomy of the Gorilla. Columbia University Press, New York; p 15-188.
83. **Rolleston, G** (1868): On the homologues of certain muscles. *Trans. Linn. Soc.* 26.
84. **Saberton, CWS** (1906): The nerve plexuses of *Troglodytes niger*. *Studies in Anatomy, Univ. of Manchester.* 3, p165-270.
85. **Sherrington, CS** (1898): Experiments in examination of the peripheral distribution of the fibers of the posterior roots of some spinal nerves. Part II. *Phil. Trans. Roy. Soc. B.* 190, p45-186.
86. **Singh, SP; Ekandem, GJ and Bose, S** (1982): A study of the superficial veins of the cubital fossa in Nigerian subjects. *Acta Anat.* 114, p317-320.
87. **Sommer, A** (1907): Das Muskelsystem des Gorilla. *Jena. Z. Naturwiss.* 42, p181-308.
88. **Sonntag, CF** (1923): On the anatomy, physiology, and pathology of the chimpanzee. *Proc. Zool. Soc. Lond.* 23, p323-429.
89. **Sonntag, CF** (1924): On the anatomy, physiology, and pathology of the orang-outan. *Proc. Zool. Soc. Lond.* 24, p349-450.
90. **Straus, WL Jr** (1941a): The phylogeny of the human forearm extensors. *Human Biol.* 13, p23-50.
91. **Straus, WL Jr** (1941b): The phylogeny of the human forearm extensors (concluded). *Human Biol.* 13, p203-238.
92. **Straus, WL Jr** (1942): Rudimentary digits in primates. *Q. Rev. Biol.* 17, p228-243.

93. **Sullivan, WE** and **Osgood, CW** (1927): The musculature of the superior extremity of the orang-utan, *Simia satyrus*. *Anat.Rec.* 35(3), p193-239.
94. **Susman, RL** and **Stern, JT Jr** (1980): EMG of the interosseous and lumbrical muscles in the chimpanzee (*Pan troglodytes*) hand during locomotion. *Am.J.Anat.* 157, p389-397.
95. **Susman, RL**; **Jungers, WL** and **Stern, JT Jr** (1982): The functional morphology of the accessory interosseous muscle in the gibbon hand: determination of locomotor and manipulatory compromises. *J.Anat.* 134(1), p111-120.
96. **Sutton, JB** (1883): On some points in the anatomy of the chimpanzee (*Anthropopithecus troglodytes*). *J.Anat.Phys.* 18, p66-85.
97. **Symington, J** (1890): Observations on the myology of the gorilla and chimpanzee. *Rep.Brit.Assoc.Adv.Sci.* 59, p629-630.
98. **Testut, L** (1884): Les anomalies musculaires chez l'homme expliquées par l'anatomie comparée. Leur importance en anthropologie. G.Masson, Paris.
99. **Thiranagama, R**; **Chamberlain, AT** and **Wood, BA** (1989a): Valves in superficial limb veins of humans and nonhuman primates. *Clin.Anat.* 2, p135-145.
100. **Thiranagama, R**; **Chamberlain, AT** and **Wood, BA** (1989b): The comparative anatomy of the forelimb veins of primates. *J.Anat.* 164, p131-144.
101. **Thiranagama, R**; **Chamberlain, AT** and **Wood, BA** (1991): Character phylogeny of the primate forelimb superficial venous system. *Folia Primatol.* 57, p181-190.
102. **Todd, TW** (1912): The hinder end of the brachial plexus in man and mammals. *Anat.Anz.* 42, p129-144.
103. **Tuttle, RH** (1969): Quantitative and functional studies on the hands of the Anthropoidea. *J.Morphol.* 128, p309-364.
104. **Vrolik, W** (1841): Recherches d'anatomie comparée, sur le chimpansé. Johannes Miller, Amsterdam.
105. **Wagenseil, F** (1936): Untersuchungen über die Muskulatur der Chinesen. *Z.Morphol.Anthropol.* 36, p39-150.

106. **Warwick, P** and **Williams, PL** (1973): Gray's Anatomy. 35th British Edition. Saunders Co., Philadelphia.
107. **Westling, C** (1884): Beiträge zur Kenntniss des peripherischen Nervensystems. (I. *Pithecus satyrus*; II. *Ornithorhyncus paradoxus*). Bihang K.Svenska Vetensk.Akad.Handl.(Stockholm). 9(8), p1-48.
108. **Wilder, B** (1862): Contributions to the comparative myology of the chimpanzee. Boston J.Nat.Hist. 6, p352-384.
109. **Wood, J** (1864): On some varieties in human myology. Proc.Roy.Soc. 13, p299-303.
110. **Wood, J** (1865): Additional varieties in human myology. Proc.Roy.Soc. 14, p379-393.
111. **Wood, J** (1866): Variations in human myology observed during the Winter Session of 1865-6 at King's College, London. Proc.Roy.Soc. 15, p229-244.
112. **Wood, J** (1867a): On human muscular variations and their relation to comparative anatomy. J.Anat.Phys. 1, p44-59.
113. **Wood, J** (1867b): Variations in human myology observed during the Winter Session of 1866-7 at King's College, London. Proc.Roy.Soc. 15, p518-545.
114. **Wood, J** (1868): Variations in human myology observed during the Winter Session of 1867-8 at King's College, London. Proc.Roy.Soc. 16, p483-525.
115. **Ziegler, AC** (1964): Brachiating adaptations of chimpanzee upper limb musculature. Am.J.Phys.Anthropol. 22, p15-32.



## 3.5 BACK

### 3.5.1 MUSCLES

#### 3.5.1.1 Extrinsic

##### 3.5.1.1.1 Cranio-cervical

###### *Splenius capitis*

No information for *Hylobates*.

In great apes and *Homo* splenius capitis originates from the spinous processes of C5 to T3<sup>28, 34, 36, 37, 42</sup>, extending further superiorly to C4 in *Homo*, *Gorilla* and *Pongo*<sup>34, 37, 42</sup>, to C3 in *Gorilla* and *Pongo*<sup>34, 37</sup>, and to C2 in *Pongo* alone<sup>37</sup>. Inferior extension of the origin is present to T4 in both species of *Pan* and *Pongo*<sup>28, 36, 37</sup>, and as far as T5-T7 in *Pan*<sup>36</sup>, in which the splenius capitis and cervicis form a single mass<sup>36</sup>. The muscle also takes origin from the supraspinous ligaments in *Gorilla* and *Pongo*<sup>34, 37</sup>.

The insertion of the muscle in great apes and *Homo* is to the mastoid process and the occipital bone beneath the superior occipital line<sup>9, 28, 34, 36, 37, 42</sup>, in *Gorilla* and *Pongo* beginning more inferiorly on the occipital bone, in the region of the occipital crest<sup>34, 37</sup>. There is a slip to levator scapulae in *Pan*<sup>36</sup>.

Innervation in *Homo* and *Pan paniscus* is from the dorsal rami of the cervical nerves<sup>28, 42</sup>.

###### *Splenius cervicis*

No information for *Hylobates*.

It takes origin from T3 to T6 in *Homo*<sup>42</sup>, from T5 in *Pan paniscus*<sup>28</sup>, and in *Gorilla* from T1 to T3 and their supraspinous ligaments<sup>34</sup>.

The muscle may be absent from *Pongo*<sup>37</sup>, or part of a splenius mass as in *Pan*<sup>36</sup>.

Splenius cervicis receives a slip from longissimus cervicis at the level of C2 in *Pan paniscus*<sup>28</sup>.

Insertion in *Homo*, *Pan paniscus* and *Gorilla* is to the transverse process of C1<sup>28, 34, 42</sup>, extending inferiorly to the transverse process of C2 in *Homo* and *Gorilla*<sup>34, 42</sup>. In *Pan* it blends with the levator scapulae<sup>36</sup>.

Innervation in *Homo* and *Pan paniscus* is from the dorsal rami of the lower cervical nerves<sup>28,42</sup>.

### 3.5.1.1.2 Cervicothoracic

#### *Serratus posterior superior*

No information for *Hylobates*.

The muscle originates from the spinous processes of C7 in African apes and *Homo*<sup>28, 34, 36, 42</sup>, additionally from C6 in *Homo*, *Pan paniscus* and *Gorilla*<sup>28, 34, 42</sup>, and from T1 in *Homo* and both species of *Pan*<sup>28, 36, 42</sup>. The origin extends inferiorly to T2 in *Homo* and *Pan paniscus*<sup>28, 42</sup>, and superiorly as far as C3 in *Pan paniscus* and *Gorilla*<sup>28, 34</sup>. *Gorilla* possesses additional digitations from C1 and C2<sup>34</sup>.

*Serratus posterior superior* is absent or represented by tendinous threads in *Pongo*<sup>35, 37</sup>, and may be absent from *Homo* as a variant<sup>42</sup>.

The muscle inserts in African apes and *Homo* onto the second to fifth ribs lateral to their angles<sup>23, 28, 34, 36, 42</sup>, extending superiorly to the first rib in *Pan*<sup>36</sup>, and inferiorly to the sixth rib in *Gorilla*<sup>34</sup>.

It is innervated by branches of the second to fifth intercostal nerves in *Homo*<sup>42</sup>, the first four intercostal nerves in *Pan paniscus*<sup>28</sup>, and the first five intercostal nerves in *Gorilla*<sup>34</sup>.

### 3.5.1.1.3 Thoracolumbar

#### *Serratus posterior inferior*

No information for *Hylobates*.

In great apes and *Homo* serratus posterior inferior originates from the thoracolumbar fascia<sup>28, 36, 37, 42</sup>.

The muscle is absent from *Gorilla*<sup>34</sup>, and occasionally absent from *Homo*<sup>42</sup>.

Serratus posterior inferior inserts onto the inferior four or five ribs, lateral to their angles, in great apes and *Homo*<sup>28, 36, 37, 39, 42</sup>.

Innervation is via the ventral rami of the ninth to twelfth thoracic spinal nerves in *Homo* and *Pan paniscus*<sup>28, 42</sup>.

### 3.5.1.1.4 Upper limb

#### *Dorsoepitrochlearis* See 3.4.1.2.2

#### *Latissimus dorsi*

In great apes and *Homo* latissimus dorsi takes origin from the supraspinous ligaments and spinous processes of T9 to T12, extending superiorly to T8 in all except *Gorilla*<sup>5, 15, 28, 34, 36, 37, 38, 42</sup> and as far superiorly as T7 in *Homo*<sup>42</sup>. In great apes and *Homo*, the muscle takes origin from the thoracolumbar fascia<sup>4, 34, 36, 37, 38, 42</sup>, and in great apes (except *Pan paniscus*<sup>28</sup>) and *Homo* from the posterior third of the iliac crest<sup>4, 5, 15, 24, 28, 34, 37, 38, 42, 45</sup>. The iliac origin in great apes reaches almost to the anterior superior

iliac spine<sup>5, 15, 34, 36, 45</sup>. The costal part of the origin involves three or four ribs in *Homo* and *Pan*<sup>4, 5, 15, 24, 36, 42</sup>, five ribs in *Pan paniscus* and *Hylobates*<sup>15, 28</sup>, or six ribs in *Gorilla* and *Pongo*<sup>4, 15, 31</sup>. The costal origin may be absent from *Pongo*<sup>15, 38</sup>. Fibres of origin from the inferior scapular angle, frequently present in *Homo*, are absent from all apes<sup>15, 28, 36, 37, 38</sup> except *Pan paniscus*<sup>28</sup>.

Latissimus dorsi is fused superiorly with trapezius in great apes<sup>24, 34, 38</sup>.

In all apes and *Homo* the flat tendon passes to insert on the floor of the intertubercular groove of the humerus<sup>4, 5, 10, 15, 24, 28, 34, 36, 37, 38</sup>, in common with the insertion of teres major in all except *Gorilla*<sup>15, 34</sup>, 4/5 *Pan*<sup>4, 5, 15, 24</sup> and 3/6 *Pongo*<sup>15, 33</sup>, although in these specimens of *Pan* and *Pongo* a slip passes to the posterior aspect of the tendon of teres major, and inserts anterior to it<sup>5, 15, 45</sup>. Coracobrachialis inserts onto the tendon of insertion of latissimus dorsi in *Pongo*<sup>4</sup>.

Latissimus dorsi is innervated in all apes and *Homo* by the thoracodorsal nerve<sup>5, 15, 28, 42</sup>.

#### *Levator scapulae*

No information for *Hylobates*.

Levator scapulae takes origin in great apes and *Homo* by four slips from the dorsal tubercles of the transverse processes of C1 to C4<sup>15, 28, 34, 37, 38, 42, 43</sup>, with the exception of both species of *Pan* in which the origin is shorter, from C1 and C2<sup>5, 45</sup>, C1 to C3<sup>15, 28</sup>, or C2 and C3<sup>14</sup>, or longer from C1 to C5<sup>36, 39</sup>. A single specimen of *Pongo* has 5 slips of origin, with 2 slips coming from C3 and fusing soon afterwards<sup>38</sup>. The origin in *Homo* may be from all cervical vertebrae, or as few as two, although larger numbers are more common<sup>42, 45</sup>. Levator scapulae takes origin

in *Pongo* also from the outer surface of the mastoid process under the sterno (cleido)mastoid muscle<sup>15</sup>.

The slips from C3, C4 and C5 in the *Pan* specimens with the long origin, fuse with splenius cervicis<sup>36</sup>. The C1 and C2 slips in *Gorilla* fuse with atlantoclavicularis, the C2 slip is fused with scalenus posterior, and the C2, C3 and C4 slips are fused with iliocostalis cervicis<sup>34</sup>.

The insertion of levator scapulae in great apes and *Homo* is to the part of the medial scapular border inferior to the superior angle, not occupied by the rhomboidei<sup>4, 15, 28, 34, 36, 37, 38, 39, 42, 45</sup>. The insertion may be split into two parts in *Pan*<sup>4</sup>.

Innervation of levator scapulae is from the third and fourth cervical nerves in *Homo*<sup>42</sup>, from the third and fifth cervical nerves<sup>36</sup> or the fourth cervical nerve<sup>5</sup> alone in *Pan*, the dorsal scapular nerve in *Pan paniscus*<sup>28</sup>, and from the second to fourth cervical nerves in *Gorilla*<sup>34</sup>.

#### *Rhomboid major and minor*

No information for *Hylobates*.

The rhomboids are present as a single muscle mass in great apes<sup>4, 15, 31, 23, 28, 36, 37, 38, 39, 40, 43</sup>, with the exception of single specimens of *Pan*<sup>5</sup> and *Pongo*<sup>4</sup> in which they are separated, as in *Homo*<sup>42</sup>.

Treating the human muscle as if it had a combined origin, which may be present as a variation<sup>42</sup>, the rhomboidei take origin from the spinous processes of C6 to T4 in great apes and *Homo*<sup>4, 28, 34, 36, 37, 38, 42</sup>, extending superiorly to C3 in great apes<sup>4, 28, 34, 37, 38</sup>, and to the medial portion of the superior nuchal line of the occipital bone in a single specimen of *Pan*<sup>14</sup>, in *Pongo*<sup>4, 15, 31, 37, 38</sup>, and as a variation in *Homo*<sup>42</sup>. This

occipital slip, absent from *Gorilla*, has been called the *rhomboid capitis* or *omoccipitalis*<sup>11,12, 15, 36, 37, 38</sup>. The inferior extent of the origin is to T5 in *Homo* and *Pan*<sup>5</sup>, T6 in *Gorilla* and *Pongo*<sup>15, 34, 37, 38</sup>, and to T7 in *Pongo* alone<sup>38</sup>.

The rhomboidei insert in great apes and *Homo* to the medial scapular border between the inferior scapular angle and the scapular margin at the base of the scapular spine<sup>4, 5, 15, 28, 34, 36, 37, 38, 42</sup>.

Innervation of the rhomboidei is via the dorsal scapular nerve in *Homo* and *Pan paniscus*<sup>28, 42</sup>, and from the fifth cervical nerve in *Pan*<sup>5, 36</sup>.

### *Trapezius*

Trapezius originates in *Homo* and all apes except *Hylobates*, from the superior nuchal line and the external occipital protuberance<sup>15, 28, 34, 36, 37, 38, 42</sup>. There is no occipital origin in *Hylobates*<sup>37</sup>, and this may be absent from *Homo*<sup>42</sup>. The remainder of the origin is from the spinous processes and supraspinal ligaments of C7 and all the thoracic vertebrae in great apes and *Homo*<sup>36, 37, 38, 42</sup>, while great apes have an extensive cervical origin from C2 to C6<sup>28, 36, 37, 38</sup>, extending to C1 in both species of *Pan*<sup>28, 36</sup>. The cervical origin begins at C5 in *Hylobates*<sup>37</sup>. The thoracic part of the origin ends at T9 in *Pan paniscus*<sup>28</sup>, and may continue inferiorly onto the last rib in *Gorilla*<sup>34</sup>, or L1 in *Pongo*<sup>38</sup>. In *Homo*, the thoracic origin may end at T8 as a variation<sup>42</sup>.

In the midspinal region in *Homo*, the origin is tendinous<sup>42</sup>, and this is present in *Pan paniscus*<sup>28</sup>, but absent from *Pan* and *Pongo*<sup>36, 37, 38</sup>.

The *nuchal ligament* is absent from all apes with the exception of *Hylobates*<sup>37</sup>, thus the nuchal origin present in *Homo*<sup>42</sup> is absent from great apes<sup>31, 36, 37, 38</sup>.

Fusion with latissimus dorsi is present in 2/5 *Pan*<sup>39</sup>, *Gorilla*<sup>34</sup> and *Pongo*<sup>38</sup>, and is also fused with the deltoid muscle in *Pan*<sup>36</sup>, but not in *Pongo*<sup>37</sup>. In great apes but not in *Homo*<sup>21</sup>, cranial trapezius is thicker than the caudal portion<sup>2, 27, 34, 37</sup>. The middle part of trapezius is most strongly developed in hylobatids, with thinner cranial and caudal margins<sup>1</sup>. Oxnard has produced tables of relative weights and comparative features of trapezius in *Homo*, brachiators, semi-brachiators and quadrupeds<sup>32</sup>.

Insertion is onto the lateral third of the clavicle, the whole length of the superior border of the scapular spine and the acromion process in great apes and *Homo*<sup>4, 15, 28, 34, 36, 37, 38, 42</sup>. There is no special insertion into the root of the scapular spine in *Pan* or *Pongo*<sup>37</sup>, unlike *Homo*<sup>42</sup>. Fibres pass into the coracoclavicular ligament from the deep surface of trapezius in *Gorilla*<sup>34</sup>, and in *Pongo* some fibres insert into the infraspinatus fascia<sup>38</sup>.

Innervation of trapezius in *Homo*, *Pan paniscus* and *Gorilla* is from the accessory nerve<sup>28, 34, 42</sup>, and also from muscular branches of the third and fourth cervical nerves in *Homo* and *Pan*<sup>36, 42</sup> and the third cervical nerve in *Pan paniscus*<sup>28</sup>.

#### 3.5.1.1.5 Scapular

*Deltoid* See 3.4.1.1

*Infraspinatus*

No information for *Hylobates*.

Infraspinatus takes origin in great apes and *Homo* from the infraspinous fossa and the infraspinatus fascia<sup>4, 28, 34, 36, 38, 42</sup>. In *Homo*, *Pan*, and *Pongo* it also takes origin from the scapular spine<sup>4, 38, 42</sup>, while *Pan* and *Pongo* share an origin from the intermuscular septa<sup>4</sup>.

Larger than supraspinatus in all apes and *Homo*<sup>15, 18, 36, 37, 42</sup>, the muscle is fused with supraspinatus at its insertion in *Pongo*<sup>4, 38</sup>, and also in *Gorilla* and *Pongo* with teres minor<sup>34, 38</sup>, which occurs in *Homo* as a variant<sup>42</sup>.

The insertion of infraspinatus in great apes and *Homo* is to the middle facet of the greater tubercle of the humerus<sup>4, 20, 28, 34, 36, 37, 38, 42</sup>, extending in great apes to the capsule of the shoulder joint<sup>4, 34, 38</sup>.

Innervation is by the suprascapular nerve in *Homo*, *Pan paniscus* and *Gorilla*<sup>28, 34, 42</sup>.

### *Subscapularis*

In all apes and *Homo* subscapularis originates from the subscapular fossa<sup>4, 15, 20, 34, 36, 37, 38, 42</sup>, in *Pan* taking additional fascial origin from the inferior scapular angle<sup>4</sup>.

Accessory bundles are present as a variation in *Homo*<sup>38</sup> and an accessory bundle is present in a specimen of *Pan*, originating from the superior part of the lateral scapular border, inserting into the capsular ligament and the humerus one centimetre distal to the greater tubercle<sup>45</sup>. An independent superior bundle is present in a specimen of *Pongo*<sup>38</sup>.

Triangular in *Homo* and *Gorilla*<sup>34, 42</sup>, the muscle consists of three parts in *Homo* and *Pan*<sup>20, 36, 42</sup>, seven or more fascicles in *Gorilla*<sup>34, 37</sup> and is continuous in *Pongo*<sup>37</sup>.

Insertion in all apes and *Homo* is onto the lesser tubercle of the humerus<sup>4, 15, 34, 36, 37, 38, 42, 45</sup>, extending onto the shaft below in *Homo*, *Pan* and *Pongo*<sup>4, 36, 42, 45</sup>, but not in *Gorilla*<sup>34</sup>. Subscapularis also inserts into the capsule of the shoulder joint in the African apes<sup>34, 36, 45</sup>, while in *Homo* it passes in close proximity to the joint capsule<sup>42</sup>.



Innervation in *Homo* and *Pan paniscus* is from the subscapular nerve<sup>28, 42</sup>, with five subscapular nerves supplying the muscle in *Gorilla*<sup>34</sup>.

### *Supraspinatus*

Supraspinatus originates in great apes and *Homo* from the supraspinatus fossa<sup>4, 28, 34, 36, 38, 42</sup>, while *Homo* and *Gorilla* share an origin from the supraspinatus fascia<sup>34, 42</sup>.

In *Pongo*, the origin extends from the suprascapular notch to the superior angle, and on the medial border to the base of the scapular spine, and along the scapular spine to the acromion<sup>38</sup>.

Smaller than infraspinatus in all apes and *Homo*<sup>15, 18, 36, 37, 42</sup>, in *Homo*, *Gorilla* and *Pongo* the muscle is fused with the capsule of the shoulder joint<sup>34, 38, 42</sup>, and in *Pan* with the tendon of pectoralis minor<sup>15</sup>. Supraspinatus is fused distally with infraspinatus in *Pongo* alone<sup>4, 38</sup>.

Insertion of supraspinatus is onto the superior facet of the greater tubercle of the humerus in great apes and *Homo*<sup>28, 34, 36, 37, 38, 42</sup>.

Supraspinatus is innervated by the subscapular nerves in *Homo*<sup>42</sup>, by the suprascapular nerve in *Pan paniscus*<sup>28</sup>, but is described in *Gorilla* as being innervated by the infraspinatus nerve<sup>34</sup>.

### *Teres major*

In all apes and *Homo* teres major originates from the lateral border of the dorsal surface of the scapula<sup>4, 15, 28, 36, 37, 38, 42</sup>. The scapular origin involves a third of the lateral border in *Homo*, *Gorilla* and *Pongo*<sup>4, 15, 37, 38, 42</sup>, half the border in both species of *Pan*<sup>15, 28, 36</sup> and more than half in *Hylobates*<sup>15</sup>. Fibres of origin from the adjacent infraspinous fossa are present in *Homo* and *Pan*<sup>5, 42, 45</sup>. In *Homo*, *Pan* and

*Pongo* there are fibres of origin from the intermuscular septa with teres minor and infraspinatus<sup>4, 42</sup>. In 1/7 *Pongo*, the muscle was fused at origin with infraspinatus<sup>38</sup>, and with subscapularis in 2/7 *Pongo*<sup>37, 38</sup>.

A flat strap-like muscle, it is overlapped laterally by the long head of triceps in *Homo* and great apes<sup>5, 34, 38, 42</sup>, and medially by latissimus dorsi in *Homo* and *Gorilla*<sup>34, 42</sup>. Teres major may be absent from *Homo* as a variant<sup>42</sup>.

Insertion in all apes and *Homo* is onto the medial lip of the intertubercular groove anterosuperior to the insertion of coracobrachialis<sup>15, 36, 37, 38, 42</sup>, in African great apes and *Homo* posterior to the insertion of latissimus dorsi<sup>42</sup>. Teres major is fused with latissimus dorsi in 2/7 *Pan*<sup>15, 36</sup>, *Pan paniscus*<sup>28</sup>, 1/2 *Gorilla*<sup>34</sup>, 4/7 *Pongo*<sup>4, 15, 37, 38</sup> and *Hylobates*<sup>15</sup>, and as a variant in *Homo*<sup>42</sup>.

In *Homo* and African apes teres major is supplied by the subscapular nerves<sup>5, 15, 28, 34, 42</sup>.

#### *Teres minor*

In all apes and *Homo* originates from the lateral border of the dorsal surface of the scapula, involving the superior two-thirds in *Homo*<sup>42</sup>, 1/4 *Pan*<sup>15</sup> and 1/5 *Pongo*<sup>38</sup>, the superior half in 1/4 *Pan*<sup>36</sup>, *Pan paniscus*<sup>28</sup>, and 2/5 *Pongo*<sup>15, 37</sup>, the middle third in 1/4 *Pan*<sup>5</sup> and *Gorilla*<sup>15</sup>, while in *Hylobates* the origin occupies only the superior part of the border close to the glenoid cavity<sup>15</sup>. In *Homo* and great apes the muscle also has fibres of origin from the intermuscular septum with infraspinatus<sup>4, 34, 37, 42</sup>, and in *Homo* and *Pan* from the intermuscular septum with teres major<sup>4, 42</sup>. In *Homo* and *Pongo* teres minor is separated from teres major by the long head of triceps<sup>38, 42</sup>.

The muscle may be fused with infraspinatus as a variant in *Homo*<sup>42</sup>, and is so fused in *Gorilla*<sup>34</sup> and *Pongo*<sup>37</sup>.

The insertion in all apes and *Homo* is onto the inferior facet of the greater tubercle of the humerus<sup>4, 15, 20, 36, 37, 38, 42</sup>, extending to the shaft just below in *Homo* and African apes<sup>20, 36, 42</sup>, and onto the humeral head in *Pan* and *Pongo*<sup>4</sup>. In *Pan paniscus* the muscle also inserts into the posterior capsule of the shoulder joint<sup>28</sup>, and in *Pan* onto the scapular ligament<sup>4</sup>.

Innervation is from the axillary (circumflex) nerve in *Homo* and African great apes<sup>28, 34, 36, 42</sup>.

### 3.5.1.2 Intrinsic

#### 3.5.1.2.1 Long

##### *Erector spinae*

No information for *Hylobates*.

Originates in great apes and *Homo* from the dorsum of the sacrum and the sacroiliac ligaments, from the iliac crest, and the spinous processes of the lumbar vertebrae<sup>28, 34, 36, 37, 41, 42</sup>. In African apes and *Homo* it also takes origin from the thoracolumbar fascia<sup>34, 36, 42</sup>.

#### 3.5.1.2.1.1 Lateral

##### *Iliocostalis*

No information for *Hylobates*.

The costal origin of iliocostalis is from all the ribs in *Pan* and *Pongo*<sup>36, 37</sup>, from all ribs except the first two in *Homo* and *Gorilla*<sup>34, 42</sup>, and from all except the first four ribs in *Pan paniscus*<sup>28</sup>.

The origin of iliocostalis is fused with longissimus in *Homo*, African apes and *Pongo*<sup>28, 34, 36, 37, 42</sup>, while the cervical part of iliocostalis is fused with levator scapulae and splenius cervicis in *Gorilla*<sup>34</sup>.

The insertion in the cervical region is to the transverse processes of C4 to C7 in *Homo*<sup>42</sup>, C7 and T1 in *Pan paniscus*<sup>28</sup>, C2 to C4 in *Gorilla*<sup>34</sup> and C4 to C6 in *Pongo*<sup>37</sup>. The rest of the muscle inserts onto the first to sixth ribs in *Homo*<sup>42</sup>, the first to ninth ribs in *Pan*<sup>36</sup>, the seventh to fourteenth ribs in *Pan paniscus*<sup>28</sup>, the twelfth and thirteenth ribs in *Pan* and *Gorilla*<sup>34, 36</sup> and the first to twelfth ribs in *Pongo*<sup>37</sup>.

Innervation in *Homo* and *Pan paniscus* is from the dorsal rami of the spinal nerves<sup>28,</sup>

<sup>42</sup>.

#### 3.5.1.2.1.2 Intermediate

##### *Longissimus*

No information for *Hylobates*.

In great apes and *Homo*, iliocostalis originates in addition from the transverse processes of the lumbar vertebrae<sup>28, 34, 37, 41, 42</sup>. The thoracic origin is from the transverse processes of T1 to T6 in great apes<sup>28, 34, 36</sup> except *Pongo*, in which the inseparable thoracic part arises from the transverse processes of T1 to T4, as in *Homo*<sup>37, 42</sup>. The inferior extent of the thoracic origin extends to T8 in *Gorilla*<sup>34</sup>. In *Pan* there is also an origin from the spinous processes of the last two thoracic vertebrae, T12 and T13<sup>36</sup>. In the cervical region, the origin is as far superiorly as the transverse process of C5 in *Homo* and *Gorilla*<sup>34, 42</sup>, C4 in *Pongo*<sup>37</sup>, and C3 in *Pan paniscus*<sup>28</sup>.

In *Homo* and both species of *Pan* and *Homo*, longissimus is fused with iliocostalis<sup>28, 34, 36, 37, 42</sup>, in *Pan paniscus* sending slips to splenius cervicis and longus capitis and cervicis<sup>28</sup>. In *Pan* and *Pongo* the muscle is fused with semispinalis capitis<sup>36, 37</sup>, in *Pan* also with scalenus posterior<sup>36</sup>.

The cranial insertion of longissimus is to the occiput in great apes<sup>28, 36, 37</sup>, including the mastoid process in *Homo*, *Pan paniscus* and *Gorilla*<sup>28, 34, 42</sup>.

The cervical insertion in great apes and *Homo* is onto the transverse processes of C3 to C5<sup>28, 34, 36, 37, 42</sup>, extending superiorly to C2 in all these with the exception of *Pan*<sup>28, 34, 37, 42</sup>, inferiorly to C6 in *Pongo* and *Pan paniscus*<sup>28, 37</sup>, and to C7 in *Gorilla*<sup>34</sup>. An insertion onto the atlas is present in *Pan* and *Gorilla*<sup>34, 36</sup>.

In the thoracic region, longissimus inserts onto the transverse processes of the thoracic vertebrae in *Homo* and both species of *Pan*<sup>28, 36, 42</sup>. In all great apes and *Homo* with the exception of *Pongo* longissimus inserts onto the ribs between the costal angle and the transverse processes of the thoracic vertebrae<sup>36</sup>. In *Homo* and *Gorilla* this involves all the ribs<sup>34, 42</sup>, while in both species of *Pan* the extent of the costal insertion is from the fourth rib to the last rib<sup>28, 36</sup>.

Innervated by branches from the dorsal rami of the spinal nerves in *Homo*, *Pan paniscus* and *Gorilla*<sup>28, 34, 42</sup>.

#### 3.5.1.2.1.3 Medial

##### *Spinalis*

No information for *Pongo* or *Hylobates*.

In *Homo* and African apes spinalis originates from the spinous processes of T11 and T12<sup>28, 34, 36, 42</sup>. It extends superiorly to T10 in *Homo* and *Pan paniscus*<sup>28, 42</sup>, reaching its most superior origin at T9 in *Gorilla*<sup>34</sup>. The origin extends inferiorly to T13 in *Gorilla*<sup>34</sup>, reaching L1 to L3 in *Homo* and *Pan paniscus*<sup>28, 42</sup>. The muscle is fused with semispinalis capitis in *Pan* and *Gorilla*<sup>34, 36</sup>. A cervical part of the muscle, originating in *Homo* from T2 to T6<sup>42</sup>, is not present in African apes<sup>28, 34, 36</sup>.

The insertion of spinalis is to the spinous processes of T2 to T6 in African apes and *Homo*<sup>28, 34, 36</sup>, extending superiorly to T1 in *Pan*<sup>36</sup>, and to C7 in *Pan paniscus* and *Gorilla*<sup>28, 34</sup>. The superior extent of the insertion in *Gorilla* continues as far as C3<sup>34</sup>, which may correspond to the insertion of spinalis cervicis in *Homo*, which involves C2 to C4<sup>42</sup>. The insertion extends inferiorly in *Homo* and both species of *Pan* to T7 and T8<sup>28, 36</sup>.

Innervated by branches from the dorsal rami of the spinal nerves in *Homo* and *Pan paniscus*<sup>28, 42</sup>.

### 3.5.1.2.2 Short

#### 3.5.1.2.2.1 Transversospinal

##### *Semispinalis thoracis*

No information for *Gorilla* or *Hylobates*.

Semispinalis thoracis is separable at origin from semispinalis cervicis in *Homo* and *Pongo*<sup>37, 42</sup>, but not in *Pan*<sup>36, 44</sup>. In both *Homo* and *Pongo*, the muscle originates from the transverse processes of T6 to T11<sup>37, 42, 44</sup>, extending superiorly to T5 in *Homo*<sup>42</sup> and inferiorly to T12 in *Pongo*<sup>37</sup>.

Semispinalis thoracis has not been described in *Pan paniscus* or *Gorilla*<sup>28, 34</sup>. It has a combined origin with semispinalis cervicis in *Pan*<sup>36, 44</sup>, which is described with the latter muscle.

The insertion of semispinalis thoracis in *Homo*, *Pan* and *Pongo* is to the spinous processes of T2 and T3<sup>36, 37, 42, 44</sup>, extending superiorly to C6 in *Homo* and *Pongo*<sup>37, 42</sup>. The insertion extends inferiorly to T4 in *Homo* and *Pongo*<sup>37, 42, 44</sup>, and may reach as far inferiorly as T8 in *Pan*<sup>44</sup>.

### *Semispinalis cervicis*

No information for *Hylobates*.

In great apes and *Homo* semispinalis cervicis originates from the transverse processes of T1 to T4<sup>28, 34, 36, 37, 42, 44</sup>, extending inferiorly to T7 in *Homo* and *Gorilla*<sup>34, 42</sup>, to T10 in *Pan*<sup>44</sup> and in *Gorilla* and *Pongo* also originating from the articular processes of C4 to C7<sup>34, 37</sup>. The origin extends superiorly to the articular process of C3 in *Gorilla*<sup>34</sup>. In *Pan* and *Gorilla* semispinalis cervicis also takes origin from the spinalis muscles<sup>34, 44</sup>.

The combined origin of semispinalis thoracis and cervicis in *Pan* involves the transverse processes of all the thoracic vertebrae and the articular processes of C2 to C7<sup>36, 42</sup>. Winckler puts the division between thoracis and cervicis at the level of its seventh fascicle, which arises from T7 to T10 and inserts onto T1<sup>44</sup>.

The insertion of semispinalis cervicis in great apes and *Homo* is to the spinous processes of C2 to C5<sup>28, 34, 36, 37, 42, 44</sup>, extending superiorly to C1 in both species of *Pan*<sup>28, 36</sup>. The inferior extent of the insertion is to C6 in *Homo* and both species of *Pan*<sup>28, 36, 42, 44</sup>, reaching inferiorly to C7 in *Gorilla*<sup>34</sup> and as far as T1 in *Pan*<sup>44</sup>.

### *Semispinalis capitis*

No information for *Hylobates*.

*Semispinalis capitis* originates in great apes and *Homo* from the articular processes of C5 to C7<sup>28, 34, 36, 37, 42, 44</sup>, extending superiorly to C4 in *Homo* and *Pan paniscus*<sup>28, 42</sup>, to C3 in *Pan* and *Pongo*<sup>34, 36, 37, 44</sup>, and further to C2 in *Gorilla*<sup>34</sup>. The inferior extension of the origin is to T4 in *Pan paniscus*<sup>28</sup>, extending further inferiorly to T5 in *Gorilla*<sup>34</sup>, and to T6 in *Pan*<sup>36</sup>, *Pongo*<sup>37</sup> and as a variant in *Homo*<sup>42, 44</sup>. It may extend as far inferiorly as T7 in *Homo* and *Pan*<sup>42, 44</sup>. There is a slip of origin from the spinous process of C7 occasionally in *Homo*<sup>42</sup> and in *Pongo*<sup>37</sup>, but not in *Pan*<sup>36</sup>.

*Semispinalis capitis* is fused with *longissimus capitis* in *Pongo*<sup>37</sup>, with *longissimus thoracis* and *spinalis thoracis* at its origin in *Pan*<sup>36</sup>, and with *semispinalis cervicis* in *Gorilla*<sup>34</sup>.

The insertion of *semispinalis capitis* is to the occipital bone between the superior and inferior nuchal lines in great apes and *Homo*<sup>28, 34, 36, 37, 42</sup>.

*Semispinalis capitis* in *Pongo* has, on its internal surface, a separate slender Y-shaped bundle of fibres, the vertical limb arising from fascia covering *semispinalis capitis* and the two diverging limbs blending with *capitis* itself before its insertion into the occipital bone<sup>37</sup>. This is the *biventer cervicis*, which is usually blended with *semispinalis capitis* in *Homo*<sup>42</sup>, but may be a separate muscle<sup>44</sup>. This fasciculus is not separable from the muscle in *Pan*<sup>36</sup>, although a tendinous intersection in the muscle, as in *Homo*<sup>44</sup>, is present in both species of *Pan*<sup>28, 44</sup>.



Innervation of the semispinales in *Homo* is from the dorsal rami of C1 to C6 and T4 to T6<sup>42</sup> and by the dorsal rami of C2 to T3 in *Gorilla*<sup>34</sup>, while semispinalis cervicis and capitis are supplied by the dorsal rami of the cervical nerves in *Pan paniscus*<sup>28</sup>.

### *Multifidus*

No information for *Pongo* or *Hylobates*.

Originates in *Homo* and African apes from the sacrum and sacroiliac ligaments, the mammillary processes of the lumbar vertebrae, the transverse processes of the thoracic vertebrae, and the articular processes of C7 to C4<sup>28, 34, 36, 42, 44</sup>, extending superiorly to C3 in *Pan paniscus*<sup>28</sup>. The inferior extent of the origin in *Homo* is S4<sup>42, 44</sup>, while in *Pan* it is Co2<sup>44</sup>.

Lying subjacent to semispinalis<sup>34, 36, 42, 44</sup>, the muscle fascicles insert into the lamina and entire length of the spinous processes of lumbar, thoracic and cervical vertebrae two to four vertebrae above the vertebra of origin reaching superiorly to C2 in great apes and *Homo*<sup>28, 34, 36, 42, 44</sup>, extending to C1 in *Pan paniscus* alone<sup>28</sup>.

Innervated by dorsal rami of the spinal nerves in *Homo* and *Pan paniscus*<sup>28, 42</sup>.

### *Rotatores breves and longi*

No information for *Pongo* or *Hylobates*.

Rotatores originate in *Homo* and African apes from the transverse processes of the thoracic vertebrae<sup>34, 36, 42</sup>, extending as far superiorly as C2, and as far inferiorly as the sacrum in *Gorilla*<sup>34</sup>. Rotatores in the cervical and lumbar regions are variably present in *Homo*<sup>42</sup>.

Insertion of the short fibres in *Homo* and African apes is to the lamina and base of the spinous process of the vertebra above<sup>34, 36, 42</sup>, while *rotatores longi*, which insert onto the vertebra after that appear to be present only in *Homo* and *Gorilla*<sup>34, 42</sup>.

#### **3.5.1.2.2 Interspinales**

##### *Interspinales*

No information for *Pan*, *Pongo* or *Hylobates*.

In *Homo* and *Gorilla* interspinales originate from the spinous processes of the cervical and lumbar vertebrae<sup>34, 42</sup>.

The cervical part extends as far superiorly as C2 in *Homo*<sup>42</sup>, C3 in *Gorilla*<sup>34</sup>, and as far inferiorly as T3 in *Homo*<sup>42</sup> and T2 in *Gorilla*<sup>34</sup>. Additional thoracic interspinales are present in *Homo* between T11 and T12, and between T12 and L1<sup>42</sup>.

They insert onto the spinous processes of the adjacent vertebrae in *Homo* and *Gorilla*<sup>34, 42</sup>.

#### **3.5.1.2.3 Intertransversarii**

##### *Intertransversarii*

No information for *Hylobates*.

The intertransversarii in great apes have been described as similar to *Homo*<sup>34, 36, 37</sup>.

### **3.5.2 VESSELS**

#### **3.5.2.1 Arteries**

##### **3.5.2.1.1 Subclavian**

### *Suprascapular*

The suprascapular branch of the thyrocervical trunk is present in great apes and *Homo*<sup>34, 36, 37, 42</sup>.

In *Homo* and *Gorilla* it supplies the subclavius muscle<sup>34</sup>, while in *Pan* branches of the suprascapular and the descending branch of the transverse cervical arteries take the place of the superior thoracic branch of the axillary artery in *Homo*<sup>36</sup>.

In *Homo* and *Pongo* it gives off acromial branches<sup>37, 42</sup>.

### *Transverse cervical*

The transverse cervical artery is found in about one-third of *Homo*, giving rise to the superficial cervical and dorsal scapular arteries<sup>16, 42</sup>. The artery has also been found in specimens of *Pan* and *Pongo*<sup>36, 37</sup>.

### **3.5.2.1.2 Axillary**

#### *Subscapular*

The subscapular artery arises as an independent branch of the axillary artery in *Homo*<sup>42</sup>, 1/4 *Pan*<sup>36</sup>, *Gorilla*<sup>25</sup> and *Pongo*<sup>25, 29, 30</sup>. In 3/4 *Pan*<sup>13, 25, 29, 30</sup> and *Hylobates*<sup>25, 29, 30</sup> the artery arises from a common trunk with the circumflex humeral and circumflex scapular arteries, or with the circumflex humeral and profunda brachii, which may occur in *Homo* as a variant<sup>42</sup>.

There is a separate common trunk for the circumflex humeral and profunda brachii in *Pongo*<sup>25</sup>, and for the circumflex humeral and circumflex scapular arteries in *Homo*<sup>42</sup>, while in *Homo*<sup>42</sup> and 1/3 *Pongo*<sup>29, 30</sup> all three branches arise independently.

### 3.5.3 NERVES

*Dorsal scapular* See 3.4.3.3.1

*Subscapular* See 3.4.3.3.2.8

*Suprascapular* See 3.4.3.3.1

### BIBLIOGRAPHY

1. **Andrews,P** and **Groves,CP** (1976): Gibbons and brachiation. In:  
Rumbaugh,DM (ed); Gibbon and siamang. Vol.4. Karger, Basel' p167-218.
2. **Ashton,EH** and **Oxnard,CE** (1963): The musculature of the primate shoulder.  
Trans.Zool.Soc.Lond. 29, p553-550.
3. **Bardeen,CR** (1907): Cited in MacDowell (1910).
4. **Beddard,FE** (1893): Contributions to the anatomy of the anthropoid apes.  
Trans.Zool.Soc.Lond. 13, p177-218.
5. **Champneys,F** (1872): On the muscles and nerves of a chimpanzee (*Troglodytes niger*) and a *cynocephalus anubis*. J.Anat.Phys. 6, p176-211.
6. **Chapman,HC** (1878): On the structure of the gorilla. Proc.Zool.Soc.Lond. p385-394.
7. **Chapman,HC** (1879): On the structure of the chimpanzee. Proc.Zool.Soc.Lond. p52-63.
8. **Chapman,HC** (1880): On the structure of the orang outang. Proc.Zool.Soc.Lond. p160-174.
9. **Dean,MC** (1984): Comparative myology of the hominoid cranial base: The muscular relationships and bony attachments of the digastric muscle. Folia Primatol. 43, p234-248.
10. **Dwight,T** (1895): Notes on the dissection and brain of the chimpanzee "Gumbo". Mem.Boston Soc.Nat.Hist. 5, p31-51.

11. **Fick,R** (1895a): Vergleichend-anatomische Studien an einem erwachsenen Orang-utang. Arch.Anat.Physiol. Anat.Abt. p1-100.
12. **Fick,R** (1895b): Beobachtungen an einem zweiten erwachsenen Orang-Utang und einem Schimpanzen. Arch.Anat.Physiol. Anat.Abt. p289-318.
13. **Glidden,EM** and **De Garis,CF** (1936): Arteries of the chimpanzee. I. The aortic arch II. Arteries of the upper extremity III. The descending aorta IV. Arteries of the lower extremity. Am.J.Anat. 58 (2), p501-527.
14. **Gratiolet,LP** and **Alix,PHE** (1866): Recherches sur l'anatomie de *Troglodytes aubryi*, chimpanzé d'une espèce nouvelle. Nouv.Arch.Mus.Natl.Hist. Nat.(Paris). 2, p1-264.
15. **Hepburn,D** (1892): The comparative anatomy of the muscles and nerves of the superior and inferior extremities of the anthropoid apes. J.Anat.Phys. 26, p149-186, 324-356.
16. **Huelke,DF** (1962): The dorsal scapular artery - a proposed term for the artery to the rhomboid muscles. Anat.Rec. 142, p57-62.
17. **Humphry,GM** (1866/7): On some points in the anatomy of the chimpanzee. J.Anat.Phys. 1, p254-268.
18. **Inman,VT**, **Saunders,JB** de **CM** and **Abbott,LC** (1944): Observations on the function of the shoulder joint. J.Bone.Jt.Surg. 26, p1-30.
19. **Jungers,WL** and **Stern,JT Jr** (1981): Preliminary electromyographical analysis of brachiation in gibbon and spider monkey. Int.J.Primatol. 2 (1), p19-33.
20. **Larson,SG** and **Stern,JT Jr** (1986): EMG of scapulohumeral muscles in the chimpanzee during reaching and "arboreal" locomotion. Am.J.Anat. 176, p171-190.
21. **Larson,SG**, **Stern,JT** and **Jungers,WL** (1991): EMG of serratus anterior and trapezius in the chimpanzee: scapular rotators revisited. Am.J.Phys.Anthropol. 85, p71-84.

22. **Le Double, F** (1897): *Traité des variations du système musculaire de l'homme et de leur signification au point de vue de l'anthropologie zoologique, I et II.* Librairie C.Reinwald, Paris.
23. **MacAlister, A** (1871): On some points in the myology of the chimpanzee and of the primates. *Ann.Mag.Nat.Hist.* 7 (2), p341-351.
24. **MacDowell, EC** (1910): Notes on the myology of *Anthropopithecus niger* and *Papio-thoth ibeanus*. *Am.J.Anat.* 10, p431-460.
25. **Manners-Smith, T** (1910a): The limb arteries of primates (part 1). *J.Anat.Phys.* 44, p271-302.
26. **Michaëlis, P** (1903): Beiträge zur vergleichenden Myologie des *Cynocephalus babuin*, *Simia satyrus*, *Troglodytes niger*. *Arch.Anat.Phys. Anat. Abt.* p205-256.
27. **Miller, RA** (1932): Evolution of the pectoral girdle and forelimb in the primates. *Am.J.Phys.Anthropol.* 17, p1-56.
28. **Miller, RA** (1952): The musculature of *Pan paniscus*. *Am.J.Anat.* 91 (2), p182-232.
29. **Müller, E** (1903): Beiträge zur Morphologie des Gefasssystems. I. Die Armarterien des Menschen. *Anat.Hefte.* 22, p279-574.
30. **Müller, E** (1905): Beiträge zur Morphologie des Gefasssystems. II. Die Armarterien des Säugetiere. *Anat.Hefte.* 27, p73-241.
31. **Owen, R** (1830/1): On the anatomy of the orangutan (*Simia satyrus*, L.). *Proc.Zool.Soc.Lond.* 1, p4-5,9-10, 28-29, 66-72.
32. **Oxnard, CE** (1967): The functional morphology of the primate shoulder as revealed by comparative anatomical, osteometric and discriminant function techniques. *Am.J.Phys.Anthropol.* 26, p219-240.
33. **Primrose, A** (1900): The anatomy of the orang-outang. *Univ.of Toronto Studies. Anat.series* 1, p1-94.
34. **Raven, HC** (1950): Regional anatomy of the *Gorilla*. In: Gregory, WK (ed); *The anatomy of the Gorilla.* Columbia University Press, New York; p 15-188.

35. **Seydel, O** (1892): Cited in Sonntag (1924).
36. **Sonntag, CF** (1923): On the anatomy, physiology, and pathology of the chimpanzee. *Proc.Zool.Soc.Lond.* 23, p323-429.
37. **Sonntag, CF** (1924): On the anatomy, physiology, and pathology of the orang-utan. *Proc.Zool.Soc.Lond.* 24, p349-450.
38. **Sullivan, WE** and **Osgood, CW** (1927): The musculature of the superior extremity of the orang-utan, *Simia satyrus*. *Anat.Rec.* 35 (3), p193-239.
39. **Sutton, JB** (1883): On some points in the anatomy of the chimpanzee (*Anthropopithecus troglodytes*). *J.Anat.Phys.* 18, p66-85.
40. **Vrolik, W** (1841): Recherches d'anatomie comparée, sur le chimpansé. Johannes Miller, Amsterdam.
41. **Ward, CV** (1993): Torso morphology and locomotion in *Proconsul nyanzae*. *Am.J.Phys.Anthropol.* 92, p291-328.
42. **Warwick, P** and **Williams, PL** (1973): Gray's Anatomy. 35th British Edition. Saunders Co., Philadelphia.
43. **Wilder, B** (1862): Contributions to the comparative myology of the chimpanzee. *Boston J.Nat.Hist.* 6, p352-384.
44. **Winckler, G** (1947): Recherches sur le système musculaire du transverso-spinalis. *Arch.Anat.Histol.Embryol.* 30, p151-231.
45. **Ziegler, AC** (1964): Brachiating adaptations of chimpanzee upper limb musculature. *Am.J.Phys.Anthropol.* 22, p15-32.

## 3.6 ABDOMEN AND PELVIS

### 3.6.1 MUSCLES

#### 3.6.1.1 Anterior abdominal wall

##### 3.6.1.1.1 Longitudinal

###### *Rectus abdominis*

No information for *Pongo*.

In *Homo* and African apes rectus abdominis takes origin from the outer surface of the costal cartilages of the fifth to seventh ribs<sup>121, 136, 170</sup>, extending to the eighth and ninth costal cartilages in *Gorilla*<sup>136</sup>. The origin may involve more ribs in *Homo* as a variation<sup>170</sup>. In *Homo* and *Gorilla* it also originates from the xiphoid process of the sternum<sup>136, 170</sup>.

There are three tendinous intersections in *Homo*<sup>170</sup>, four in both species of *Pan*<sup>22, 121, 152</sup>, and five in *Gorilla*<sup>136</sup>. Of these, one or two are sometimes present below the umbilicus in *Homo*<sup>170</sup>, two are below the umbilicus in *Pan paniscus*<sup>121</sup>, and one may be in this position in *Gorilla*<sup>136</sup>.

The superficial *rectus sheath* is formed in *Pan*, *Gorilla* and *Hylobates* by the external and internal oblique, and the deep sheath by transversus abdominis alone<sup>22, 112, 121, 169</sup>, whilst in *Homo* the internal oblique splits into two laminae, the anterior of which forms the superficial sheath with the external oblique, and the posterior of which forms the deep sheath with transversus abdominis<sup>169, 170</sup>.



Rectus abdominis inserts in *Homo*, *Pan paniscus* and *Gorilla* into the region of the pubic crest<sup>121, 136, 170</sup>, and in *Homo* and *Gorilla* also into the symphyseal ligaments<sup>136, 170</sup>.

Innervated by the lower intercostal nerves in *Homo*, *Pan paniscus* and *Gorilla*<sup>121, 136, 170</sup>, and also by the first lumbar nerve in *Gorilla*<sup>136</sup>.

### *Pyramidalis*

No information for *Pongo* or *Hylobates*.

Pyramidalis is absent from *Pan*<sup>22, 152, 168</sup> and *Gorilla*<sup>136</sup>, and unilaterally absent from *Pan paniscus*<sup>121</sup>. In *Homo* the muscle may be absent or variably developed<sup>170</sup>.

On the left side in *Pan paniscus*, and in *Homo* when present, the muscle originates from the pubic crest between rectus abdominis and the rectus sheath, radiating into the linea alba<sup>121, 170</sup>.

Innervated by the twelfth thoracic nerve in *Homo* and *Pan paniscus*<sup>121, 170</sup>.

### *Tensor linea semilunaris*

No information for *Homo*, *Pan*, *Pongo* or *Hylobates*.

This muscle appears to be present only in *Gorilla*. A small, wide flat muscle distinct from rectus femoris, it originates near the pubic symphysis more superiorly than the insertion of rectus femoris<sup>136</sup>.

The fibres run anteriorly, parallel to the lateral border of rectus femoris, terminating in a small round tendon at the junction of the aponeurosis of transversus abdominis with the internal oblique, spreading out into the aponeurotic fibres of the internal oblique<sup>136</sup>.

### 3.6.1.1.2 Oblique

#### *Cremaster*

Cremaster takes origin in all apes and *Homo* with the exception of a single specimen of *Hylobates*<sup>118</sup>, from the internal abdominal oblique<sup>80, 112, 120, 121</sup>. In all apes and *Homo* it also contains a contribution from the transversus abdominis<sup>80, 112, 118, 120</sup>.

The muscle is attached to the inguinal ligament in *Homo* alone<sup>13, 170</sup>. It is a large heavy muscle in *Pan* and *Pongo*, but weaker in *Gorilla*<sup>120</sup>.

#### *External abdominal oblique*

In *Homo* and African apes the external abdominal oblique originates by fleshy slips from the external surface of the sixth to eleventh ribs<sup>22, 121, 136, 152, 170, 179</sup>. In *Homo*, *Pan paniscus* and *Gorilla* its origin extends inferiorly to the last rib<sup>121, 136, 170</sup>, which may be the twelfth or thirteenth rib, dependant on the number of thoracic vertebrae<sup>136</sup>. The cranial extent of the origin is to the fifth rib in *Homo*<sup>170</sup>, and variably so in all apes<sup>22, 136, 152, 179</sup> with the possible exception of *Pan paniscus*<sup>121</sup>. In hylobatids it may reach as far superiorly as the fourth rib<sup>179</sup>.

The upper part of the muscle interdigitates with slips of serratus anterior and the lower part with slips of latissimus dorsi in *Homo* and *Pan*<sup>22, 152, 170</sup>. In *Pan* it interdigitates medially with pectoralis major<sup>152</sup>. No further information for *Pongo*.

Insertion of the fibres from the last ribs in *Homo* and great apes is onto the iliac crest and its lateral lip, as far as the anterior superior iliac spine<sup>22, 103, 121, 152, 170, 171</sup>. From the anterior superior iliac spine to the pubic tubercle, the muscle has a free lower aponeurotic border in *Homo* and African apes<sup>103, 112, 121, 136, 152, 170</sup>, although it is not thickened in *Gorilla*<sup>136</sup>.

Innervation in *Homo* and *Pan paniscus* is via branches of the lower intercostal nerves<sup>121, 170</sup> and in *Pan paniscus* also from the iliohypogastric and ilioinguinal nerves<sup>121</sup>.

There is no true *inguinal ligament* in any ape, only a series of tendinous arches over sartorius and the femoral vessels and nerves, merging with the fascia lata<sup>61, 111, 120, 121</sup>.

A true inguinal ligament has been stated to be an exclusively human character<sup>111, 120, 143</sup>, although ligament-like connective tissue in a plane ventral to the pelvic girdle has been identified in all mammals<sup>111</sup>.

#### *Internal abdominal oblique*

The internal abdominal oblique originates in *Homo* and African apes from the anterior part of the iliac crest<sup>112, 121, 136, 152, 170</sup>, in *Homo*, *Pan paniscus* and *Gorilla* from the deep layer of the thoracolumbar fascia<sup>121, 136, 170</sup>, and in *Homo*, *Pan* and *Gorilla* from the aponeurosis of the external oblique, or *inguinal ligament*<sup>112, 120, 121, 136, 152, 170</sup>.

In all apes and *Homo* the internal abdominal oblique forms the conjoint tendon with transversus abdominis, described with the latter<sup>80, 112, 120, 136, 170</sup>. No further information for Asian apes.

The cranial part of the muscle inserts onto the inferior margins of the cartilage of the last three or four ribs in *Homo*<sup>170</sup>, and the last four ribs in African apes<sup>121, 136, 152</sup>. The middle fibres become aponeurotic medially, forming the anterior and posterior walls of the rectus sheath in *Homo*<sup>170</sup>, and the anterior wall alone in African apes<sup>22, 112, 121</sup>.

169

Innervation of the internal oblique is from branches of the lower intercostal nerves and the first lumbar nerve in *Homo*, *Pan paniscus* and *Gorilla*<sup>121, 136, 170</sup>.

#### *Transversus abdominis*

Transversus forms the posterior layer of the rectus sheath in all apes<sup>22, 112, 121, 169</sup>, while in *Homo* a lamella of the internal oblique supplements the transversus in this role<sup>170</sup>.

Heavy and muscular in *Gorilla*, the transversus abdominis is more weakly developed and thinner in other apes<sup>120</sup>.

The fibres of transversus abdominis decussate in the linea alba, and in all apes and *Homo* the aponeurotic part forms with the internal oblique, the conjoint tendon<sup>80, 112, 120, 136, 170</sup>, which in all apes and *Homo* inserts into the superior pubic surface in the region of the pubic crest<sup>112, 120, 121, 152, 170</sup>. The weak conjoint tendon of *Hylobates* may attach to the anterior wall of the rectus sheath above the pubis<sup>80, 120</sup>.

Innervation is via the lower intercostal nerves and first lumbar nerve in *Homo*, *Pan paniscus* and *Gorilla*<sup>121, 136, 170</sup>.

#### **3.6.1.1.3 Inguinal canal**

The length of the inguinal canal is 11.6 mm in *Symphalangus*, 11.0 mm in *Hylobates hoolock* and 11.3 mm in an adult *Hylobates concolor*<sup>80</sup>. In *Homo*, the inguinal canal is about 40 mm long<sup>170</sup>.

#### *Deep inguinal ring*

The deep inguinal ring is bounded by the inguinal ligament, the conjoint tendon and the transversalis fascia in *Homo*<sup>170</sup>. In *Pan* the deep ring is bounded by all the muscle

layers of the anterior abdominal wall<sup>120</sup>, in *Gorilla* and *Hylobates* by the internal oblique and transversus<sup>120</sup> while in *Pongo* the deep inguinal ring is bounded almost entirely by the internal oblique<sup>120</sup>. The deep inguinal ring is large in *Hylobates*<sup>80, 120</sup>.

#### *Superficial inguinal ring*

The superficial inguinal ring is bounded by the aponeurosis of the external oblique in all apes and *Homo*<sup>120, 121, 170</sup>, and its lateral third also by the muscular fibres of the internal oblique in *Homo*<sup>170</sup>.

The *lateral crus* of the aperture is stronger than the medial crus in *Homo*<sup>170</sup>, but weaker in Asian apes<sup>120</sup>. It is formed by fibres of the inguinal ligament inserted into the pubic tubercle in *Homo*<sup>170</sup>. The inguinal part of the aponeurosis of the external oblique attaches to most of the pubic ramus in both species of *Pan*<sup>120, 1952</sup>, and with a reduced attachment to the pubis in *Hylobates*<sup>120</sup>.

The *medial crus* attaches to the anterior aspect of the pubic symphysis in *Homo* and *Pan*<sup>120, 170</sup>, and to the pubic crest in all apes<sup>120, 121</sup>. Intercrural bands in the fascia of the external oblique may arch above the apex of the ring in all apes and *Homo*<sup>120, 121, 170</sup>.

### **3.6.1.2 Posterior abdominal wall**

#### *Iliacus*<sup>a</sup>

In all apes and *Homo* iliacus originates from the iliac fossa<sup>72, 170</sup>. In all apes it originates from the entire anterior surface of the ilium<sup>149</sup>, and in *Homo* alone from the region of the anterior inferior iliac spine<sup>149, 170</sup>. In *Gorilla* there may be an additional origin from the lumbodorsal fascia<sup>136</sup>. As a variation in *Homo* the origin may be from the capsule of the hip joint and the sacrum<sup>170</sup>.

In all apes and *Homo* it inserts in combination with psoas major onto the medial aspect of the lesser trochanter<sup>8, 22, 136, 149, 170</sup>.

Iliacus is supplied by the femoral nerve in all apes and *Homo*<sup>136, 149, 170</sup>. In *Gorilla* the iliac branch of the iliolumbar nerve is stated to ramify on the surface of iliacus as in *Homo*<sup>136</sup>.

#### *Psoas major*<sup>a</sup>

In all apes and *Homo* psoas major originates from the lateral surfaces of the bodies and the costal processes of the lumbar vertebrae<sup>17, 22, 72, 136, 149, 170</sup>, extending proximally to T12 in *Homo*, *Gorilla*, *Pongo* and *Hylobates*<sup>72, 136, 149, 170</sup> and in some *Pan*<sup>22, 149</sup>, extending distally to S1 in Asian apes<sup>72, 149</sup> some *Gorilla*<sup>149</sup> and most *Pan*<sup>72, 149</sup>. In all apes and *Homo* it takes origin from the intervening intervertebral discs<sup>72, 149, 170</sup>. An origin from the head of the twelfth rib may be present in *Pan*<sup>22</sup>. Psoas major in *Hylobates* has an additional origin from the lateral side of the tendon of origin of rectus femoris<sup>72, 101</sup>.

As a variation in *Homo*, psoas major may be divided into longitudinal slips<sup>27, 96</sup>.

In all apes and *Homo* psoas major joins with iliacus, and inserts as iliopsoas onto the lesser trochanter and distally on the adjacent shaft<sup>8, 17, 22, 72, 136, 149, 170</sup>.

Nerve supply is via the first two or three lumbar nerves and the femoral nerve in all apes and *Homo*<sup>22, 72, 136, 149, 152, 153, 170</sup>.

#### *Psoas minor*<sup>a</sup>

In all apes and *Homo* with the exception of a single *Gorilla*<sup>136</sup>, the muscle originates from the anterolateral surface of L1<sup>22, 72, 101, 136, 149, 162</sup>. An origin from the last

thoracic vertebra is present in *Homo*, *Gorilla* and *Pongo*<sup>22, 72, 149, 162</sup> and in half of all *Pan*<sup>22, 72, 149, 162</sup> and *Hylobates*<sup>149</sup>. An origin from L2 may be present in all apes<sup>72, 136, 149, 170</sup>.  
<sup>101</sup>In a single specimen of *Gorilla*, the origin extends further superiorly to T11<sup>136</sup> and in a single *Hylobates*, it extends further inferiorly to L3<sup>101</sup>. Psoas minor is stated to take origin from the intervertebral discs in all apes and *Homo*<sup>149, 162, 170</sup>.

In all apes and *Homo* it lies on the anteromedial surface of psoas major<sup>149, 170</sup>. Psoas minor is absent from about 40% of human subjects<sup>170</sup>, and is fused with psoas major in two-thirds of *Hylobates*<sup>149</sup>.

In all apes and *Homo* psoas minor inserts onto the iliopubic eminence and pectineal line<sup>22, 72, 136, 149, 162, 170</sup>. This insertion is more anterior in *Pan* than in *Gorilla* or *Pongo*<sup>72</sup>.

Innervation is via the first lumbar nerve in all apes and *Homo*<sup>22, 149, 170</sup>. Psoas minor may also be innervated by the twelfth thoracic nerve in African apes<sup>72, 149</sup>, but in Asian apes that nerve also contributes a supply<sup>149</sup>.

#### *Quadratus lumborum*

No information for *Pongo* or *Hylobates*.

In *Homo*, *Pan paniscus* and *Gorilla* quadratus lumborum originates from the medial lip of the iliac crest and the iliolumbar ligament<sup>121, 136, 170</sup>.

The anterior fibres are continuous with iliacus in *Pan paniscus* and *Gorilla*<sup>121, 136</sup>, and with psoas major in *Gorilla*<sup>136</sup>.

The insertion of the muscle is to the last rib in these two apes and *Homo*<sup>121, 136, 170</sup>, extending to the penultimate rib in *Pan paniscus*<sup>121</sup> and to the body of the last rib-

bearing vertebrae in *Gorilla*<sup>136</sup>. The second part of the insertion is to the transverse processes of L1 and L2 in both these apes and *Homo*<sup>121, 136, 170</sup>, extending to L3 or L4 in *Homo* and *Pan paniscus*<sup>121, 170</sup>. The insertion is also onto the bodies of L1 and L2 in *Gorilla*<sup>136</sup>.

Innervation of the muscle is from the ventral rami of the first to third or fourth lumbar nerves in *Homo*<sup>170</sup>, of all the lumbar nerves in *P.paniscus*<sup>121</sup> and of the first and second lumbar nerves in *Gorilla*<sup>136</sup>. *Homo* and *Gorilla* also show an innervation from the last thoracic nerve<sup>136, 170</sup>.

### 3.6.1.3 Pelvis

#### 3.6.1.3.1 Pelvic diaphragm

##### *Coccygeus*

*Coccygeus* takes origin in *Homo*, *Gorilla* and *Hylobates* from the ischial spine<sup>48, 136, 170</sup>, the origin extends to the dorsal surface of the ilium in *Gorilla*<sup>48, 136</sup>.

Mostly tendinous with few muscle fibres<sup>48, 121, 136, 151</sup>, it is most extensively developed among apes in *Hylobates*<sup>48</sup>. The caudal border is continuous with pubococcygeus in both species of *Pan*<sup>48, 121</sup>, and it interdigitates with the sacrospinous ligament in all apes and *Homo*<sup>48, 121, 136, 170</sup>. In *Pongo* the muscle is mostly replaced by the strong sacrospinous ligament<sup>48</sup>, and coccygeus may be absent as a variant in *Homo*<sup>170</sup>.

Insertion in all apes and *Homo* is to the side of the coccyx<sup>48, 121, 170</sup>, in *Homo* and *Gorilla* to the inferior part of the sacrum<sup>48, 170</sup> and in *Gorilla* and *Hylobates* to the anococcygeal raphe<sup>48</sup>. In *Pan* coccygeus is fused at insertion with the coccygeal part of the origin of gluteus maximus<sup>22</sup>.



Innervated by the third sacral nerve in *Pan* and *Gorilla*<sup>22, 136</sup> and by the fourth and fifth sacral nerves in *Homo* and *Pan paniscus*<sup>121, 170</sup>.

### *Flexor caudae*

There is no trace of flexor caudae in *Pan* or *Hylobates*<sup>48</sup>, but remnants have been reported in *Gorilla*<sup>48, 136</sup> and *Pongo*<sup>45, 109</sup>.

In a specimen of *Gorilla*, a small irregular cord runs from the anococcygeal raphe just inferior to the last coccygeal vertebrae to insert into the rectal wall<sup>136</sup>.

### *Iliococcygeus*

The muscle is absent from *Hylobates*, being replaced by fascia<sup>48</sup>, and may be absent or thin in *Homo* and great apes<sup>48, 151, 170</sup>.

Iliococcygeus is aponeurotic at origin in great apes<sup>35, 165</sup>, which in *Homo*, *Gorilla* and *Pongo* is from the obturator fascia<sup>35, 48, 136, 165</sup>, extending in *Homo* and *Pongo* as far as the ischial spine<sup>165, 170</sup>.

Iliococcygeus belongs to the vertebral column muscle group, which includes the flexor caudae<sup>151</sup>, and is homologous with the most superior fibres of levator ani<sup>35, 136, 165</sup>. In *Pongo* the muscle is continuous with the sacrosciatic ligaments and piriformis<sup>165</sup>.

Insertion in *Homo* and great apes is onto the coccyx<sup>35, 48, 136, 165, 170</sup> and in *Gorilla* also onto the sacrum<sup>48</sup>.

Innervated by the fourth sacral nerve and the inferior rectal nerve in *Homo*<sup>170</sup>, and by the first to third sacral nerves in *Gorilla*<sup>136</sup>.

*Levator ani*

No information for *Hylobates*.

Levator ani is formed by two plates from each side of the inner wall of the lesser pelvis in *Homo* and great apes, originating from the obturator fascia from the pubic symphysis to the ischial ramus<sup>121, 152, 165, 170</sup>.

The fibres encircle the rectum and insert into the anococcygeal raphe behind the anus, inserting in addition into the tip of the coccyx in *Homo* and great apes<sup>35, 121, 136, 152, 170</sup>.

Innervated by branches of the inferior rectal nerve in *Homo*, from the second and third sacral nerves in *Gorilla*<sup>136</sup>, the fourth sacral nerve in *Homo* and *Pan paniscus*<sup>121, 170</sup>, and also from the first sacral nerve in *Gorilla*<sup>136</sup> and the fifth sacral nerve in *Pan paniscus*<sup>121</sup>.

*Ligamentum puboprostaticum* (*puboampullaris, pubovesicalis, rectovesicalis*)

No information for *Pan, Pongo* or *Hylobates*.

This consists of smooth muscle, originating from the pubis medial to the origin of pubococcygeus in *Homo* and *Gorilla*<sup>35, 136, 170</sup>.

The puboampullaris lies on the superficial surface of pubococcygeus but is separated from it by a thin fascial plane in *Gorilla*<sup>35</sup>. The two muscle masses appear to provide support for the urogenital structures as well as elevating and pulling the rectum forward in *Gorilla*<sup>35</sup>.

The muscles of the two sides unite, and insert into the smooth muscle of the rectal wall, and the inferolateral aspect of the bladder in *Homo* and *Gorilla*<sup>35, 136, 170</sup>.

### *Pubococcygeus*

In *Homo* and great apes pubococcygeus originates from the posterior surface of the pubic body<sup>35, 48, 136, 165, 170</sup>, extending in *Pan* and *Pongo* to the ischial spine<sup>48, 151</sup>. The muscle also takes origin in *Homo* and great apes from the obturator fascia<sup>48, 136, 165, 170</sup>.

In all apes and *Homo* the pubococcygeus muscles of the two sides unite at the midline<sup>48, 151, 165, 170</sup>, and in *Homo* and *Gorilla* the muscle mingles with posterior fibres of the deep part of the external anal sphincter<sup>35, 136, 170</sup>.

The muscle inserts in all apes and *Homo* onto the rectal wall<sup>35, 48, 136, 165</sup> (variably in *Pan*<sup>48</sup>). This part may be described as the *puborectalis* in *Homo*<sup>170</sup>. Pubococcygeus also inserts onto the tip of the coccyx in all apes and *Homo*<sup>48, 136, 151, 170</sup> (variably so in *Gorilla*<sup>35</sup>), in *Homo*, *Pan* and *Hylobates* into the anococcygeal raphe<sup>48, 170</sup>, and in *Pan* onto the sacrum<sup>151</sup>.

Innervated by the fourth sacral nerve and a branch from the inferior rectal nerve in *Homo*<sup>170</sup> first to third sacral nerves in *Gorilla*<sup>136</sup>.

### *Puborectalis*

No information for *Hylobates*.

In *Homo* puborectalis takes origin with the rest of levator ani from the pubic bone near the symphysis<sup>170</sup>, while in *Gorilla* the muscle originates aponeurotically from connective tissue in the region of the symphyseal angle<sup>35</sup>.

In great apes puborectalis is homologous with the inferior fibres of pubococcygeus<sup>35, 48, 136, 165</sup>. In *Homo* and *Gorilla*, a puborectal sling is formed, encircling the upper part of the anal canal<sup>35</sup>.

In *Homo*, puborectalis blends with the longitudinal coat of the rectum, descending as a longitudinal coat for the anal canal, deep to the external anal sphincter<sup>170</sup>. In *Gorilla* fibres intermingle with the deep external anal sphincter<sup>35</sup>.

### 3.6.1.3.2 Perineum

#### 3.6.1.3.2.1 Anal region

##### *External anal sphincter*

The sphincter encircles the anus in all apes and *Homo*<sup>35, 48, 121, 136, 170</sup>, extending from the anococcygeal raphe in *Homo* and African apes<sup>121, 136, 152, 170</sup> to the perineal body in *Homo* and great apes<sup>48, 121, 136, 170</sup>.

The sphincter ani in *Gorilla*, as in *Pongo* and to a less marked degree in *Pan*, forms a muscular basin for the support of both alimentary and urogenital viscera<sup>48</sup>.

Some deeper fibres blend with the inferior margin of levator ani in *Homo* and African apes<sup>35, 48, 136, 152</sup>, while other fibres radiate into the raphe of bulbospongiosus in *Homo*, *Gorilla* and Asian apes<sup>35, 48, 136</sup>. In *Homo*, dorsal and ventrolateral tetherings of the external anal sphincter may be adaptations to erect posture<sup>178</sup>.

Fibres radiate to the tip of the coccyx in *Homo*<sup>170</sup>, but do not reach the coccyx in *Gorilla*<sup>35, 48, 136</sup>.

Innervated by branches of the second and third sacral nerves in *Homo* and *Gorilla*<sup>136, 170</sup>, by the fourth sacral nerve in *Homo* and *Pan paniscus*<sup>121, 170</sup>, also by the first sacral nerve in *Gorilla*<sup>136</sup> and by the fifth sacral nerve in *Pan paniscus*<sup>121</sup>.

### 3.6.1.3.2.2 Urogenital region

#### *Bulbospongiosus (bulbocavernosus)*

In all apes and *Homo* bulbospongiosus originates from the median raphe of the penile bulb<sup>35, 48, 136</sup>, and in addition in *Homo*, *Pongo* and 1/3 *Gorilla* from the perineal body<sup>48, 136</sup>. African apes and *Hylobates* share an origin from the ischium<sup>35, 48</sup>, which is more extensive in *Hylobates* than in African apes<sup>48</sup>.

The muscle surrounds the bulb and the corpora of the penis in all apes and *Homo*<sup>35, 48, 136</sup>, and fibres of the external anal sphincter merge with the superior fibres in *Homo*, *Gorilla* and Asian apes<sup>35, 48, 136</sup>.

The muscle in *Homo* and *Gorilla* extends into a dorsal fibrous expansion on the penis<sup>48, 136</sup>, while in *Gorilla* and *Pongo*, it is described as inserting onto the inferior surface of the penis<sup>35, 39, 136</sup>.

#### *Ischiocavernosus*

No information for *Pongo* or *Hylobates*.

A paired muscle<sup>136</sup>, in *Homo* and *Gorilla* the ischiocavernosus take origin from the ischial ramus anterior to the ischial tuberosity<sup>35, 136, 170</sup>, and from the ascending pubic ramus in *Pan*<sup>152</sup>.

In *Gorilla* the muscle is slightly shorter and thicker than in *Homo*<sup>136</sup>.

The muscle spreads from the origin, over the penile crus, to insert in *Homo* and *Gorilla* onto the proximal end of the corpora cavernosum<sup>35, 136, 170</sup>.

#### *Sphincter urethrae*

No information for *Pongo* or *Hylobates*.

In an adult male *Gorilla* the sphincter urethrae is a true sphincter<sup>35</sup>, with no invasion of the prostate, similar to that found in prepubescent *Homo*<sup>35</sup>. In adult male *Homo* the continued growth of the prostate causes a major loss of muscle fibres<sup>35</sup>.

In female *Homo* and *Pan*, fibres of the sphincter urethrae also interlace in the vaginal wall<sup>139, 170</sup>.

#### *Transversus perinei profundus*

No information for *Pongo* or *Hylobates*.

In *Homo* and *Gorilla* this muscle originates from the fascia just above the ischial ramus<sup>35, 170</sup>.

In *Pan*, some fibres of the bulbospongiosus which lie in contact with the pelvic diaphragm and insert into the ischia, may be homologous with the deep transverse perineal muscle<sup>48</sup>. In *Gorilla* the transversus perinei profundus is continuous with the sphincter urethrae<sup>35</sup>, while in *Homo* the voluntary sphincter has separated from the deep transverse perineal muscle<sup>170</sup>.

In *Homo* the muscles interlace and insert onto the perineal body<sup>170</sup>, while in *Gorilla* the fibres interdigitate at the midline with the external anal sphincter, the bulbospongiosus and the smooth muscle of the rectal wall<sup>35</sup>. This point may be analogous to a perineal body<sup>35</sup>.

### *Transversus perinei superficialis*

No information for *Pongo* or *Hylobates*.

In *Homo*, and when present in *Gorilla*, the muscle originates from the ischial tuberosities<sup>136, 170</sup>.

The muscle is absent from *Pan*<sup>152</sup>, and may be absent from *Homo* as a variation<sup>170</sup>.

When absent from *Gorilla*, a few fibres of the superficial external anal sphincter radiate towards the ischial tuberosities, but do not reach them<sup>35</sup>.

In *Homo* the muscle inserts into the perineal body with the external anal sphincter and bulbospongiosus<sup>170</sup>, while in *Gorilla* although part of the muscle inserts into the bulbospongiosus muscle, the majority of fibres insert into the external anal sphincter<sup>136</sup>.

## **3.6.2 VESSELS**

### **3.6.2.1 Arteries**

#### **3.6.2.1.1 Abdominal aorta<sup>b</sup>**

The abdominal aorta begins at the aortic hiatus of the diaphragm(see 3.2.1.3).

In all apes and *Homo* it terminates by dividing into the two common iliac arteries.

This occurs at the level of L4 in *Homo* and all apes<sup>92, 99, 152, 153</sup> with the exception of 1/2 *Pongo*, in which the abdominal aorta branches at the level of L3<sup>92</sup>.

Dimensions of the abdominal aorta in *Gorilla* have been provided by Kleinschmidt<sup>96</sup> and Steiner<sup>156</sup>.

### 3.6.2.1.1.1 Ventral

#### 3.6.2.1.1.1.1 Coeliac

##### *Coeliac trunk*

No information for *Pongo* or *Hylobates*.

The coeliac trunk divides into left gastric, hepatic and splenic branches in *Homo* and *Pan*<sup>152, 170</sup>.

Unnamed branches of the coeliac trunk supply the liver, gall-bladder, stomach, superior half of the duodenum, greater omentum, pancreas and spleen in *Gorilla*<sup>83</sup>.

##### *Left gastric*

No information for *Pongo* or *Hylobates*.

In *Homo* and *Pan* the left gastric artery runs along the lesser curvature of the stomach<sup>152</sup>.

In *Homo* and *Pan* the artery gives off gastric arteries to both surfaces of the stomach, and oesophageal arteries which ascend through the oesophageal opening in the diaphragm<sup>152, 170</sup>. The left gastric artery in *Homo* and *Pan* anastomoses with the right gastric artery<sup>152, 170</sup>.

The left gastric artery gives off a branch to the liver in *Gorilla*<sup>83</sup>.

##### *Hepatic*

The *right gastric artery* anastomoses with the left gastric artery in *Homo* and *Pan*<sup>152</sup>.

170



In *Homo* and *Pan* the *right gastro-omental* artery anastomoses with the left gastro-omental artery<sup>152, 170</sup>.

The *cystic artery* is a branch of the hepatic artery in *Homo* and *Pan*<sup>152, 170</sup>. The cystic arterial supply of the gall-bladder has a bi-pinnate pattern in *Homo* and *Hylobates*, and a pinnate pattern in *Gorilla* and *Symphalangus*<sup>62</sup>. In *Gorilla* and hylobatids the cystic artery reaches the gall-bladder by running immediately beside the cystic duct, closely bound to it by firm areolar tissue, while in *Homo* the cystic artery is never in contact with any part of the cystic duct<sup>62</sup>.

### *Splenic*

No information for *Hylobates*.

The splenic artery is shorter in *Pongo* than in *Homo*<sup>150</sup>.

*Pancreatic* branches of the splenic artery are present in *Homo* and *Pan*<sup>152, 170</sup>.

*Short gastric* branches of the splenic artery are present in *Homo*, *Pan* and *Gorilla*<sup>83, 152, 170</sup>, although they appear to have a longer course in *Gorilla* than in *Homo*<sup>83</sup>.

The *left gastro-omental* artery anastomoses in *Homo* and *Pan* with the right gastro-omental artery<sup>152, 170</sup>.

### **3.6.2.1.1.1.2 Superior mesenteric**

#### *Superior mesenteric*

No information for *Pongo* or *Hylobates*.

The superior mesenteric artery supplies the whole of the small intestine, except the superior half of the duodenum and half of the colon, in *Homo* and African apes<sup>83, 152,</sup>

170

The *middle colic* artery is a branch of the superior mesenteric artery in *Homo* and *Gorilla*<sup>136, 170</sup>.

### 3.6.2.1.1.3 Inferior mesenteric

#### *Inferior mesenteric*

No information for *Pongo* and *Hylobates*.

The origin of the inferior mesenteric artery is more superior in *Gorilla* than in *Homo* and *Pan*<sup>61, 152</sup>, being from midway along the anterior aspect of the abdominal aorta<sup>99</sup>.

The inferior mesenteric artery supplies the inferior half of the colon in *Homo* and African apes<sup>83, 152, 170</sup>, although the inferior mesenteric artery supplies the whole of the transverse colon in *Gorilla*<sup>83</sup>, compared with the left part of the transverse colon in *Homo*<sup>170</sup> and *Pan*<sup>152</sup>.

The *left colic* branch anastomoses with the middle colic artery in *Homo* and *Pan*<sup>152, 170</sup>.

The *superior rectal* artery is relatively larger in *Pan* than in *Homo*<sup>152</sup>.

### 3.6.2.1.1.2 Lateral

#### 3.6.2.1.1.2.1 Inferior phrenic

No information for *Gorilla* or *Hylobates*.

The inferior phrenic arteries arise from the abdominal aorta in *Homo* and *Pan*<sup>61, 152, 170</sup>, but from the coeliac axis in *Pongo*<sup>153</sup> and as a variation in *Homo*<sup>170</sup>.

In *Pan* the right and left inferior phrenic arteries arise from a common trunk<sup>61, 152</sup>, as may also occur in *Homo*<sup>170</sup>.

In *Homo* and African apes the phrenic arteries supply the inferior surface of the diaphragm and the suprarenal glands<sup>61, 99, 152, 170</sup>, and may also supply the liver and spleen in *Homo*<sup>170</sup>.

#### 3.6.2.1.1.2.1 Middle suprarenal

No information for *Hylobates*.

Suprarenal arteries arising from the aorta are absent from *Pongo*<sup>153</sup> and from 1/2 *Pan*<sup>152</sup>.

In *Homo* and 1/2 *Pan* there are two middle suprarenal arteries arising directly from the aorta<sup>61, 170</sup>, while in *Gorilla* there are three middle suprarenal arteries, two on the right and one on the left<sup>99</sup>.

#### 3.6.2.1.1.2.2 Renal

No information for *Pongo* or *Hylobates*.

Right and left renal arteries are present in *Homo* and African apes<sup>61, 99, 136, 152, 170</sup>.

The renal arteries supply *inferior suprarenal* branches in *Homo* and African apes<sup>61, 99, 152, 170</sup>.

Interlobular arteries branch in the outer third of the cortex in *Pan*<sup>157</sup>, either forming Y-shaped bifurcations as in *Homo*<sup>110</sup> or multiple branches as in *Macaca*<sup>157</sup>.

#### 3.6.2.1.1.2.3 Gonadal

##### *Ovarian*

No information for *Gorilla*, *Pongo* or *Hylobates*.

The ovarian arteries are long and slender in *Homo* and *Pan*<sup>61, 170</sup>.

In 1/2 *Pan* the left ovarian artery arises from the left renal artery, but the right ovarian artery is a branch of the abdominal aorta<sup>152</sup>, as in *Homo*<sup>170</sup>.

### *Testicular*

No information for *Gorilla* or *Pongo*.

In *Homo*, the testicular artery passes along the spermatic cord with little or no convolution<sup>69, 68</sup>. In *Pan*<sup>68</sup> the testicular arteries are convoluted both along the spermatic cord and along the posterior and anterior borders of the testis. In *Hylobates* the testicular artery is less convoluted on the spermatic cord and posterior border of the testis than in *Pan*, subsequently running straight or slightly convoluted on the anterior surface of the testis<sup>68</sup>.

Each testicular artery divides into two branches supplying the medial and lateral surfaces of the testis in *Homo*, *Pan* and *Hylobates*<sup>68</sup>.

### **3.6.2.1.1.3 Dorsal**

#### **3.6.2.1.1.3.1 Lumbar**

No information for *Pongo* or *Hylobates*.

Four pairs of lumbar arteries arise from the abdominal aorta in *Homo*, 1/2 *Pan*<sup>152</sup> and *Gorilla*<sup>99</sup>. In 1/2 *Pan*, only two pairs of lumbar arteries are present<sup>61</sup>.

#### **3.6.2.1.1.3.2 Median sacral**

No information for *Gorilla* or *Hylobates*.

In *Homo* and *Pan* the median sacral artery arises from the posterior surface of the aorta, slightly above its bifurcation<sup>61, 170</sup>.

The median sacral artery is absent from *Pongo*<sup>153</sup>.

### 3.6.2.1.2 Internal iliac

#### *Internal iliac*

No information for *Hylobates*.

The internal iliac artery in *Homo* and *Pan* divides into anterior and posterior trunks<sup>61, 152, 170</sup>.

#### 3.6.2.1.2.1 Anterior trunk

In *Homo* and *Pan* the anterior trunk of the internal iliac terminates in the medial umbilical ligament, passing superiorly on the deep surface of the anterior abdominal wall<sup>61, 170</sup>.

#### *Obturator*

No information for *Hylobates*.

In *Homo* and unilaterally in 1/2 *Pan*, the obturator artery is a branch of the internal iliac artery<sup>54, 170</sup>.

The obturator artery is a branch of the inferior epigastric branch of the external iliac artery unilaterally in 1/2 *Pan*<sup>54</sup> and in *Gorilla* and *Pongo*<sup>47, 132, 136</sup>. This is also the case in 20 to 30% of *Homo*<sup>170</sup>.

The obturator artery is absent from 1/2 *Pan*, with its area of distribution taken over by the medial femoral circumflex artery<sup>61</sup>.

#### *Inferior gluteal*

No information for *Hylobates*.

In *Homo* and 1/2 *Pan*, the inferior gluteal artery is a branch of the internal iliac artery<sup>61, 170</sup>.

In 1/2 *Pan* and *Gorilla*, the inferior gluteal artery is a branch of the internal pudendal artery<sup>47, 152</sup>. The inferior gluteal and internal pudendal arteries may be a common stem from the internal iliac in *Homo*<sup>170</sup>.

The inferior gluteal artery is absent from *Pongo*<sup>132</sup>.

The uterine, middle rectal and internal pudendal arteries are given off as branches of the inferior gluteal artery in 1/2 *Pan*<sup>61</sup>. Branches of this artery may replace the middle rectal artery in *Homo*<sup>170</sup>.

Vesical branches of the inferior gluteal artery are present in *Homo* and *Pan*<sup>61, 170</sup>. The artery also supplies gluteus maximus, the gemelli, obturator internus, and the hip joint in *Homo* and *Pan*<sup>152, 170</sup>.

#### *Vesical*

No information for *Hylobates*.

Two vesicular arteries, superior and inferior, are given off from the internal iliac artery in *Homo* and *Pongo*<sup>132, 170</sup>, while only the superior vesicular artery is given off by the internal iliac artery in *Pan* and *Gorilla*<sup>47, 61, 152</sup>.

In *Pan*, the inferior vesical artery is a branch either of the inferior gluteal<sup>61</sup> or internal pudendal<sup>152</sup> arteries, while in *Gorilla* it is given off from the internal iliac artery with the uterine artery<sup>47</sup>. The inferior vesical artery may arise from the internal iliac with the middle rectal artery in *Homo*<sup>170</sup>.

### *Uterine*

No information for *Hylobates*.

The internal iliac gives off the uterine artery in *Homo* and great apes<sup>47, 61, 132, 152, 170</sup>.

The uterine artery may be a branch of the inferior gluteal artery<sup>61</sup>, or given off from the internal iliac with the vaginal artery as a uteri-vaginal trunk in *Pan*<sup>152</sup>.

### *Middle rectal*

No information for *Gorilla*, *Pongo* or *Hylobates*.

The middle rectal arteries arise from the internal iliac artery in *Homo*<sup>170</sup>, but from the inferior gluteal artery in *Pan*<sup>61</sup>.

### *Internal pudental*

No information for *Hylobates*.

The internal iliac artery gives off the internal pudental artery in *Homo* and great apes<sup>47, 61, 132, 152, 170</sup>.

The internal pudental artery in *Gorilla* is given off with the middle rectal artery and the inferior gluteal artery<sup>47</sup>. The inferior gluteal and internal pudental arteries may be a common stem from the internal iliac in *Homo*<sup>170</sup>.

The internal pudental artery in *Pan* gives off the inferior vesical artery<sup>152</sup>.

In 1/2 *Pan* and *Gorilla*, the inferior gluteal artery is a branch of the internal pudental artery<sup>47, 152</sup>.

### 3.6.2.1.2.2 Posterior trunk

#### *Iliolumbar*

No information for *Hylobates*.

The iliolumbar artery originates from the internal iliac artery in *Homo* and *Pongo*<sup>132</sup>,<sup>170</sup>, from the superior gluteal artery in *Pan*<sup>61</sup>, and from the distal end of the aorta in *Gorilla*<sup>47</sup>.

As variations, the iliolumbar artery may arise from the common iliac artery, but not from the aorta or the medial sacral artery in *Homo*<sup>132</sup>.

#### *Lateral sacral*

No information for *Gorilla*, *Pongo* or *Hylobates*.

The lateral sacral artery is given off by the internal iliac artery in *Homo* and 1/2 *Pan*<sup>152, 170</sup>, but from the superior gluteal artery in 1/2 *Pan*<sup>61</sup>.

#### *Superior gluteal*

No information for *Hylobates*.

The internal iliac artery gives off the superior gluteal artery in *Homo* and great apes<sup>47</sup>,<sup>61, 132, 152, 170</sup>.

In *Homo* and *Pan* the superior gluteal artery divides into two branches<sup>152</sup>. In *Homo* the superficial branch supplies gluteus maximus and the skin posterior to the sacrum, while the deep branch supplies gluteus medius and minimus and the hip joint<sup>170</sup>. In *Pan* the superior branch supplies gluteus medius and the nutrient artery to the ilium, while the inferior one descends to supply gluteus medius, gluteus minimus and the scansorius muscle<sup>152</sup>.



The superior gluteal artery gives off the iliolumbar and lateral sacral arteries in 1/2 *Pan*<sup>61</sup>.

### 3.6.2.1.3 External iliac<sup>b</sup>

#### *Inferior epigastric*

No information for *Hylobates*.

The obturator artery is a branch of the inferior epigastric branch of the external iliac artery unilaterally in 1/2 *Pan*<sup>54</sup>, and in *Gorilla* and *Pongo*<sup>47, 132, 136</sup>. This is also the case in 20 to 30% of *Homo*<sup>170</sup>.

The superficial circumflex iliac artery is a branch of the inferior epigastric artery in *Pongo*<sup>132</sup>, while in *Homo* it is a branch of the femoral artery<sup>170</sup>.

A pubic branch is present in *Homo* and *Gorilla*<sup>136, 170</sup>.

The medial circumflex femoral artery is a branch of the external iliac artery with the inferior epigastric artery in 2/3 *Pan*<sup>54, 61</sup>, while in *Homo* it is a branch of the profunda femoris or the femoral artery<sup>170</sup>.

#### *Deep circumflex iliac*

No information for *Pongo* or *Hylobates*.

The deep circumflex iliac artery is a branch of the lateral aspect of the external iliac artery in *Homo* and African apes<sup>61, 136, 170</sup>.

### 3.6.2.2 Veins

3.6.2.2.1 Inferior vena cava See 3.3.2.3.4

3.6.2.2.2 Portal system

### *Portal vein*

No information for *Pongo* or *Hylobates*.

The hepatic portal system collects blood from the abdominal alimentary tract, spleen and pancreas in *Homo* and African apes<sup>83, 122, 152, 170</sup>.

It is formed by the confluence of the gastric, splenic, duodenal, inferior mesenteric, superior mesenteric<sup>122</sup> and cystic veins from the transverse colon in *Homo* and *Pan*, in both of which the portal vein divides into two branches before entering the liver<sup>152, 170</sup>.

### **3.6.2.3 Lymphatics**

#### *Common iliac nodes*

No information for *Gorilla*, *Pongo* or *Hylobates*.

Present in *Homo* and *Pan*<sup>152, 170</sup>.

#### *External iliac nodes*

No information for *Pan*, *Pongo* or *Hylobates*.

These nodes drain the bladder and spermatic cord in *Homo* and *Gorilla*<sup>136, 170</sup>.

#### *Gastric nodes*

No information for *Gorilla*, *Pongo* or *Hylobates*.

Present in *Homo* and *Pan* along the lesser and great curvatures of the stomach<sup>152, 170</sup>.

#### *Inguinal nodes*

No information for *Gorilla*, *Pongo* or *Hylobates*.

Superficial inguinal nodes are found close to the midpoint of the inguinal ligament in *Homo* and *Pan*<sup>152, 170</sup>.

#### *Mesenteric nodes*

No information for *Gorilla*, *Pongo* or *Hylobates*.

Present in *Homo* and *Pan*<sup>152, 170</sup>.

#### *Thoracic duct*

The thoracic duct begins at the cisterna chyli in *Homo*, *Pan* and *Pongo*<sup>89, 152, 170</sup>. The cisterna chyli is 5 to 7 cm long in *Homo*, but nearly 18 cm long in *Pongo*<sup>89</sup>.

Two vessels arise from the cisterna chyli in *Pan*, which later unite at a variable level to form a single thoracic duct<sup>89, 95, 114, 152</sup>. This point of junction may be at the level of T6<sup>152</sup> or T12<sup>95</sup>.

### **3.6.3 NERVES**

**3.6.3.1 Vagus See 3.2.3.1**

**3.6.3.2 Lumbar<sup>b</sup>**

#### *Iliohypogastric*

No information for *Pongo* or *Hylobates*.

The iliohypogastric nerve arises from the first lumbar nerve in *Homo* and *Gorilla*<sup>136, 170</sup>, and is described as arising from the thirteenth thoracic nerve in *Pan*<sup>15, 22, 152</sup>.

It communicates with the genitofemoral nerve in *Gorilla*<sup>136</sup>, and with the subcostal and ilioinguinal nerves in *Homo*<sup>170</sup>.

### *Ilioinguinal*

No information for *Pongo*.

The ilioinguinal nerve arises from the first lumbar nerve in *Homo*, 2/4 *Pan*, *Gorilla* and *Hylobates*<sup>72, 152, 170</sup>. In 1/4 *Pan* the origin is solely from the thirteenth thoracic nerve<sup>22</sup> while in 1/4 *Pan* the ilioinguinal nerve is jointly formed by the first lumbar and thirteenth thoracic nerves<sup>15</sup>.

### *Genitofemoral*

The genitofemoral nerve has spinal components from the first lumbar nerve in all taxa<sup>12, 39, 88, 102, 103, 116</sup> except *Hylobates*<sup>39</sup>, and from the second lumbar nerve only in *Homo*, *Gorilla* and *Hylobates*<sup>39, 116</sup>.

The nerve pierces psoas major in all taxa<sup>12, 39, 88, 102, 103, 116</sup> except 1/2 *Pan*<sup>12</sup> and 1/2 *Gorilla*, where it passes lateral to psoas major<sup>88</sup>.

### **3.6.3.3 Sacral nerves**

#### *Pudendal*

No information for *Pongo* or *Hylobates*.

In *Homo* and *Pan* the pudendal nerve arises from the second sacral nerve<sup>15, 152, 170</sup>, and also from the third and fourth sacral nerves in *Homo*<sup>170</sup>.

Branches of the pudendal nerve supply the rectum, external anal sphincter, levator ani and ischiocavernosus in *Homo* and *Pan*<sup>152, 170</sup>. No branches to the transverse perineal muscles are present in *Pan*, as the muscles are absent<sup>152</sup>.

It supplies the bulbospongiosus in *Homo* and *Gorilla*<sup>136, 170</sup>.

### 3.6.3.4 Autonomic

#### *Sympathetic trunk*

The pelvic part of the sympathetic trunk consists of four or five sacral ganglia connected by sections of the trunk in *Homo* and African apes<sup>47, 152, 170</sup>, and four ganglia in Asian apes<sup>134</sup>.

The two pelvic sympathetic trunks unite inferiorly in front of the coccyx as the *ganglion impar* in *Homo*, *Pan* and *Pongo*<sup>134, 170</sup>. The ganglion impar lay on Co1 in *Pan* and Asian apes<sup>134</sup>.

On the right side in *Pan*, there may be an elongated ganglion formed by the fusion of the last lumbar and first sacral ganglia, and more inferiorly a smaller ganglion formed by the fusion of the second and third sacral ganglia<sup>134</sup>.

Species	Sacral vertebrae	Number of ganglia	
		Right	Left
<i>Pan troglodytes</i>	6	4	5
<i>Pan troglodytes</i>	6	5	5
<i>Pan troglodytes</i>	6	4	5
<i>Pongo</i>	5	4	4
<i>Symphalangus</i>	5	4	4
<i>Symphalangus</i>	5	4	4
<i>Symphalangus</i>	5	3	4

Table 3.6.1. Number of sacral vertebrae and sacral sympathetic ganglia in *Pan*, *Pongo* and *Symphalangus*<sup>134</sup>.

### 3.6.4 ALIMENTARY SYSTEM

#### 3.6.4.1 Intestine<sup>b</sup>

##### 3.6.4.1.1 Oesophagus See 3.3.4.1

### 3.6.4.1.2 Stomach

In *Homo* and *Pongo* the stomach lies obliquely<sup>28, 170</sup>, while in *Pan* the long axis of the stomach is more horizontal than in *Homo*<sup>28, 152</sup>. It lies mostly to the left of the midline in *Gorilla*<sup>156</sup>, and entirely to the left of the midline in *Pongo*<sup>25</sup>.

In *Gorilla* the cardiac and pyloric orifices are closer together than in *Homo*<sup>49, 83</sup>.

In *Pongo*, the cardiac portion of the heart is elongated<sup>25</sup> and constricted from the pyloric part as in *Homo* and African apes<sup>49, 152, 170</sup>, the latter of which is thicker and narrower than the cardiac part<sup>25, 125</sup>.

Sex	BW (kg)	Length	Breadth	Height	Weight
Male	130	285	150	250	720 g (0.55)
Female	68	260	150	200	700 g (1.029)

Table 3.6.2. Dimensions (mm) and weight (g) of the stomach in male and female *Gorilla*.

Adapted from<sup>83</sup>. Numbers in parentheses are stomach weight in percentage of body weight (BW).

Species	Water-filled	Surface area	Greater curvature
<i>Pan troglodytes</i>	-	1079	965
	-	135	72
<i>Gorilla</i>	-	116	88
<i>Symphalangus</i>	240	156	264
	350	385	296
<i>Hylobates pileatus</i>	580	499	-

Table 3.6.3. Estimation of stomach volume (cm<sup>3</sup>), considering the stomach as a sphere in African apes and hylobatids, and also estimation of stomach volume by filling the organ with water without stretching the wall in hylobatids. Adapted from<sup>26</sup>.

Species	Sex	BW	Surface area	Weight	Volume
<i>Pan troglodytes</i>	F	-	472	-	965
	M	34000	690	-	1705
<i>Gorilla</i>	M	51000	1087	-	3370
<i>Pongo</i>	M	8620	256	71	385
	M	-	880	331	2457
<i>Hylobates lar</i>	M	5000	204	58	274
	F	5400	104	53	100
<i>Hylobates pileatus</i>	F	7260	304	56	499
<i>Symphalangus</i>	F	11340	457	146	919
	M	7250	140	55	156

**Table 3.6.4. Measurements of body weight (BW, in g), and of surface area (cm<sup>3</sup>), weight (g) and volume (cm<sup>3</sup>) of the stomach. Adapted from <sup>26</sup>.**

### 3.6.4.1.3 Small intestine

#### *Plica circulares (valvulae conniventes)*

No information for *Hylobates*.

The plica circulares are variably developed in *Homo* and the great apes<sup>49, 74, 152, 170</sup>.

#### *Small intestine*

The small intestine, including the duodenum, has an average length of around 590 cm in female *Homo*, and around 635 cm in male *Homo*<sup>166</sup>. The length of the small intestine was found to be correlated with height in *Homo*<sup>166</sup>. The length of the jejunum and ileum together has been noted as 350 cm in *Pan*<sup>152</sup> and 945 cm and 1021 cm in two adult *Gorilla*<sup>49, 156</sup> males.

In *Homo* and *Pan* the villi of the small intestine contain a single central vein draining a subepithelial capillary plexus converging at the apex of the villus. These villi also

contain a single eccentrically located artery rising to the midlevel of the villus, where it branches into subepithelial capillaries over the rest of its length<sup>161</sup>.

Species	Sex	BW	Surface area	Weight	Volume
<i>Pan troglodytes</i>	F	-	1700	-	815
	M	34000	3761	-	1967
<i>Gorilla</i>	M	51000	4018	-	1897
<i>Pongo</i>	M	8620	1263	124	461
	M	-	6564	568	4046
<i>Hylobates lar</i>	M	5000	453	81	154
	F	5400	268	35	68
<i>Hylobates pileatus</i>	F	7260	592	77	596
<i>Symphalangus</i>	F	11340	2278	150	1007
	M	7250	1708	183	697

Table 3.6.5. Measurements of body weight (BW, in g), and of surface area (cm<sup>3</sup>), weight (g) and volume (cm<sup>3</sup>) of the small intestine in great apes and hylobatids. Adapted from<sup>26</sup>.

#### 3.6.4.1.3.1 Duodenum

##### *Duodenum*

No information for *Hylobates*.

The duodenum can be divided in *Homo* and African apes into superior, descending, horizontal and ascending portions, ending at the duodenojejunal junction<sup>49, 152, 170</sup>.

The superior portion is more freely movable than the other sections, and the descending portion is partly covered by the colon in *Homo* and *Gorilla*<sup>49, 170</sup>.

Mitchell found no distinct duodenum in *Gorilla* or *Pongo*<sup>122</sup>.

##### *Duodenal glands*

No information for *Gorilla*, *Pongo* or *Hylobates*.

Duodenal glands are present in *Homo* and *Pan*<sup>104</sup>.



*Duodenal papilla* See 3.6.4.2.3

### 3.6.4.1.3.2 Ileum

#### *Aggregated lymphatic follicles (Peyers patches)*

No information for *Hylobates*.

These patches have been found in *Homo* and great apes<sup>23, 24, 25, 152, 170</sup>.

#### *Solitary lymphatic follicles*

No information for *Hylobates*.

These scattered follicles have been reported as present in *Homo* and great apes<sup>25, 125,</sup>

126, 156, 170

### 3.6.4.1.4 Large intestine

No information for *Hylobates*.

The large intestine is about 150 cm long in *Homo*<sup>170</sup>, in *Pan* 76 cm<sup>24</sup> to 122 cm<sup>152</sup> long, in adult male *Gorilla* the large intestine was 168 cm<sup>156</sup> or 193 cm<sup>83</sup> long, 175 cm long in an adult female *Gorilla*<sup>83</sup> and in *Pongo* 122 cm<sup>25</sup> long.

Haustrations are present in *Homo* and great apes<sup>2, 12, 25, 44, 49, 52, 83, 125, 152, 170</sup>, and

appendices epiploicae are present in *Homo*<sup>170</sup> and *Pan*<sup>152</sup>.

Division of the large intestine into ascending, transverse, descending and sigmoid parts as in *Homo*<sup>170</sup>, is not generally found in great apes.

In *Gorilla* the colon may be differentiated into a proximal portion continuous with the caecum and a very large loop incorporating three rather irregular wide loops, the

most distal of which may be regarded as the equivalent of the sigmoid colon, as in *Pongo*<sup>122</sup>.

The ascending and descending colon are relatively shorter, and the transverse portion more elongated in *Gorilla* than in *Homo* and *Pan*<sup>74</sup>.

The *ascending colon* is kinked medially in juvenile *Pan*<sup>74</sup>, but is straight in *Homo*, adult *Pan* and *Pongo*<sup>74, 170</sup>. It measures 15-18 cm<sup>83</sup> in diameter, or 30 cm<sup>156</sup> in circumference in adult *Gorilla*, compared to 14 cm<sup>156</sup> in *Homo*. A true ascending colon may be absent from *Gorilla*<sup>74</sup>.

The *transverse colon* is very coiled in great apes<sup>74</sup>. It measures 10-14 cm in diameter in an adult male *Gorilla*<sup>83</sup>.

The *descending colon* is coiled in great apes<sup>74, 160</sup>. It measures 8-13 cm in diameter in an adult male *Gorilla*<sup>83</sup>. No true descending colon is found in *Pan*, as a recurrent limb is present<sup>74</sup>.

The *sigmoid colon* is a large loop in *Homo* and great apes<sup>74, 137, 170</sup>, but may be composed of a number of small loops in *Pongo*<sup>122</sup>. It measures 4-5 cm in diameter in an adult male *Gorilla*<sup>83</sup>. The sigmoid colon may be replaced by a small curve in the descending colon in *Gorilla*<sup>156</sup>.

Species	Sex	BW	Surface area	Weight	Volume
<i>Pan troglodytes</i>	F	-	1812	-	1451
	M	34000	2925	-	4335
<i>Gorilla</i>	M	51000	4813	-	7006
<i>Pongo</i>	M	8620	978	157	1071
	M	-	5774	980	7800
<i>Hylobates lar</i>	M	5000	383	74	259
	F	5400	403	68	267
<i>Hylobates pileatus</i>	F	7260	1128	144	920
<i>Symphalangus</i>	F	11340	1557	230	1891
	M	7250	954	184	883

Table 3.6.6. Measurements of body weight (BW, in g), and surface area (cm<sup>3</sup>), weight (g) and volume (cm<sup>3</sup>) of the colon in great apes and hylobatids. Adapted from <sup>26</sup>.

#### *Mesocolon*

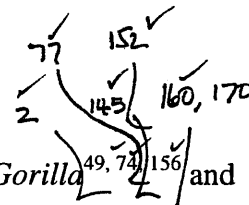
No information for *Hylobates*.

The transverse and sigmoid colons possess a mesentery in *Homo* and *Gorilla*<sup>49, 74, 159, 170</sup>. Ascending and descending mesocolons may be present in *Homo* as a variation<sup>170</sup>.

In *Pan*, there may be no mesentery for the ascending and sigmoid colons or for the majority of the descending colon, the iliac part of the descending colon being the only part with a mesentery<sup>152</sup>. A transverse mesocolon may be present in *Pan*<sup>24</sup>. The sigmoid mesocolon in *Gorilla* may extend proximally onto the iliac part of the descending colon<sup>74</sup>.

In juvenile *Pongo*, the ascending, transverse, descending and sigmoid colons may have a mesentery<sup>74</sup>, while in adult *Pongo* the recurrent part of the descending colon and the sigmoid colon have a mesocolon, the ascending and descending mesocolons being absent<sup>74</sup>.

## Taeniae coli



Three taeniae coli are present in *Homo*<sup>170</sup>, 3/4 *Pan*<sup>74, 145, 160</sup>, *Gorilla*<sup>49, 74, 156</sup> and *Pongo*<sup>2, 74, 145</sup>, while two are present in 1/4 *Pan*<sup>152</sup> and four in *Hylobates*<sup>77</sup>.

### 3.6.4.1.4.1 Caecum and appendix

#### Caecum

Species	Sex	BW	Surface area	Weight	Volume
<i>Pan troglodytes</i>	F	-	162	-	91
	M	34000	286	-	407
<i>Gorilla</i>	M	51000	590	-	955
<i>Pongo</i>	M	8620	70	17	56
	M	-	155	22	55
<i>Hylobates lar</i>	M	5000	15	4	3
	F	5400	6	2	2
<i>Hylobates pileatus</i>	F	7260	77	17	34
<i>Symphalangus</i>	F	11340	75	10	34
	M	7250	81	22	58

Table 3.6.7. Measurements of body weight (BW, in g), and of surface area (cm<sup>2</sup>), weight (g) and volume (cm<sup>3</sup>) of the caecum in great apes and hylobatids. Adapted from <sup>26</sup>.

#### Iliocaecal valve

No information for *Gorilla* or *Hylobates*.

An iliocaecal valve is present in *Homo*, *Pan* and *Pongo*<sup>25, 44, 152, 170</sup>.

#### Vermiform appendix

The vermiform appendix is present in all apes and *Homo*<sup>10, 23, 24, 25, 44, 49, 64, 77, 83, 122, 125, 145, 152</sup>.

The appendix varies from 2 to 20 cm in length, with an average of about 9 cm<sup>170</sup> in *Homo*. In *Pan*, the appendix is reported as 11.5 to 16.5 cm long<sup>24, 152</sup>. It has been

described as 7 cm to 25.5 cm long in *Gorilla*<sup>14, 23, 49, 52, 83, 115, 156</sup>, and 17 cm long in *Pongo*<sup>25</sup>.

Appendicitis as a cause of death has been described in all apes<sup>51, 66, 76, 100, 117, 173, 174, 175</sup>.

### 3.6.4.1.5 Rectum

Unlike *Homo*<sup>170</sup>, the rectum and anal canal form a straight canal with no flexures in *Pan*<sup>152</sup>.

Species	Length	Diameter
<i>Homo</i> <sup>170</sup>	120	40
<i>Pan</i> <sup>152, (a)</sup>	140	-
<i>Gorilla</i> (male) <sup>83</sup>	350	50
<i>Gorilla</i> (female) <sup>83</sup>	150	-

**Table 3.6.8. Dimensions (mm) of the rectum in *Homo* and African apes.** <sup>(a)</sup> includes anal canal.

#### *Rectococcygeus(caudoanalis)*

No information for *Pan*, *Pongo* or *Hylobates*.

The rectococcygeus is present in 1/2 *Gorilla*, and vestiges may be present in *Homo*<sup>48</sup>.

In *Homo*<sup>170</sup>, two fasciculi of striated muscle arise from the anterior surface of Co2 and Co3, while in *Gorilla*<sup>48, 136</sup> the paired muscles originate from the last coccygeal vertebra and the fascia caudal to it, running obliquely across the inner surface of pubococcygeus<sup>136</sup>.

A thin muscle, it tapers to insert into the sheath of the rectum deep to the external anal sphincter in *Gorilla*<sup>48, 136</sup>, blending with the longitudinal muscle fibres of the posterior wall of the anal canal in *Homo*<sup>170</sup>.

Innervated in *Gorilla*<sup>136</sup> by a branch of the nerve to pubococcygeus.

### *Rectourethralis*

No information for *Pan*, *Pongo* or *Hylobates*.

Rectourethralis consists of smooth muscle which in *Homo* and *Gorilla* originates from the inferior part of each side of the rectal wall<sup>35, 170</sup>, at the rectal ampulla in *Homo*<sup>170</sup> and in *Gorilla*<sup>35</sup>, 8 to 10 cm above the anal verge.

In *Homo*<sup>170</sup> the fibres of the rectourethralis insert into the perineal body, while in *Gorilla* they insert into the sphincter urethrae and dorsal urethra, extending proximally to the superior border of the bulb of the corpus spongiosum<sup>35</sup>.

#### **3.6.4.1.6 Anal canal**

No information for *Pongo* or *Hylobates*.

Anal columns are present in *Homo* and African apes<sup>49, 152, 170</sup>. Anal valves are present in *Homo*<sup>170</sup> but are absent from *Pan*<sup>152</sup>, while anal sinuses are present in *Homo* and *Gorilla*<sup>49, 170</sup>.

#### **3.6.4.2 Glands**

##### **3.6.4.2.1 Liver**

No information for *Hylobates*.

The number of lobes is four in *Homo*<sup>170</sup>, while in *Gorilla* the number of lobes has been stated to vary from 3 to 7<sup>21, 49, 83, 91, 100, 136, 156</sup>.

##### *Caudate lobe*

The caudate lobe and caudate process are present in *Homo* and the African apes<sup>21, 24,</sup>

49, 83, 152

The caudate lobe is absent from *Pongo*<sup>25</sup> and has been described as “not developed” in *Gorilla*<sup>156</sup>.

#### *Left lobe*

In *Gorilla*, the left lobe is subdivided by a deep fissure into left central and left lateral lobules, the lateral being larger than the central lobule<sup>21, 29</sup>. The dividing fissure is continuous with the fissure for the ligamentum teres<sup>21</sup>.

#### *Quadrate lobe*

The quadrate lobe was present, but not well demarcated in *Pan* and *Gorilla*<sup>21, 24, 156</sup>.

In *Gorilla* the lobe was roughly triangular<sup>21</sup>, rather than rectangular than in *Homo*<sup>170</sup>.

A shallow transverse fissure subdivides the quadrate lobe into two lobules in *Gorilla*<sup>21</sup>.

#### *Right lobe*

The right lobe is slightly larger than the left in *Pan* and *Gorilla*<sup>21, 49, 152</sup>, unlike *Homo* where the right lobe constitutes five-sixths of the liver<sup>170</sup>.

In *Gorilla* the right lobe is subdivided into a right central and a right lateral lobule, the central being larger than the lateral<sup>21, 49</sup>.

Species	BW (kg)	Length	Breadth	Weight
<i>Pan</i> <sup>128</sup>	19.3	-	-	907 (4.70)
<i>Pan paniscus</i> <sup>9</sup>	4.6	-	-	171 (3.72)
<i>Pan paniscus</i> <sup>9</sup>	4.5	-	-	230 (5.11)
<i>Pan paniscus</i> <sup>9</sup>	-	-	-	775
<i>Pan paniscus</i> <sup>9</sup>	40	-	-	750 (1.88)
<i>Gorilla</i> <sup>83</sup>	130	37	15	2020 (1.55)
<i>Gorilla</i> <sup>83</sup>	68	31	18	2110 (3.10)
<i>Gorilla</i> <sup>156</sup>	227	-	-	2200 (0.97)
<i>Gorilla</i> <sup>21</sup>	134	30.5	26.7	3900 (2.91)
<i>Gorilla</i> <sup>1</sup>	-	-	-	1818

**Table 3.6.9. Dimensions (cm) and weights (gm) of the liver in African apes. Numbers in parentheses are liver weight in percentage of body weight(BW).**

#### 3.6.4.2.2 Gall bladder

##### *Cystic duct*

No information for *Pan*, *Pongo* or *Hylobates*.

The cystic duct is 2.5 cm long in *Gorilla*<sup>156</sup> and 3 to 4 cm long in *Homo*<sup>170</sup>.

##### *Gall bladder*

No information for *Pongo* or *Hylobates*.

The gall bladder is present on the inferior surface of the right central lobe in *Homo* and *Gorilla*<sup>21, 49, 83, 156, 170</sup>. It may be embedded in the substance of the liver in *Pan*<sup>152</sup>.

The gall bladder does not project below the inferior margin of the liver in *Gorilla*<sup>21</sup>, unlike *Homo* and *Pan*<sup>152, 170</sup>.

The valves at the gall bladder neck are few and simple in *Gorilla*<sup>156</sup>.



	BW (kg)	Length	Breadth
Male <sup>83</sup>	130	9	3.5
Female <sup>83</sup>	68	12	6
Male <sup>156</sup>	227	17.5	4.5
<sup>21</sup>	134	15.2	5.1

Table 3.6.10. Dimensions of the gall bladder (cm) in *Gorilla*.

### 3.6.4.2.3 Pancreas

#### *Pancreas*

No information for *Pongo*.

The pancreas is dark in colour in African apes<sup>156, 152</sup>, while in *Homo*<sup>170</sup> the pancreas is described as greyish-pink.

In *Homo*, *Pan* and *Symphalangus* the greatest vertical dimension of the head of the pancreas is usually half of the greatest length of the whole pancreas<sup>106</sup>. The head of the pancreas lies within the curve of the duodenum in *Homo*, *Pan*, *Gorilla* and *Symphalangus*<sup>49, 106, 170</sup>. The head of the pancreas is often described as smaller in proportion to the body of the pancreas in *Gorilla* than in *Homo*<sup>49, 83, 156</sup>.

In *Homo*, *Pan* and *Symphalangus*, the end of the pancreatic tail is directed superiorly<sup>106, 170</sup>. The tail is contact with the spleen in *Homo* and *Gorilla*<sup>49, 170</sup>.

An additional pancreatic process runs up along the portal vein for a short distance<sup>152</sup>.

	BW (kg)	Total length	Breadth of body	Length of head	Breadth of head	Weight
Male <sup>83</sup>	130	20	2	11	3.5	75 (0.057)
Female <sup>83</sup>	68	17	3	6.5	-	47 (0.069)
Male <sup>156</sup>	227	31.5	1.8	-	6.5	105 (0.046)

Table 3.6.11. Length (cm) and weight (g) of the pancreas in *Gorilla*. Numbers in parentheses are pancreas weights in percentage of body weight (BW).

### *Pancreatic duct*

In *Pan*, there is an accessory duct and an inferior duct of the pancreatic head, both of which join the main pancreatic duct before it enters the duodenal wall<sup>106</sup>. The accessory duct is present, but the inferior duct of the head is absent from *Symphalangus*<sup>106</sup>. The accessory duct in *Symphalangus* opens into the main duct<sup>106</sup>, while in *Homo* it usually opens onto a minor duodenal papilla above the main papilla<sup>170</sup>, and may do so in *Pan* and *Symphalangus*<sup>106</sup>.

In *Homo*, 3/5 *Pan*, 1/2 *Gorilla* and *Symphalangus* the bile duct and the pancreatic duct have a common orifice<sup>49, 106, 152, 170</sup>, although in these African apes there may be no definite papilla<sup>49, 106, 152, 170</sup>. The papilla is better defined in *Pan* than in *Gorilla*<sup>106</sup>.

The hepatic and pancreatic ducts enter the duodenum separately but close together in 2/5 *Pan*<sup>106, 160</sup> 1/2 *Gorilla*<sup>49</sup> and in *Pongo*<sup>25, 125, 159</sup>.

In *Homo* there are delicate reinforcing fibres from the duodenal musculature to the sphincter of the hepatopancreatic ampulla<sup>97</sup>, which have also been found in fetal *Pan*<sup>105</sup>.

#### **3.6.4.2.4 Spleen**

No information for *Hylobates*.

The spleen is more pointed at its extremities in *Pongo* than in *Homo*<sup>125</sup>, and is more elongated in *Gorilla* than in *Homo*<sup>49, 83</sup>.

A small, oval, accessory spleen connected to the transverse colon has been found in *Pan*<sup>152</sup>, while no accessory spleens have been found in *Pongo*<sup>153</sup>.

Species	BW (kg)	Length	Width	Breadth	Weight
<i>Homo</i> <sup>170</sup>	-	12	7	3-4	80-300
<i>Pan</i> <sup>126</sup>	-	12.7	10.2	-	-
<i>Pan</i> <sup>128</sup>	19.3	-	-	-	71 (0.37)
<i>Pan</i> <sup>152</sup>	-	9.7	7.0	3.1	-
<i>Pan paniscus</i> <sup>9</sup>	4.6	-	-	-	12 (0.26)
<i>Pan paniscus</i> <sup>9</sup>	4.5	-	-	-	17 (0.38)
<i>Pan paniscus</i> <sup>9</sup>	-	-	-	-	62
<i>Pan paniscus</i> <sup>9</sup>	40	-	-	-	100 (0.25)
<i>Gorilla</i> <sup>83</sup>	130	16	8.5	-	250 (0.19)
<i>Gorilla</i> <sup>83</sup>	68	12.5	7.0	-	120 (0.18)
<i>Gorilla</i> <sup>156</sup>	227	18.8	9.7	3.8	372 (0.16)
<i>Gorilla</i> <sup>49</sup>	-	33	7	-	-
<i>Gorilla</i> <sup>97</sup>	-	18	7	3	-
<i>Gorilla</i> <sup>115</sup>	-	-	-	-	680
<i>Pongo</i> <sup>153</sup>	-	10.9	3.8	0.8	-

Table 3.6.12. Dimensions (mm) and weight (g) of the spleen in *Homo* and great apes. Numbers in parentheses are pancreas weights in percentage of body weight (BW).

### 3.6.5 UROGENITAL SYSTEM

#### 3.6.5.1 Urinary system<sup>b</sup>

##### 3.6.5.1.1 Kidney

In *Homo*, *Pan*, 2/4 *Gorilla* and *Symphalangus*, the left kidney lies higher than the right<sup>54, 83, 106, 152, 170</sup>. In 1/4 *Gorilla*, the left kidney is lower than the right<sup>49</sup>, and in 1/4 *Gorilla* the kidneys are nearly on the same level<sup>83</sup>.

On both sides the ilium lies behind the inferior portion of the kidney in *Gorilla*, unlike *Homo*<sup>49, 170</sup>.

In *Homo*, the number of papillae present has been noted as between 3 and 20<sup>82</sup>, 5 to 11<sup>107</sup> or 6 to 14<sup>4</sup>.

A single papilla is usually present in apes<sup>12, 25, 38, 41, 42, 46, 49, 60, 85, 118, 125, 158, 163, 183</sup>, although up to six papillae have been reported in *Pan*<sup>24, 152, 154, 155, 167, 176</sup> and *Gorilla*<sup>58, 154, 176, 183</sup>. Two papillae or four fused papillae have been described in *Pongo*<sup>118, 153, 18</sup>, while in *Hylobates*<sup>154, 176, 183</sup> as many as four papillae have been noted. In *Pongo*<sup>118</sup> the single papilla may have a subdividing groove, or no papilla may be present<sup>57, 153</sup>.

The boundary between the medulla and cortex is frequently scalloped, the pyramid thus being divided into secondary pyramids<sup>49, 156</sup>. Three to five secondary pyramids have been noted in *Pan* and *Pongo*<sup>158</sup>, while a female *Gorilla*<sup>49</sup> showed five subpyramids on the right side, but no subdivision on the left. Three to six secondary pyramids have been described in *Hylobates*<sup>38, 158</sup>.

The renal columns are well demarcated in *Pan* and *Pongo*<sup>25, 60, 85, 118, 154, 167, 172, 176, 183</sup>.

In *Gorilla*<sup>156</sup> the cortex averaged 16 mm and the medulla 28 mm in thickness.

Values for renal plasma flow in *Pan* are similar to those for *Homo*<sup>56, 67</sup>.

The fetal kidneys of *Homo* and *Gorilla* are externally lobulated<sup>37, 170</sup>.

## *Urethra*

No information for *Pongo*.

The diameter of the urethra is 6 mm in *Homo*<sup>170</sup> and has been noted as 7.5 mm in *Gorilla*<sup>35</sup>.

The length of the urethra from the base of the bladder to the beginning of the corpus spongiosum is around 43 mm in *Homo*<sup>170</sup> and 45 mm in *Gorilla*<sup>35</sup>.

A navicular fossa is formed in the glans penis in *Homo*, African apes and hylobatids<sup>80, 87, 136, 139, 170</sup>.

The urethra runs through the prostate in *Homo* and *Hylobates*<sup>70, 80, 170</sup>. The proximal part of the urethra may penetrate the prostate in *Gorilla*<sup>83</sup>. The prostate does not encircle the urethra in African apes, the anterior surface being free of prostatic tissue<sup>35, 84, 139</sup>. The urethra may be entirely anteprostatic in *Pan*<sup>152</sup>, *Pongo*<sup>133</sup> and *Symphalangus*<sup>118</sup>.

The ducts of the bulbourethral glands enter the spongiöse urethra in *Homo* and *Gorilla*<sup>35, 170</sup> while a seminal colliculus is present in the proximal urethra of *Homo*, *Gorilla* and hylobatids<sup>80, 136, 170</sup>.

The mucosa is arranged in longitudinal folds in *Homo* and African apes<sup>35, 136, 139, 170</sup>.

Species	Age	Prostatic	Membranous	Penile
<i>H.agilis</i> <sup>68</sup>	Adult	7.0-8.0	12.0	-
<i>H.concolor</i> <sup>80</sup>	Adult	10.0	5.5	32.2
<i>H.hoolock</i> <sup>80</sup>	Juvenile	9.5	3.5	18.5
<i>H.hoolock</i> <sup>80</sup>	Subadult	9.0	4.5	18.5
<i>H.leuciscus</i> <sup>68</sup>	Immature	2.0	8.0	-
<i>Symphalangus</i> <sup>80</sup>	Subadult	13.5	5.5	32.5
<i>Symphalangus</i> <sup>80</sup>	Juvenile	10.0	4.0	19.0
<i>Symphalangus</i> <sup>80</sup>	Immature	10.0	5.5	24.0

Table 3.6.15. Dimensions (mm) of the urethra in hylobatids.

### 3.6.5.1.4.2 Female

#### *Urethra*

No information for *Gorilla*, *Pongo* or *Hylobates*.

The epithelium of the urethra in *Homo* and *Pan* is transitional near the bladder, stratified or pseudostratified in the mid-urethra, becoming stratified squamous epithelium distally<sup>139, 170</sup>.

Longitudinal and circular muscle layers are present in addition to spongiose tissue in *Homo* and *Pan*<sup>139, 170</sup>.

#### *Urethral opening*

The urethral opening in *Homo* and *Hylobates* is an anteroposterior slit<sup>70, 170</sup>, while in *Gorilla* the urethra opens in the vestibule by a transverse slit<sup>180</sup>. The slit has prominent margins in *Homo*<sup>170</sup> and is guarded by a small mucosal fold in *Gorilla*<sup>180</sup>.

It is situated anterior to the vaginal opening in *Homo* and African apes<sup>75, 136, 170</sup>, but may be present on the vaginal wall in *Pan*<sup>152</sup>.

The opening may be located on a papilla or eminence in *Gorilla* and *Hylobates*<sup>6, 32, 33, 118</sup>.  
This papilla is absent from *Homo*, *Pan* and *Pongo*<sup>6, 75, 180, 70, 116, 180</sup>.

### *Paraurethral glands*

No information for *Pongo* or *Hylobates*.

These glands are present in *Homo* and African apes<sup>6, 139, 170</sup>.

Paraurethral ducts are present in *Homo* and *Gorilla*<sup>6, 170</sup>.

## **3.6.5.2 Genital system<sup>b</sup>**

### **3.6.5.2.1 Male**

#### **3.6.5.2.1.1 Testis and epididymis**

##### *Tunica vaginalis*

The tunica vaginalis is a closed sac in all apes and *Homo*<sup>25, 80, 126, 136, 170</sup>.

Communication with the peritoneal cavity may be present in *Homo*<sup>170</sup>, and has been noted in a specimen of *Hylobates hoolock*<sup>80</sup>.

##### *Testis*

Hill and Harrison-Matthews found no asymmetry in the position of the testes in *Gorilla*<sup>78</sup>, while Hartmann and McKenney *et al.* record the left testis lower than the right<sup>71, 115</sup> and Wislocki found the right testis to be lower than the left<sup>176</sup>.

The testes of *Gorilla* often appear atrophied, with little or no spermatogenesis<sup>3, 53, 65, 100, 115, 135, 156</sup>. Unilateral cryptorchidism has been noted in 3/62 wild *Hylobates* (12 juvenile, 50 adult)<sup>144</sup>.

Species	Glandular	Connective	Total
<i>Homo</i>	2.54	1.98	4.52
<i>Pan</i>	3.17	1.33	4.50
<i>Hylobates</i>	2.30	2.19	4.49

**Table 3.6.16. Weights (g) of glandular tissue and connective tissue in the testis in *Homo*, *Pan* and *Hylobates*. Adapted from <sup>144</sup>.**

Primates with relatively large testes appear to have a considerably greater proportion of sex-cell producing glandular tissue and a smaller proportion of connective tissue than those with comparatively small testes<sup>144</sup>.

Dahl *et al.* provide testicle volumes relative to body weight in *Homo* and *Pongo*<sup>34</sup>.

Testicle weight relative to female body weight produces a ratio which is not statistically significantly different for *Homo* (0.059-0.066), *Pongo* (0.069) or *Hylobates* (0.088), indicating that selection for testicular size is similar among all three species<sup>34</sup>.



Species	Age	Length	Transverse	Dorsoventral	Weight
<i>Homo</i> <sup>170</sup>	Adults	40-50	25	30	10.5-14
<i>Homo</i> <sup>148</sup>	Adults	-	-	-	19-42
<i>Pan</i> <sup>144</sup>	Adults	-	-	-	108-129
<i>Gorilla</i> <sup>83</sup>	Adult	40	20	27	-
<i>Gorilla</i> <sup>3</sup>	16.5 years	38	-	-	-
<i>Gorilla</i> <sup>156</sup>	Adult	-	-	-	19-23
<i>Gorilla</i> <sup>97</sup>	Adult	-	-	-	10.5
<i>Pongo</i> <sup>25</sup>	3 years	19.1	-	-	-
<i>Pongo</i> <sup>144</sup>	-	-	-	-	16.6-40.8
<i>Hylobates</i> <sup>144</sup>	Adults	-	-	-	2.9-6.1
<i>Hylobates agilis</i> <sup>68</sup>	Adult	28	18	-	-
<i>H.concolor</i> <sup>80</sup>	Adult	13.6	7.75	9.5	-
<i>H.hoolock</i> <sup>80</sup>	Juvenile	9.0	3.5	5.0	-
<i>H.hoolock</i> <sup>80</sup>	Subadult	9.8	5.8	7.8	-
<i>Hylobates leuciscus</i> <sup>68</sup>	Immature	10	7.0	-	-
<i>Symphalangus</i> <sup>80</sup>	Subadult	10.2	5.2	7.0	-
<i>Symphalangus</i> <sup>80</sup>	Juvenile	9.0	3.5	6.0	-
<i>Symphalangus</i> <sup>80</sup>	Immature	12.7	3.7	8.5	-

Table 3.6.17. Dimensions (mm) and weights (g) of the testis in the Hominoidea.

	Sample size	Body mass (kg)	Testes mass (g)	Testes/ Body %	Relative testes size
<i>Homo</i> <sup>144</sup>	3	64	50	0.08	0.50
<i>Pan troglodytes</i> <sup>144</sup>	3	44	119	0.27	1.53
<i>Gorilla</i> <sup>64</sup>	1	134	23	0.02	0.14
<i>Gorilla</i> <sup>83</sup>	1	130	18	0.01	-
<i>Pongo</i> <sup>144</sup>	2	75	35	0.05	0.31
<i>Hylobates lar</i> <sup>94</sup>	1	6	6	0.10	0.32
<i>Hylobates moloch</i> <sup>144</sup>	4	6	6	0.10	0.33

Table 3.6.18. Testes mass as a percentage of body mass and relative testes size (ratio of observed/predicted body testes size) in the Hominoidea. Adapted from <sup>93</sup>.

### Epididymis

No information for *Pan* or *Pongo*.

The epididymis is present on the posterolateral side of the testis in *Homo* and *Hylobates*<sup>80, 170</sup>.

In *Homo* and *Hylobates* the caput epididymis reaches the cranial pole of the testis and the cauda epididymis reaches the caudal pole<sup>80, 170</sup>, which is not the case with the smaller epididymis of *Gorilla*<sup>136</sup>. The large caput epididymis projects above the cranial pole of the testis in *Hylobates*<sup>70, 80</sup>.

### 3.6.5.2.1.2 Spermatic cord

#### *Ejaculatory duct*

The thin-walled ejaculatory duct is about 20 mm long in *Homo*<sup>170</sup> and about 10 mm long in *Gorilla*<sup>35</sup>.

The ejaculatory ducts do not pass through the prostate in *Gorilla*<sup>35</sup>, unlike *Homo* or *Pan*<sup>84, 139, 170</sup>.

#### *Spermatic cord*

The diameter of the spermatic cord in a 16.5 year old *Gorilla* is 15 to 20 mm<sup>3</sup>. In *Symphalangus* the diameter of the cord is uniformly 6.8 mm in diameter<sup>80</sup>, while in *Hylobates* the maximum diameter of the cord ranges from 6.3 to 6.9 mm, narrowing proximally to 4.7-4.9 mm<sup>80</sup>.

#### *Vasa deferentia*

The vasa deferentia pass on the posterior surface of the bladder, converging toward the midline in *Homo* and *Gorilla*<sup>35, 136, 170</sup>.

Each vas deferens unites with the duct of the seminal vesicle before entering the urethra in *Homo* and African apes<sup>35, 84, 136, 170</sup>.

The wall of the duct is thicker than the diameter of the lumen in *Homo*, *Gorilla* and hylobatids<sup>35, 80, 170</sup>. It is more muscular in *Gorilla* than in *Homo* or *Pongo*, while the vas of *Pan* has a greater cross-sectional area than *Homo* or any other great ape<sup>39</sup>. Longitudinal and circular muscle fibres are present in *Homo* and hylobatids<sup>80, 170</sup>. The calibre of the duct gradually increases posterior to the bladder in *Gorilla*<sup>136</sup>, but there is no distinct ampulla, such as is present in *Homo* and *Hylobates*<sup>70, 170</sup>.

### 3.6.5.2.1.3 Prostate and seminal vesicles

#### *Prostate*

A single body in *Homo* and apes<sup>70, 80, 83, 84, 156, 170</sup>, in *Gorilla*, however, paired prostates may be present<sup>35</sup>, and Raven found the gland to be united anteriorly, with the posterior lobes in contact but unfused<sup>136</sup>. Hosokawa and Kamiya found a single prostate divided by two longitudinal clefts on its posterior surface into three lobes in *Gorilla*<sup>83</sup>.

The apex of the gland is directed inferiorly in *Homo* and *Hylobates*<sup>80, 170</sup>, but superiorly in *Gorilla*<sup>35</sup>.

The anterior part of the prostate is narrow in *Homo*, *Pan* and *Hylobates*<sup>70, 80, 84, 170</sup>.

The base of the gland is in contact with the neck of the bladder in *Homo* and *Hylobates*<sup>80, 170</sup>, but not in *Symphalangus*<sup>80</sup>.

The relationship between the prostate and the urethra is given in 3.6.5.1.4.1.

Species	Age	Height	Width	AP Thickness	Weight
<i>Homo</i> <sup>170</sup>	Adult	30	40	20	8
<i>Gorilla</i> <sup>a, 35</sup>	Adult	25	15	7	-
<i>Gorilla</i> <sup>83</sup>	Adult	18	30	11	-
<i>Gorilla</i> <sup>156</sup>	Adult	32	26	10	-
<i>Gorilla</i> <sup>136</sup>	Adult	20	20	20	-
<i>Gorilla</i> <sup>3</sup>	16.5 years	40	-	-	-
<i>Gorilla</i> <sup>88</sup>	32 years	-	-	-	15
<i>Hylobates hoolock</i> <sup>80</sup>	-	-	11	9.5	-

**Table 3.6.19. Dimensions (mm) and weight (g) of the prostate in *Homo*, *Gorilla* and *Hylobates*.<sup>a</sup>**  
**Dimensions for one of a pair.**

*Seminal vesicles*

No information for *Pan*.

Each seminal vesicle consists of a coiled tube with diverticula in *Homo* and *Symphalangus*<sup>80, 170</sup>, while no diverticula are found in *Pongo* or *Hylobates*<sup>70, 80, 133</sup>.

Species	Age	Length	Width	Breadth
<i>Homo</i> <sup>170</sup>	Adult	50	-	-
<i>Gorilla</i> <sup>35</sup>	-	50-60	5-7	-
<i>Gorilla</i> <sup>83</sup>	Adult	R 40	9	9
		L 35	11	4
<i>Gorilla</i> <sup>136</sup>	Adult	45	5-8	-
<i>Pongo</i> <sup>25</sup>	-	25	-	-
<i>Hylobates hoolock</i> <sup>80</sup>	Juvenile	5.0	-	-
<i>Hylobates concolor</i> <sup>80</sup>	Adult	10.0	-	-
<i>Hylobates agilis</i> <sup>68</sup>	Adult	20	7.5	-
<i>Hylobates leuciscus</i> <sup>68</sup>	Immature	5	1.5	-
<i>Symphalangus</i> <sup>80</sup>	Subadult	11.2	-	-
<i>Symphalangus</i> <sup>80</sup>	Juvenile	15.0	-	-
<i>Symphalangus</i> <sup>80</sup>	Immature	6.1	-	-

**Table 3.6.20. Dimensions (mm) of the seminal vesicles in *Homo*, *Gorilla* and Asian apes.**

### *Bulbo-urethral glands*

These glands are present in all apes and *Homo*<sup>25, 35, 70, 80, 139</sup>, although Raven did not find them in *Gorilla*<sup>136</sup>.

The paired glands are situated within the sphincter urethrae in *Homo* and African apes<sup>35, 139, 170</sup>, lying on either side of the membranous urethra in *Hylobates*<sup>70, 80</sup>.

The duct of each gland opens into the penile urethra in *Homo*, *Gorilla* and *Hylobates*<sup>35, 70, 80, 170</sup>.

**3.6.5.2.1.4 Urethra** See 3.6.5.1.4.1

**3.6.5.2.1.5 External genitalia**

**3.6.5.2.1.5.1 Penis**

#### *Corpora cavernosa*

No information for *Pongo*.

A fibrous septum is present between the corpora cavernosa in *Homo* and *Gorilla*<sup>136, 170</sup>, while in both species of *Pan* the corpora cavernosa are undivided<sup>87</sup>.

The crura are more cylindrical in *Hylobates hoolock* than in *Hylobates concolor*<sup>80</sup>, while in *Symphalangus* the crura are relatively more flattened craniocaudally than in *Hylobates hoolock*<sup>80</sup>.

#### *Glans*

The glans penis is demarcated in *Homo*<sup>170</sup>, 3/6 *Pan*<sup>43, 118, 181, 182</sup>, 1/2 *Pan paniscus*<sup>141</sup>, 5/8 *Gorilla*<sup>43, 63, 79, 86, 182</sup>, 2/20 *Pongo*<sup>31</sup>, 1/3 *Hylobates*<sup>80</sup> and 1/2 *Symphalangus*<sup>80</sup>.

In the remaining *Pan* specimens<sup>29, 87, 130, 154</sup> and 10/21 *Pongo*<sup>25, 31, 154, 182</sup> the apex of the penis is cylindrical and smooth, while in 3/8 *Gorilla*<sup>78, 115, 136</sup>, 8/21 *Pongo*<sup>31, 131, 138</sup> and 3/5 hylobatids<sup>80, 130</sup> it is dome-like.

A ventral groove in the glans is present in *Gorilla*<sup>43, 136, 153</sup> and *Hylobates*<sup>80</sup>, represented in *Homo* by a hiatus from the meatus to the coronal sulcus<sup>153</sup>.

The urethral opening on the tip of the penis is a sagittal slit in *Homo*<sup>170</sup>, *Pan*<sup>73</sup> and 3/6 *Gorilla*<sup>79, 136</sup>, but crescentic in 3/6 *Gorilla*<sup>78</sup> and in *Hylobates*<sup>80</sup>. In *Pan paniscus*<sup>87</sup>, *Hylobates*<sup>7</sup> and *Symphalangus*<sup>80</sup> the meatal opening is described as Y-shaped, and as lobate in *Pan paniscus*<sup>87</sup> and *Symphalangus*<sup>80</sup> in the former of which there are four lobes, or lappets<sup>87</sup>.

Species	Age	Proximodistal	Transverse	Sagittal	Length of EUM
<i>Gorilla</i> <sup>136</sup>	Adult	20	20	8	-
<i>Gorilla</i> <sup>79</sup>	Juvenile	3.6	4.2	6.9	4.0
<i>Gorilla</i> <sup>78</sup>	Juvenile	6.5	7.0	8.2	4.4
<i>Gorilla</i> <sup>78</sup>	Subadult	8.0	11.0	13.0	6.5
<i>Gorilla</i> <sup>78</sup>	Adult	7.5	10.0	12.0	6.0
<i>Hylobates concolor</i> <sup>80</sup>	Newborn	3.7	1	2.5	3
<i>Hylobates hoolock</i> <sup>80</sup>	Juvenile	4	4	-	4
<i>Hylobates hoolock</i> <sup>80</sup>	Subadult	3	3.8	5.3	2
<i>Symphalangus</i> <sup>80</sup>	Subadult	4	4	7	3
<i>Symphalangus</i> <sup>80</sup>	Juvenile	3	4.5	-	2.5
<i>Symphalangus</i> <sup>80</sup>	Immature	3.5	5.5	5.6	3.5

Table 3.6.21. Dimensions (mm) of the glans penis in *Gorilla* and hylobatids.

### *Os penis*

The penis bone, or baculum, is a rod of bone or cartilage at the distal end of the septum joining the two corpora cavernosa<sup>116</sup>.

The penis bone is absent from *Homo*<sup>78</sup>, and has been reported as absent from specimens of *Gorilla*<sup>59, 78</sup>, *Pongo*<sup>25</sup> and fetal *Hylobates concolor*<sup>80</sup>. Hill and Harrison-Matthews review the literature with regard to penis bones in *Homo*<sup>78</sup>.

Species	Length	Details
<i>Pan</i> <sup>78</sup>	8.4	Two adults
<i>Pan</i> <sup>59</sup>	8.5	Juvenile
<i>Pan</i> <sup>170</sup>	8.5	Adult
<i>Pan</i> <sup>143</sup>	9.0	Subadult, 40.2 kg
<i>Pan</i> <sup>143</sup>	10.5	Adult, 43.8 kg
<i>Pan</i> <sup>152</sup>	13	Adult
<i>Pan paniscus</i> <sup>87</sup>	8.5	12-13 years
<i>Gorilla</i> <sup>78</sup>	12.7	Adult
<i>Gorilla</i> <sup>78</sup>	7.0	Subadult
<i>Pongo</i> <sup>143</sup>	11	77.1 kg
<i>Pongo</i> <sup>170</sup>	12	Adult
<i>Pongo</i> <sup>131</sup>	12	Two adults, one 76.5 kg
<i>Pongo</i> <sup>133</sup>	15	-
<i>Pongo</i> <sup>78</sup>	11.4	Bornean
<i>Pongo</i> <sup>78</sup>	13.7	Bornean
<i>Pongo</i> <sup>78</sup>	14.7	Sumatran
<i>Pongo</i> <sup>59</sup>	8	Subadult
<i>Pongo</i> <sup>50</sup>	<15.7	Adult
<i>Hylobates hoolock</i> <sup>80</sup>	3	Juvenile
<i>Hylobates concolor</i> <sup>80</sup>	9	Adult
<i>Hylobates</i> <sup>6</sup>	2.7	Infant
<i>Hylobates agilis</i> <sup>68</sup>	6	Adult
<i>Hylobates leuciscus</i> <sup>68</sup>	3	Immature
<i>Hylobates leuciscus</i> <sup>59</sup>	2.75	Juvenile
<i>Hylobates leucogenys</i> <sup>113</sup>	8-10	Fifteen specimens
<i>Hylobates concolor</i> <sup>113</sup>	6-9	Ten specimens
<i>Symphalangus</i> <sup>59</sup>	14.5	Adult
<i>Symphalangus</i> <sup>59</sup>	7	Juvenile
<i>Symphalangus</i> <sup>80</sup>	3.5	Subadult
<i>Symphalangus</i> <sup>80</sup>	2.5	Juvenile

Table 3.6.22. Penis bone length (mm) in hominoids.

### *Penile spines*

Spines or spicules are normally absent from the penile surface of *Homo*<sup>170</sup>, *Gorilla*<sup>78</sup>,  
<sup>79</sup> and *Pongo*<sup>30, 73, 133, 131</sup>. They may be found on the glans of *Homo* as a rare  
anomaly<sup>70</sup>.

In *Pan*, the spicules are most numerous on the sides of the glans<sup>70, 73, 79, 87</sup>. In  
*Hylobates* the spicules are better developed, and are absent from the glans and the  
dorsum of the shaft<sup>70, 80</sup>, while in *Symphalangus* the spicules are present on the shaft  
adjacent to the glans<sup>80</sup>.

### *Penis length*

Scores of penile complexity, based on a scale of 1-5 for each of the following  
characters: length of *pars libera*, distal penis morphology, size of penile spines and  
baculum length, result in a rating of 11/20 in both species of *Pan*, 7/20 for *Gorilla*,  
9/20 in *Pongo* and 8/20 in hylobatids<sup>31, 39</sup>.



Species	Details	Length	Diameter
<i>Homo</i> <sup>30</sup>	54 adults	130	-
<i>Pan</i> <sup>147</sup>	-	80	-
<i>Pan</i> <sup>30</sup>	6 adults	140	-
<i>Pan paniscus</i> <sup>87</sup>	12-13 years	43.0	-
<i>Gorilla</i> <sup>136</sup>	Adult	90.0	20-30
<i>Gorilla</i> <sup>81</sup>	6 months	11.0	-
<i>Gorilla</i> <sup>147</sup>	-	30.0	-
<i>Gorilla</i> <sup>115</sup>	Adult	100.0	15
<i>Gorilla</i> <sup>78</sup>	Adult	11.5	-
<i>Gorilla</i> <sup>79</sup>	Juvenile	18.0	-
<i>Gorilla</i> <sup>78</sup>	3 years	20.0	5-12.1
<i>Gorilla</i> <sup>78</sup>	Subadult	11.5	14
<i>Gorilla</i> <sup>78</sup>	Adult	10.0	15-27
<i>Gorilla</i> <sup>156</sup>	Adult	60	12
<i>Gorilla</i> <sup>176</sup>	2 years 8 months	20	-
<i>Gorilla</i> <sup>3</sup>	16.5 years	60	-
<i>Gorilla</i> <sup>164</sup>	8 years	140	15
<i>Gorilla</i> <sup>108</sup>	7 years	50	-
<i>Gorilla</i> <sup>30</sup>	-	30	-
<i>Pongo</i> <sup>25</sup>	3 years	51	-
<i>Pongo</i> <sup>40, 147</sup>	-	40	-
<i>Pongo</i> <sup>31</sup>	9 adults	90	-
<i>Pongo</i> <sup>31</sup>	4 subadults	70	-
<i>Hylobates agilis</i> <sup>68</sup>	Adult	20	10
<i>Hylobates leuciscus</i> <sup>68</sup>	Immature	10	3
<i>Hylobates concolor</i> <sup>80</sup>	Newborn	11.4	1.0-5.6
<i>Hylobates concolor</i> <sup>80</sup>	Adult	13.5	4.3-9.0
<i>Hylobates hoolock</i> <sup>80</sup>	Juvenile	15.0	3.5-7.5
<i>Hylobates hoolock</i> <sup>80</sup>	Subadult	17.2	3.2-7.2
<i>Symphalangus</i> <sup>68</sup>	Subadult	18	3.7-6.6
<i>Symphalangus</i> <sup>68</sup>	Juvenile	17	4.0-7.0
<i>Symphalangus</i> <sup>68</sup>	Immature	18	3.5-7.5

Table 3.6.23. Dimensions (mm) of the *pars libera* of the penis in the Hominoidea.

## Prepuce

The prepuce may be absent from *Gorilla*<sup>156</sup>.

The prepuce is pigmented in *Gorilla* and hylobatids<sup>78, 80</sup> and unpigmented in *Pongo*<sup>31</sup> and fetal *Hylobates concolor*<sup>80</sup>, while a few hairs are present on the prepuce in *Gorilla*<sup>78</sup>.

A frenulum is present in *Homo* and *Symphalangus*<sup>80, 170</sup>, but absent from *Pan*<sup>73</sup> and *Pongo*<sup>182</sup>.

### 3.6.5.2.1.5.2 Scrotum

#### Scrotum

The scrotum is a dependant sac in *Homo*<sup>170</sup>, semi-pendulous in *Pan*<sup>120, 181, 182</sup> and some hylobatids<sup>7, 80, 118, 146, 177, 182</sup>, while in *Gorilla*<sup>23, 46, 63, 71, 78, 98</sup> and *Pongo*<sup>55, 78</sup> and most hylobatids<sup>102, 130, 153, 154, 177, 183</sup>, the scrotum is hardly developed,

represented by bilateral low, transverse (*Gorilla*<sup>129</sup>; *Pongo*<sup>78</sup>) or ovoid (*Gorilla*<sup>79</sup>; *Hylobates*<sup>80</sup>) areas, close to the body wall.

Hill and Kanagasuntheram suggest that in gibbons, postpenial scrotal sacs appear during fetal life. The testes are then withdrawn, returning, if at all, to a perineal site during late adolescence<sup>80</sup>.

The scrotal area in all apes and *Homo* is divided by a sagittal cutaneous raphe<sup>46, 63, 70, 78, 79, 80, 98, 170, 182</sup>, with the exception of 2/3 *Pan*<sup>73, 78</sup> and *Symphalangus*<sup>182</sup>.

The surface of the scrotal area is smooth in *Pan*<sup>78</sup> and hylobatids<sup>80</sup>, and rugose in *Gorilla*<sup>78</sup>, *Pongo*<sup>78</sup> and *Symphalangus*<sup>80</sup>, but the appearance of the scrotum varies with age and circumstances in *Homo*<sup>170</sup>.

The scrotal skin is pigmented in all<sup>73, 78, 79, 80, 182</sup>, except a juvenile *Pongo*<sup>182</sup> and a juvenile *Symphalangus*<sup>80</sup>, while the raphe is unpigmented in African apes<sup>73</sup>. The hair covering of the scrotum is sparse in all<sup>55, 73, 78, 79, 136, 182</sup> except *Hylobates*, in which the scrotal region is densely haired and may have a contrasting hair tuft<sup>177, 80</sup>.

The scrotal area is postpenial in *Homo* and *Pan*<sup>170, 182</sup>, postpenial or post/parapenial in *Gorilla*<sup>78, 77, 182</sup>, *Pongo*<sup>182</sup>, and *Symphalangus*<sup>80, 119, 146, 182</sup> and prepenial, parapenial or postpenial in *Hylobates*<sup>7, 70, 80, 130, 146</sup>.

### 3.6.5.2.2 Female

#### 3.6.5.2.2.1 Ovary

##### *Ligament of the ovary*

The ligament of the ovary is round in *Homo* and African apes<sup>180</sup>, but flattened in *Hylobates*<sup>70, 180</sup>.

The ligament is relatively shorter in *Gorilla*<sup>6</sup> and *Pongo*<sup>180</sup> than in *Hylobates*<sup>180</sup>.

##### *Ovary*

The ovaries lie closer to the uterus in *Pongo*<sup>180</sup> than in *Homo*, African apes or *Hylobates*<sup>180</sup>. In 2/5 *Pan*, there was an asymmetrical distribution of cortical ovarian stroma on the stalk, while in 1/5 *Pan*, the left ovary was enlarged and cystic<sup>184</sup>.

The ovaries are almond-shaped in *Homo*<sup>170</sup>, elongated and thin<sup>152, 180</sup> or flat and rounded<sup>152</sup> in *Pan*, elongated in *Gorilla*<sup>180</sup>, oval<sup>180</sup> or elongated and narrow<sup>127</sup> in *Pongo*, and oval in *Hylobates*<sup>70, 180</sup>. The ovaries are less fusiform and flattened in Asian than in African apes<sup>70, 180</sup>, and appear to be less richly innervated in Asian apes than the ovaries of *Homo* or African apes<sup>19</sup>.

The estimated number of ova in both ovaries of a 10 year old *Pan* was around 310 k, in a pregnant *Gorilla* around 105 k and in a 16-17 year old *Pongo* was around 450 k<sup>140</sup>.

In general similarity to *Homo*, Saglik ranks the ovaries as follows: *Pongo*, *Pan*, *Gorilla*, then *Hylobates*, the latter of which differs markedly from the other apes. Great ape ovaries are of the “fibrous” type, while in *Hylobates* follicular tissues predominate<sup>140</sup>.

	Side	Length	Width	Dorso-ventral
<i>Homo</i> <sup>170</sup>	-	30	15	10
<i>Pan</i> <sup>180</sup>	R	19	11	4
	L	30	13	6
<i>Pan</i> <sup>152</sup>	R	20	15	15
	L	25	5	2
<i>Pan</i> <sup>179</sup>	L	27	15	10
<i>Gorilla</i> <sup>180</sup>	R	40	11	9
	L	43	28	10
<i>Gorilla</i> (a), <sup>180</sup>	R	38	26	26
	L	38	12	12
<i>Gorilla</i> (a), <sup>180</sup>	R	30	16	12
	L	28	21	14
<i>Gorilla</i> <sup>5</sup>	-	40	-	-
<i>Pongo</i> <sup>180</sup>	R	21	16	10
	L	20	17	17
<i>Hylobates pileatus</i> <sup>180</sup>	R	16	12	7
	L	16	10	10
<i>Hylobates</i> <sup>36</sup>	-	10-18	5-10	5-10
<i>Hylobates</i> <sup>36</sup>	-	12	6	3
	-	12	8	7
<i>Hylobates hoolock</i> <sup>68</sup>	R	11	8	7
	L	9	7.5	5.5

Table 3.6.24. Greatest dimensions (mm) of the ovaries in the Hominoidea. (a) Pregnant.

### 3.6.5.2.2.2 Uterine tubes

#### *Fimbriae*

No information for *Pongo*.

The fimbriae are irregular in length in *Homo*<sup>170</sup>, while in *Gorilla* they are approximately equal in length<sup>6, 180</sup>. The fimbriae of *Hylobates* are between 6 and 10 mm in length<sup>11, 70</sup>.

The ovarian fimbria reaches the tubal extremity of the ovary in *Homo*, *Pan* and *Hylobates*<sup>152, 170</sup> (unilaterally in *Pan*<sup>180</sup>), but fails to reach the ovary in *Gorilla*<sup>6, 58, 180</sup>.

The gap in *Gorilla* and unilaterally in *Pan* may be filled by a ligament<sup>180</sup>.

#### *Mesosalpinx*

No information for *Pongo*.

The mesosalpinx contains more fat in *Gorilla* than in *Homo*, *Pan* or *Hylobates*<sup>6, 180</sup>.

A superior mesosalpinx has been found in some *Hylobates*<sup>36, 70</sup>, but seems to be absent from other specimens of *Hylobates*, and from *Homo* and African apes<sup>180</sup>.

#### *Uterine tube*

No information for *Pongo*.

The abdominal orifice of the uterine tube is 2 mm in diameter in *Gorilla*<sup>6</sup>, and 3 mm in *Homo*<sup>170</sup>.

A dilated ampulla forms more than half of the length of the uterine tube in *Homo*<sup>170</sup>.

The diameter of the tube is relatively constant throughout in African apes<sup>6, 152, 180</sup>, although there may be slight enlargement to form an ampulla in *Gorilla*<sup>6</sup>.

The muscular layer of the uterine tube is more developed in *Gorilla* than in *Homo*<sup>180</sup>.

The uterine orifice of the uterine tube is smaller than the abdominal orifice in *Homo* and *Gorilla*<sup>6, 170</sup>. No muscular sphincter is found at this orifice in *Homo* or *Gorilla* although longitudinal muscle fibres are present<sup>170, 180</sup>.

### 3.6.5.2.2.3 Uterus and cervix

#### *Broad ligament*

The area of attachment of the broad ligament to the uterus is more extensive in apes than in *Homo*<sup>70, 180</sup>.

The broad ligaments of *Hylobates* are more delicate and closer together than those of *Pongo*<sup>180</sup>.

#### *Cervix*

The infravaginal portion of the cervix is cylindrical in *Homo*, *Gorilla* and *Pongo*<sup>170, 180</sup> and oval in *Pan*<sup>180</sup>.

Harrison-Matthews found the cervix in *Hylobates* to project obliquely into the vagina, so that on the anterior surface it is represented only by a low ridge<sup>68</sup>.

The external os is slit-shaped<sup>180</sup> or circular<sup>170</sup> in *Homo*, round<sup>152</sup> or slit-like<sup>180</sup> in *Pan*, slit-shaped<sup>6</sup> or funnel-shaped (pregnant<sup>180</sup>) in *Gorilla*, and funnel-shaped in *Hylobates*<sup>180</sup>.

The muscular walls of the cervix appear to be much thicker in *Gorilla* than in *Homo*<sup>180</sup>.

Species	Age	Length	Diameter
<i>Homo</i> <sup>180</sup>	Adult	30-32	19-27
<i>Pan</i> <sup>180</sup>	Adult	14	8
<i>Pan</i> <sup>123, (a)</sup>	-	20	-
<i>Pan</i> <sup>152</sup>	-	12	11
<i>Pan</i> <sup>140</sup>	10 years	35	-
<i>Gorilla</i> <sup>180</sup>	Adult	38	32
<i>Pongo</i> <sup>180</sup>	Adult	8	6
<i>Hylobates pileatus</i> <sup>180</sup>	Adult	8	8
<i>Hylobates pileatus</i> <sup>180</sup>	Adult	9	8
<i>Hylobates hoolock</i> <sup>68</sup>	Adult	11	-

**Table 3.6.25. Largest diameter (mm) of the infravaginal segment of the cervix in the Hominoidea. (a) Pregnant.**

### *Myometrium*

Young found ovarian tissue in the connective tissue surrounding the myometrium near the uterotubal junction in 1/5 *Pan*, although this may have been due to accidental transplantation during surgery<sup>184</sup>.

External, middle and internal muscle layers are less distinct in *Gorilla*<sup>180</sup> than in *Homo*<sup>170</sup> due to the increased interlacing of the fibres.

The external layer of *Homo* consists mainly of longitudinal fibres, the middle layer has no regular arrangement, while the internal layer contains longitudinal and circular fibres<sup>170</sup>.

In *Gorilla*, the external surface of the uterus has a thin layer of oblique and circular muscle fibres, followed by a layer of longitudinal fibres, a layer of oblique interlacing bundles, a second layer of longitudinal fibres and finally non-laminar interlacing fibres making up three-quarters of the uterine wall<sup>180</sup>.

The thickness of the muscular wall of the uterus is about 12.5 mm in non-pregnant *Homo*<sup>170</sup>, hypertrophying in pregnancy. In a pregnant mountain *Gorilla* the uterine muscle reaches 28 mm thick, but only 17 mm thick in a pregnant lowland *Gorilla*<sup>180</sup>.

#### *Round ligament*

No information for *Pongo*.

Described as flat bands in *Homo*<sup>170</sup> and *Hylobates*<sup>70</sup>, the round ligaments are thick in *Pan*<sup>140, 152</sup>.

The round ligament in African apes is attached nearer to the cervix than in *Homo* and *Hylobates*<sup>6, 70, 140, 180</sup>.

The ligament of the ovary, uterine tube and the round ligament attach to the uterus at relatively widely separated points in *Gorilla*, while in *Homo* these ligaments converge more or less to a single point on the side of the uterus<sup>180</sup>.

#### *Uterus*

No marked fundus is present in *Pan*<sup>152</sup>, unlike *Homo*, *Gorilla* or *Hylobates*<sup>36, 170, 180</sup>.

There is no distinct boundary or flexion between the body of the uterus and the cervix in *Gorilla*<sup>6</sup>, unlike *Homo*<sup>170</sup>.

Dorso-ventral flattening of the uterus is more evident in *Homo*, *Pan* and Asian apes than in *Gorilla*<sup>70, 180</sup>.



Species	Age	Length	Breadth	Dorsoventral
<i>Homo</i> <sup>170</sup>	Adult	75	50	25
<i>Pan</i> <sup>152</sup>	Juvenile	15	15	-
<i>Pan</i> <sup>179</sup>	Adolescent	50	30	20
<i>Pan</i> <sup>140</sup>	10 years	30	29	26
<i>Pan</i> <sup>180</sup>	Adult	51	37	21
<i>Pan</i> <sup>46</sup>	Adult	65	40	27
<i>Gorilla</i> <sup>5</sup>	Subadult	40	-	-
<i>Gorilla</i> <sup>180</sup>	Adult	101	52	46
<i>Gorilla</i> <sup>180</sup>	Adult (a)	111	81	76
<i>Gorilla</i> <sup>180</sup>	Adult (a,b)	105	90	55
<i>Pongo</i> <sup>180</sup>	16-17 years	42	28	18
<i>Hylobates</i> <sup>36</sup>	Adult	35-50	20-25	-
<i>Hylobates hoolock</i> <sup>68</sup>	Adult	26	20	12
<i>Hylobates pileatus</i> <sup>180</sup>	Adult	45	25	19
<i>Hylobates pileatus</i> <sup>180</sup>	Adult	44	25	19

Table 3.6.26. Greatest dimensions (mm) of the uterus in the Hominoidea. (a) Pregnant. (b) Fetus of crown-rump length 88.5 mm.

#### 3.6.5.2.2.4 Vagina

##### *Hymen*

No information for *Pongo* or *Hylobates*.

When present in *Homo*, the hymen vaginae is a thin fold of mucous membrane at the vaginal orifice, variable in shape and extent<sup>170</sup>.

The hymen is absent from *Pan*<sup>152</sup>, although Hill and Wislocki have found remnants<sup>75, 180</sup>.

Ashley-Montagu did not find any trace of a hymen in an infant *Gorilla*<sup>4</sup>, while two further *Gorilla* had relatively well-developed hymens<sup>58, 136</sup>.

## *Vagina*

As in *Homo*<sup>170</sup>, the posterior fornix is deeper than the anterior fornix in African apes and *Hylobates*<sup>6, 70, 140, 152</sup>.

Transverse ridges in the mucous membrane of the vagina are present in *Homo*<sup>170</sup> and in African apes, although less well demarcated<sup>36, 37, 170</sup> [6, 58, 152, 180]. The rugae are practically absent from Asian apes<sup>180</sup>, although they may be more developed in fetal *Hylobates*<sup>37</sup>. Variations in the size of the mucosal folds in *Hylobates* may be related to the phase of the reproductive cycle<sup>36</sup>.

The lower part of the vagina in all apes, but not in *Homo*<sup>170</sup>, displays longitudinal folds<sup>70, 75, 152, 180</sup>.

## *Vestibule*

No information for *Hylobates*.

The vestibule is narrow and "boat-shaped" in *Homo*<sup>75</sup>, irregularly shaped in *Pan*<sup>75</sup>, triangular in *Gorilla*<sup>136</sup> and almost circular in *Pongo*<sup>182</sup>.

Greater vestibular glands are present in *Homo*<sup>170</sup> and variably in *Pan*<sup>75, 152</sup>.

### **3.6.5.2.2.5 External genitalia**

#### **3.6.5.2.2.5.1 Clitoris**

## *Clitoris*

No information for *Pongo*.

### Body

The body of the clitoris in *Homo*, *Pan* and *Hylobates* consists of two corpora cavernosa separated by an incomplete pectiniform septum<sup>70, 75, 152, 170</sup>.

The external surfaces of the clitoris are pigmented in *Gorilla*<sup>5</sup> and *Hylobates hoolock*<sup>70</sup>.

Species	Age	Length	Breadth	AP diameter
<i>Pan</i> <sup>75</sup>	Juvenile	12.7	-	-
<i>Pan</i> <sup>75</sup>	Juvenile	9.5	-	-
<i>Pan</i> <sup>75</sup>	Adult	16.5	-	-
<i>Pan</i> <sup>75</sup>	Adult	16.0	-	-
<i>Pan</i> <sup>75</sup>	Adult	16.7	-	-
<i>Gorilla</i> <sup>4</sup>	About 2.5 years	9.0	5.0	7.0
<i>Hylobates hoolock</i> <sup>68</sup>	-	7.0	5.0	-

Table 3.6.27. Dimensions (mm) of the corpus clitoris in African apes and *Hylobates*.

No os clitoridis has been found in *Hylobates*<sup>70</sup>, while Gerhardt noted an os clitoridis about 4 mm long in *Symphalangus*<sup>59</sup>.

### Glans

No information for *Pongo*.

The glans may be absent from *Pan paniscus*<sup>87</sup>, but has been noted in this species<sup>141</sup>.

The glans clitoridis has a ventral cleft in African apes and *Hylobates*<sup>5, 6, 11, 32, 33, 37, 58, 70, 75, 142, 182, 185</sup>.

In *Pan*, the glans may be pigmented or unpigmented<sup>75</sup>.

Species	Age	Height	Breadth	Dorso-ventral
<i>Pan</i> <sup>75</sup>	Juvenile	6.2	6.0	2.4
<i>Pan</i> <sup>75</sup>	Juvenile	7.2	6.4	6.0
<i>Pan</i> <sup>75</sup>	Adult	7.6	8.0	8.2
<i>Pan</i> <sup>75</sup>	Adult	5.0	6.0	10.0
<i>Pan</i> <sup>75</sup>	Adult	8.5	7.5	8.4
<i>Gorilla</i> <sup>4</sup>	About 2.5 years	5.0	6.0	-

Table 3.6.28. Dimensions (mm) of the glans clitoridis in African apes.

### *Frenulum*

No information for *Pongo*.

The frenulum of the clitoris in *Homo* is the point where the labia minora of the opposing sides unite on the inferior surface of the clitoris<sup>170</sup>.

A frenulum is present in *Homo* and African apes<sup>5, 24, 75, 87, 136, 170</sup>. In *Pan*, the frenulum has a greater extent than in *Homo*, being continued from the glans onto the whole length of the body of the clitoris<sup>75</sup>.

Wislocki did not find the frenulum in an infant *Gorilla*<sup>182</sup>, while the frenulum of *Hylobates* may not be continuous with the labia minora<sup>32, 33, 70, 182</sup>.

### *Prepuce*

No information for *Pongo*.

The labia minora in *Homo* divide into two parts, the upper divisions of which unite above the clitoris to form the prepuce of the clitoris<sup>170</sup>.

The prepuce is also present in African apes and *Hylobates*<sup>5, 24, 32, 33, 75, 87, 136, 142, 182</sup>, although Harrison-Matthews states that the prepuce in *Hylobates* is rudimentary<sup>70</sup>.

The prepuce is unpigmented in *Pan*<sup>75, 90, 185</sup>, unlike *Gorilla*<sup>5</sup>.

In *Gorilla*, the prepuce possesses a few short hairs<sup>5</sup>. Ashley-Montagu gives its dimensions in an infant *Gorilla* as 26 mm transversely, and 19 mm anteroposteriorly<sup>5</sup>.

Bright orange smegma is produced by preputial glands in *Pan*<sup>75</sup>.

Species	Age	Preputial thickness
<i>Pan</i>	Juvenile	2.5
<i>Pan</i>	Adult	12.0
<i>Pan</i>	Adult	4.5

Table 3.6.29. Thickness (mm) of the clitoral prepuce in *Pan*. Adapted from <sup>75</sup>.

### 3.6.5.2.2.5.2 Labia majora

#### *Labia majora*

The labia majora of *Homo* consist of prominent longitudinal folds extending from the mons pubis to the perineum. The external surface of each labia in *Homo* is pigmented and haired, which the internal surface is smooth and studded with sebaceous follicles<sup>170</sup>.

In *Pan*<sup>185</sup>, two rolls of hair-bearing unpigmented fibrous and adipose tissue superior to the vulva correspond to the labia majora. Labia majora are absent from adult *Pan*<sup>75</sup>, while in juveniles they are represented by smooth, relatively hairless, unpigmented cutaneous<sup>75</sup> or adipose<sup>152, 182</sup> folds bordering the anterior parts of the vulva. In adults the area formerly occupied by the labia majora contains subcutaneous fat which ends at the base of the labia minora<sup>75</sup>.

*Pan paniscus*<sup>29</sup> shows wrinkled folds of tissue at the dorsal and dorsolateral margin of the vulva, which become lobular when tumescent.

In *Gorilla*<sup>5, 182</sup> the labia majora consist of bilateral adipose cushions extending from the pubic symphysis to the perineum, most prominent anteriorly. As in *Pan*, the labia majora appear to become less prominent with increasing maturity<sup>58, 70, 124</sup>. The external surfaces are sparsely haired and deeply pigmented<sup>5</sup>.

In *Pongo*<sup>30, 55, 182</sup> the labia majora are crescentic adipose cushions extending from the pubic symphysis to the perineum and the region of the labia majora is sparsely haired<sup>182</sup>.

The labia majora in *Hylobates* are folds bordering the vulva, from the symphysis to the perineum<sup>37, 142, 182</sup>, pigmented<sup>182</sup> and sparsely haired<sup>130, 182</sup>. The labia majora persist postnatally<sup>32, 33, 70, 142, 182</sup>, although Deniker states that they become less prominent with age<sup>37</sup>, while others have not found the labia majora in *Hylobates*<sup>12, 154, 183</sup>.

### 3.6.5.2.2.5.3                      Labia minora and mons pubis

#### *Labia minora*

The labia minora in *Homo* are small cutaneous folds, devoid of fat, extending from the clitoris, obliquely on either side of the vagina, to end between the vagina and the labia majora<sup>170</sup>.

In both species of *Pan* the labia minora are relatively large, dependant, unpigmented, puckered folds<sup>29, 75, 152, 180</sup>. As in *Homo*<sup>170</sup>, adipose tissue is absent<sup>75</sup>, the labia minora being composed of loose areolar tissue with some muscular fibres<sup>75</sup>.

The labia minora in *Gorilla* are represented by bilateral quadrilateral adipose cushions<sup>5</sup>. The external surfaces are hairless and pigmented, while the internal surfaces are unpigmented<sup>5, 32, 33, 182</sup>. The medial edges of the labia are relatively

unpuckered<sup>5, 32, 33</sup>. Some authors describe hairs on the lateral surface of the labia minora<sup>6, 142</sup>, and may therefore be describing labia majora.

The labia minora of *Pongo* are large and puckered, being described as "rosette-like"<sup>182</sup>.

The labia minora are large, fleshy and convoluted in *Hylobates*<sup>32, 33</sup>, although they have been described as rudimentary low folds<sup>70, 182</sup>. The colour of the labia minora appears to vary cyclically in *Hylobates*<sup>20</sup>.

Species	Age	Lateral thickness	Maximum protrusion	Length
<i>Pan</i> <sup>75</sup>	Juvenile	3.0	17.8	-
<i>Pan</i> <sup>75</sup>	Juvenile	-	30.0	-
<i>Pan</i> <sup>75</sup>	Adult	7.7	30.0	-
<i>Pan</i> <sup>75</sup>	Adult	6.9	64.0	-
<i>Gorilla</i> <sup>4</sup>	Infant	-	12.0	11.0

Table 3.6.30. Dimensions (mm) of detumescent labia minora in African apes.

#### *Mons pubis*

The mons pubis, a rounded eminence anterior to the pubis, is formed in *Homo* from subcutaneous adipose connective tissue<sup>170</sup>.

In *Pan*, a fatty subcutaneous eminence has been noted on either side of the vestibule<sup>155, 163</sup>, while two low fatty eminences either side of the midline, anterior to the vulva, have been described in *Hylobates*<sup>182</sup>.

The mons pubis is absent from *Gorilla* and *Pongo*<sup>5, 58, 75, 182</sup>, although Deniker shows a fetal *Gorilla* with indications of a mons pubis<sup>37</sup>.

Wislocki suggests that the mons pubis of *Homo* may be homologous with the portion of the labia majora that extends forwards onto the symphysis in great apes<sup>176</sup>.

### 3.6 ENDOCRINE

#### 3.6.1 Suprarenal

##### *Suprarenal glands*

No information for *Pongo* or *Hylobates*.

In *Homo* and *Gorilla* the suprarenal glands lie in contact with the superior poles of the kidneys<sup>49, 83</sup>. In a specimen of *Gorilla*, the right suprarenal gland lay on the posterosuperior aspect of the right lateral lobule of the liver<sup>21</sup>.

The right suprarenal gland in *Gorilla* may be either triangular as in *Homo*<sup>83, 170</sup>, or elongated as in *Pan*<sup>152, 156</sup>.

The left suprarenal gland in *Gorilla* is either elongated as in *Pan*<sup>83, 152</sup> or triangular<sup>156</sup>, while in *Homo* it is crescentic<sup>170</sup>.

Species		BW (kg)	Length	Breadth	Thickness	Weight
<i>Homo</i> <sup>170</sup>		-	50	30	10	5
<i>Pan paniscus</i> <sup>9</sup>		4.62	-	-	-	1.5 (0.033) 1.5 (0.033)
<i>Pan paniscus</i> <sup>9</sup>		4.46	-	-	-	2.0 (0.045) 2.2 (0.049)
<i>Pan paniscus</i> <sup>9</sup>		-	-	-	-	3.5 4.0
<i>Gorilla</i> <sup>49</sup>		-	-	80	-	-
<i>Gorilla</i> <sup>83</sup>	R	130	85, 70, 50(3 sides)	40	15	16.5 (0.012)
	L		75	25	15	12.8 (0.009)
<i>Gorilla</i> <sup>156</sup>	R	227	85	32	16	8.5 (0.004)
	L		6.1	39	19	9.3 (0.004)

**Table 3.6.31. Dimensions (mm) and weights (g) of the suprarenal glands in *Homo*, *Pan paniscus* and *Gorilla*. Numbers in parentheses are suprarenal weights in percentage of body weight (BW).**



## BIBLIOGRAPHY

1. **Allbrook, DB; Galloway, A and Wilson, AMM** (1959): The study of *Gorilla gorilla beringei* with a post-mortem report by A.M.M Wilson. S.Afr.J.Sci. 55, p205-209.
2. **Anthony, R** (1898): Mémoire sur les organes viscéraux d'un jeune orang-outan femelle. Bull.Soc.Anthropol. 9, p246-270.
3. **Antonius, JL; Ferrier, SA and Dillingham, LA** (1971): Pulmonary embolus and testicular atrophy in a gorilla. Folia Primatol. 15, p277-292.
4. **Arvis, G** (1969): Considérations anatomiques sur le hile et le sinus du rein. Ann.Radiol. 12, p75-106.
5. **Ashley-Montagu, MF** (1937): Note on the external genitalia in three female old world primates. Anat.Rec. 69(4), p389-405.
6. **Atkinson, WB and Elftman, H** (1950): Female reproductive system of the gorilla. In: Gregory, WK(ed); The anatomy of the gorilla. Columbia University Press, New York, p205-207.
7. **de Beaux, O** (1917): Sul pene degli antropomorfi. G.Morf. 1, p222-227.
8. **Beddard, FE** (1893): Contributions to the anatomy of the anthropoid apes. Trans.Zool.Soc.Lond. 13, p177-218.
9. **Benirschke, K; Bogart, MH and Adams, F** (1980): The status of the pygmy chimpanzee *Pan paniscus* in the USA. Int.Zoo Yearb. 20, p71-76.
10. **Berry, RJA** (1900): The true caecal apex, or the vermiform appendix: its minute and comparative anatomy. J.Anat.Phys. 35, p83-100.
11. **Bischoff, TLW** (1870): Beiträge zur Anatomie des Hylobates leuciscus and zu einer vergleichenden Anatomie der Muskeln der Affen und des Menschen. Abh.Bayer.Akad.Wiss.München. Math.Phys.Kl. 10, p197-297.
12. **Bischoff, TLW** (1879/80): Vergleichende anatomische Untersuchungen über die äusseren weiblichen Geschlechts- und Begattungsorgane des Menschen und der Affen, insbesondere der Anthropoiden. Abh.Bayer.Akad.Wiss.München. Math.Phys.Kl. 13(2), p207-274.

13. **Blunt, MJ** (1951): Posterior wall of the inguinal canal. *Brit.J.Surg.* 39, p230-233.
14. **Bolau, H** (1876): Cited in Elftman and Atkinson (1950).
15. **Bolk, L** (1898): Beitrag zur Neurologie der unteren Extremität der Primaten. *Morphol.Jahrb.* 25, p305-361.
16. **Bolk, L** (1907): Beiträge zur Affen-Anatomie - VI. Zur Entwicklung und vergleichenden Anatomie des Tractus Urethrovaginalis der Primaten. *Z.Morphol.Anthropol.* 10, p250-316.
17. **Boyer, EL** (1935): The musculature of the inferior extremity of the orang-utan *Simia satyrus*. *Am.J.Anat.* 56(2), p192-256.
18. **van den Broek, AJP** (1908): Ueber einige anatomische Merkmale von Ateles in Zusammenhang mit der Anatomie der Platyrrhinin. *Anat.Anz.* 33, p111-124.
19. **van Campenhout, E** (1951/2): Nouvelle contribution concernant les relations neuro-interstitielles des glandes génitales des primates. *Arch.Anat.Histol.Embryol.* 34, p95-103.
20. **Carpenter, CR** (1941): The menstrual cycle and body temperature in two gibbons (*Hylobates lar*). *Anat.Rec.* 79(3), p291-296.
21. **Chagula, WK** (1961): The liver of the mountain gorilla (*Gorilla gorilla beringei*). *Am.J.Phys.Anthropol.* 19, p309-315.
22. **Champneys, F** (1872): On the muscles and nerves of a chimpanzee (*Troglodytes niger*) and a cynocephalus anubis. *J.Anat.Phys.* 6, p176-211.
23. **Chapman, HC** (1878): On the structure of the gorilla. *Proc.Zool.Soc.Lond.* p385-394.
24. **Chapman, HC** (1879): On the structure of the chimpanzee. *Proc.Zool.Soc.Lond.* p52-63.
25. **Chapman, HC** (1880): On the structure of the orang outang. *Proc.Zool.Soc.Lond.* p160-174.

26. **Chivers, DJ and Hladik, CM** (1980): Morphology of the gastrointestinal tract in primates: comparisons with other mammals in relation to diet. *J.Morphol.* 166, p337-386.
27. **Clarkson, RD and Rain, JH** (1889): Unusual arrangement of the psoas muscle. *J.Anat.Phys.* 23, p504-506.
28. **Cunningham, DJ** (1906): The varying form of the stomach in Man and the Anthropoid apes. *Trans.Roy.Soc.Edinb.* 45, p9-43.
29. **Dahl, JF** (1985): The external genitalia of female pygmy chimpanzees. *Anat.Rec.* 211, p24-28.
30. **Dahl, JF** (1988): External genitalia. In: Schwartz, JH(ed); *Orang-utan biology.* Oxford University Press, New York. p133-144.
31. **Dahl, JF** (1994): Size and form of the penis in orang-utans. *J.Mammal.* 75 (1), p1-9.
32. **Dahl, JF and Nadler, RD** (1992a): Genital swelling in females of the monogamous gibbon, *Hylobates(H.)* lar. *Am.J.Phys.Anthropol.* 89, p101-108.
33. **Dahl, JF and Nadler, RD** (1992b): The external genitalia of female gibbons, *Hylobates(H.)* lar. *Anat.Rec.* 232, p572-578.
34. **Dahl, JF; Gould, KG and Nadler, RD** (1993): Testicle size of orang-utans in relation to body size. *Am.J.Phys.Anthropol.* 90, 229-236.
35. **Delrich, TM** (1978): Pelvic and perineal anatomy of the male gorilla: selected observations. *Anat.Rec.* 191, p433-446.
36. **Dempsey, EW** (1940): The structure of the reproductive tract in the female gibbon. *Am.J.Anat.* 57(2), p229-254.
37. **Deniker, J** (1885): Sur un foetus de gibbon et son placenta. *C.R.Acad.Sci.* 100, p654-656.
38. **Deniker, J** (1885/6): Recherches anatomiques et embryologiques sur les singes anthropoides: Foetus de gorille et de gibbon. *Arch.Zool.Exp.Gen. Ser.2, 3(3),* p1-265.

39. **Dixon, HF** (1987): Observations on the evolution of the genitalia and copulatory behaviour in male primates. *J.Zool.* 213, p423-443.
40. **Dixon, HF; Knight, J; Moore, HDM and Carman, M** (1982): Observations on sexual development in male Orang-utans *Pongo pygmaeus*. *Int.Zoo Yearb.* 22, p222-227.
41. **Dönitz** (1872) Cited in Straus (1934).
42. **Duckworth, WLH** (1915): Morphology and anthropology. 2nd ed. Cambridge University Press, Cambridge.
43. **Duvernoy, M** (1855-6): Des caractères anatomiques de grands singes pseudo-anthropomorphes. *Arch.Mus.Natl.Hist.Nat.(Paris)*. 8, p1-248.
44. **Dwight, T** (1895): Notes on the dissection and brain of the chimpanzee "Gumbo". *Mem.Boston Soc.Nat.Hist.* 5, p31-51.
45. **Eggeling, H** (1896): Zur Morphologie der Damm-muskulatur. *Morphol.Jahrb.* 24, p511-631.
46. **Ehlers, E** (1881): Beiträge zur Kenntnis des Gorilla und Chimpanse. *Abh.K.Ges.Wiss.Göttingen, Math.Phys.Kl.* 28, p3-77.
47. **Eisler, P** (1890): Das Gefäss- und periphere Nervensystem des Gorilla. Tausch and Grosse, Halle.
48. **Elftman, HO** (1932): The evolution of the pelvic floor of primates. *Am.J.Anat.* 51(2), p307-346.
49. **Elftman, H and Atkinson, WB** (1950): The abdominal viscera of the gorilla. In: Gregory, WK (ed); *The anatomy of the gorilla*. Columbia University Press, New York; p197-204.
50. **Fick, R** (1895b): Beobachtungen an einem zweiten erwachsenen Orang-Utang und einem Schimpansen. *Arch.Anat.Physiol. Anat.Abt.* p289-318.
51. **Fiennes, RT-W** (1972): Cited in Scott (1980).

52. **Flower, WH** (1872): Lectures on the comparative anatomy of the organs of digestion of the Mammalia. *Med. Times and Gaz. (London)* 62 (1), p334-337, 392-394.
53. **Foster, JW and Rowley, MJ** (1982): Testicular biopsy in the study of gorilla infertility. *Am. J. Primatol.* 2, S1, p121-125.
54. **Fransen, JWP** (1907): Cited in Glidden and De Garis (1936).
55. **Friedenthal, H** (1910): Sonderformen des menschlichen Liebesbildung. Beiträge zur Naturgeschichte des Menschen. 5, p1-100. Cited in Wislocki (1936).
56. **Gagnon, JA and Clarke, RW** (1957): Renal functions in the chimpanzee. *Am. J. Physiol.* 190, p117-120.
57. **Gegenbaur, C** (1901): Vergleichende Anatomie der Wirbelthiere. Vol. II. Leipzig.
58. **Gerhardt, U** (1906): Die Morphologie des Urogenitalsystems eines weiblichen Gorilla. *Jena. Z. Naturwiss.* 41, p632-654.
59. **Gerhardt, U** (1909): Über das Vorkommen eines Penis- und Clitorisknochen bei Hylobatiden. *Anat. Anz.* 35, p353-358.
60. **Gerhardt, U** (1914): Das Urogenitalsystem der Säugetiere. Bronn's Klassen und Ordnungen der Thier-Reichs. 6(5);2(5), p1-4, 1-48.
61. **Glidden, EM and De Garis, CF** (1936): Arteries of the chimpanzee. I. The aortic arch; II. Arteries of the upper extremity; III. The descending aorta; IV. Arteries of the lower extremity. *Am. J. Anat.* 58(2), p501-527.
62. **Gordon, KCD** (1967): A comparative anatomical study of the distribution of the cystic artery in man and other species. *J. Anat.* 101, p351-359.
63. **Goss, LJ** (1947): The external genitalia of the gorilla, *Gorilla gorilla gorilla* (Savage and Wyman). *Zoologica N. Y.* 32, p97-98.
64. **Gulliver, G** (1839): Observations on the muscular fibres of the oesophagus and heart in some of the Mammalia. *Proc. Zool. Soc. Lond.* 7, p24-129.
65. **Hall-Craggs, ECB** (1962): The testis of *Gorilla gorilla beringei*. *Proc. Zool. Soc. Lond.* 139, p511-514.

66. **Hamerton, AE** (1941): Report on the deaths occurring in the Society's Gardens during 1939-1940. *Proc.Zool.Soc.Lond.* 3, p151-185.
67. **Hamlin, RL; Smith, CR and Carter, WT** (1964): A baseline study of the renal functions, body fluid volumes, and electrolyte intake and output in immature chimpanzees. *Tech.Doc.Report No. AR1-TDR-64-48.*
68. **Harrison, RG** (1949): The comparative anatomy of the blood-supply of the mammalian testis. *Proc.Zool.Soc.Lond.* 119, p325-342.
69. **Harrison, RG and Barclay, AE** (1948): The distribution of the testicular artery (internal spermatic artery) to the human testis. *Brit.J.Urol.* 20, p57-66.
70. **Harrison-Matthews, L** (1946): Notes on the genital anatomy and physiology of the gibbon (*Hylobates*). *Proc.Zool.Soc.Lond.* 116, p339-364.
71. **Hartmann, R** (1885): *Anthropoid apes.* Kegan Paul, Trench and Co. London.
72. **Hepburn, D** (1892): The comparative anatomy of the muscles and nerves of the superior and inferior extremities of the anthropoid apes. *J.Anat.Phys.* 26, p149-186, 324-356.
73. **Hill, WCO** (1946/7): Note on the male external genitalia of the chimpanzee. *Proc.Zool.Soc.Lond.* 116, p129-133.
74. **Hill, WCO** (1949): Some points in the enteric anatomy of the great apes. *Proc.Zool.Soc.Lond.* 119, p19-32.
75. **Hill, WCO** (1951): The external genitalia of the female chimpanzee; with observations on the mammary apparatus. *Proc.Zool.Soc.Lond.* 121, p133-145.
76. **Hill, WCO** (1954): Appendicitis in gibbons. *Proc.Zool.Soc.Lond.* 124, p13-16.
77. **Hill, WCO** (1958): Pharynx, oesophagus, stomach, small and large intestine: form and position. *Primatologia.* 3, p139-207.
78. **Hill, WCO and Harrison-Matthews, L** (1949): The male external genitalia of the gorilla, with remarks on the os penis of other Hominoidea. *Proc.Zool.Soc.Lond.* 119, p363-378.

79. **Hill, WCO** and **Harrison-Matthews, L** (1950): Supplementary note on the male external genitalia of *Gorilla*. Proc.Zool.Soc.Lond. 120, p311-316.
80. **Hill, WCO** and **Kanagasuntheram, R** (1959): The male reproductive organs in certain gibbons (Hylobatidae). Am.J.Phys.Anthropol. 17, p227-241.
81. **Hill, WCO** and **Sabater Pi, J** (1971): Anomaly of the hallux in a lowland gorilla (*Gorilla gorilla gorilla* Savage and Wyman). Folia Primatol. 14, p252-255.
82. **Hon-Jensen, HM** (1930): Cited in Straus (1934).
83. **Hosokawa, H** and **Kamiya, T** (1961): Anatomical sketches of visceral organs of the mountain gorilla (*Gorilla gorilla beringei*). Primates. 3 (1), p1-28.
84. **Humphry, GM** (1866/7): On some points in the anatomy of the chimpanzee. J.Anat.Phys. 1, p254-268.
85. **Huxley, TH** (1864): Lectures on the structure and classification of the Mammalia. Med.Times and Gaz.(London). 1, p564-565.
86. **Huxley, TH** (1871): The anatomy of vertebrated animals. J and A Churchill, London.
87. **Izor, RJ**; **Walchuk, SL** and **Wilkins, L** (1981): Anatomy and systematic significance of the penis of the pygmy chimpanzee, *Pan paniscus*. Folia Primatol. 35, p218-224.
88. **Jacobs, SC**; **Beehler, BA**; **Boese, G**; **Story, MT**; **Clowry, LJ** and **Lawson, RK** (1984): The prostate of the gorilla. Prostate. 5(6), p597-603.
89. **Jdanov, DA** (1965): Anatomie comparée du canal thoracique et des principaux collecteurs lymphatiques du tronc chez les mammifères. Acta Anat. 61, p15-83.
90. **Kanagasuntheram, R** (1954): Observations on the anatomy of the Hoolock Gibbon. Ceylon J.Sci.(G). 5, p71-122.
91. **Keith, A** (1900): The position and manner of fixation of the liver of primates, and the part these factors played in the lobulation of liver. J.Anat.Phys. 33, xxi.

92. **Keith, A** (1902): The extent to which the posterior segments of the body have been transmuted and suppressed in the evolution of man and allied primates. *J. Anat. Phys.* 37, p18-40.
93. **Kenagy, GJ** and **Trombulak, SC** (1986): Size and function of mammalian testes in relation to body size. *J. Mammal.* 67 (1), p1-22.
94. **Kennard, MA** and **Willner, MD** (1941): Findings at autopsies of seventy anthropoid apes. *Endocrinol.* 28, p977-984.
95. **Kihara, T** and **Teshima, G** (1935): Cited in Jdanov (1965).
96. **King, AD**; **Hine, AL**; **McDonald, C** and **Abrahams, P** (1993): The ultrasound appearance of the normal psoas muscle. *Clin. Radiol.* 48, p316-318.
97. **Kirkman, H** (1946): A simian, deeply cleft, bilobed gall bladder with a "phrygian cap". *Anat. Rec.* 95(4), p423-441.
98. **Klaatsch, H** (1890): Über den Descensus testicularum. *Morphol. Jahrb.* 16, p587-646.
99. **Kleinschmidt, A** (1949/50): Vergleichend-anatomische Untersuchungen an der Aorta des Gorilla. *Anat. Anz.* 97, p363-366.
100. **Koch, W** (1937): Bericht über das Ergebnis der Obduktion des Gorilla *Bobby*, des Zoologischen Gartens zu Berlin. Ein Beitrag zur Vergleichenden Konstitutionspathologie. *Veröff. Konstit. Wehrpath.* 9(3), p1-36.
101. **Kohlbrügge, JHF** (1890/91): Versuch einer anatomie des Genus *Hylobates*. Muskeln und periphere Nerven. Zoologische Ergebnisse einer Reise in Niederländisch Ost-Indien. 1, p211-354; 2, p138-206. E.J.Brill; Leiden.
102. **Kohlbrügge, JHF** (1892): Versuch einer Anatomie des Genus *Hylobates*. *Zool. Ergeb. einer Reise in Nied. Ost-Indien.* Max Weber, Leiden. 2(2), Urogenital system, p185-186.
103. **Kohlbrügge, JHF** (1897): Muskeln und Periphere Nerven der Primaten, mit besonderer Berücksichtigung ihrer Anomalien. *Verh. K. Akad. Wet.* Amsterdam. Section 2, 5(6), p1-246.



104. **Krause, WJ** (1975): The duodenal glands of fourteen primate species. *Acta. Anat.* 93, p580-589.
105. **Kreilkamp, BL** and **Boyden, EA** (1940): Variability in the composition of the sphincter of Oddi. A possible factor in the pathologic physiology of the biliary tract. *Anat. Rec.* 76, p485-497.
106. **Kubik, W** (1967): The pancreatic ducts in lower primates. *Folia Morphol.* 26, 226-242.
107. **Lake, G; Schneider, W** and **Schneider, U** (1966): Cited in Warwick and Williams (1973).
108. **Lang, EM** (1959): The birth of a gorilla at Basle Zoo. *Int. Zoo Yearb.* 1, p3-7.
109. **Lartschneider, J** (1895): Zur vergleichende Anatomie des Diaphragma pelvis. *Sitzungsber. Kaiserl. Akad. Wiss. Wien, Math. Naturwiss. Kl.* 104, p160-190.
110. **Ljungquist, A** and **Lagergren, C** (1962): Normal intrarenal arterial pattern in adult and aging human kidney. *J. Anat.* 96, p285-300.
111. **Lunn, HF** (1948): The comparative anatomy of the inguinal ligament. *Anat. Phys.* 82, p58-67.
112. **Lunn, HF** (1949): Observations on the mammalian inguinal region. *Proc. Zool. Soc.* 118, p345-355.
113. **Ma, S; Wang, Y** and **Poirier, FE** (1988): Taxonomy, distribution, and status of gibbons (*Hylobates*) in southern China and adjacent areas. *Primates.* 29(2), p277-286.
114. **McClure, CFW** and **Silvester, CF** (1909): A comparative study of the lymphatico-venous communications in adult mammals. I. Primates, Carnivora, Rodentia, Ungulata and Marsupialia. *Anat. Rec.* 3, p534-552.
115. **McKenney, FD; Traum, J** and **Bonestell, AE** (1944): Acute coccidiomycosis in a mountain gorilla (*Gorilla beringei*) with anatomical notes. *J. Am. Vet. Med. Assoc.* 105, p136-140.

116. **Machida, H** and **Giacometti, L** (1967): The anatomical and histochemical properties on the skin of the external genitalia of the primates. *Folia Primatol.* 6, p48-69.
117. **Meehan, T** and **Lowenstine, L** (1997): Causes of mortality in captive lowland gorillas. In: Ogden, J and Wharton, D (eds); The management of gorillas in captivity. Gorilla SSP, Atlanta.
118. **Mijsberg, WA** (1923): Über den Bau des Urogenitalapparates bei den männlichen Primaten. *Verh. K. Akad. Wet. Amsterdam.* 23 (1), p1-92.
119. **Miller, GS Jr** (1933): The classification of gibbons. *J. Mammal.* 14, p158-159.
120. **Miller, RA** (1947): The inguinal canal of primates. *Am. J. Anat.* 76, p67-87.
121. **Miller, RA** (1952): The musculature of *Pan paniscus*. *Am. J. Anat.* 91(2), p182-232.
122. **Mitchell, PC** (1905): On the intestinal tract of mammals. *Trans. Zool. Soc. Lond.* 17, p437-536
123. **Morton, WRM** (1956): A chimpanzee placenta and foetus in situ. *J. Anat.* 91, p605.
124. **Noback, CR** (1939): The changes in the vaginal smears and associated cyclic phenomena in the lowland gorilla (*Gorilla gorilla*). *Anat. Rec.* 73(2), p209-221.
125. **Owen, R** (1830/1): On the anatomy of the orangutan (*Simia satyrus*, L.). *Proc. Zool. Soc. Lond.* 1, p4-5, 9-10, p28-29, 66-72.
126. **Owen, R** (1836): On the morbid appearances observed in the dissection of the chimpanzee (*Simia troglodytes*, Linn.). *Proc. Zool. Soc. Lond.* 4, p41-43.
127. **Owen, R** (1843): Notes of the dissection of a female orang-utan (*Simia satyrus*, Linn.). *Proc. Zool. Soc. Lond.* 11, p123-124.
128. **Owen, R** (1846): Notes on the dissection of a female chimpanzee. *Proc. Zool. Soc. Lond.* 14, p2-3.

129. **Owen, R** (1865): Memoir on the gorilla (*Troglodytes gorilla*, Savage). Taylor and Francis, London.
130. **Pocock, RI** (1925): The external characters of the Catarrhine monkeys and apes. Proc.Zool.Soc.Lond. p1479-1579.
131. **Pohl, L** (1928): Zur Morphologie der männlichen Kopulationsorgane der Säugetiere; insbesondere der Versuch einer vergleichend-anatomischen Studie über den Penis der Primaten, einschliesslich des Menschen. Z.Anat.Entwicklungsgesch. 86, p71-119.
132. **Popowsky, J** (1895): Das Arteriensystem der unteren Extremitäten bei den Primaten. Anat.Anz. 10, p55-80, 99-114.
133. **de Pousargues, E** (1895): Note sur l'appareil génital male des orang-outans. Nouv.Arch.Mus.Natl.Hist.Nat.(Paris). 7, p56-82.
134. **Prejzner-Morawska, A** (1971): The sacral portion of the sympathetic trunk in lower catarrhine monkeys and anthropoid apes. Folia Morphol. 30, p188-197.
135. **Rasmussen, AT** and **Rasmussen, T** (1952): The hypophysis cerebri of Bushman, the gorilla of Lincoln Park Zoo, Chicago. Anat.Rec. 113(3), p325-347.
136. **Raven, HC** (1950): Regional anatomy of the Gorilla. In: Gregory, WK(ed); The anatomy of the Gorilla. Columbia University Press, New York; p 15-188.
137. **Reider, N** (1936): The primate colon. Proc.Zool.Soc.Lond. p433-453.
138. **Rijksen, HD** (1978): A field study on Sumatran orang utans (*Pongo pygmaeus abelii* Lesson 1827): ecology, behaviour and conservation. H.Veenman and Zonen, Wageningen, Netherlands.
139. **Roberts, JA** and **Seibold, HR** (1971): The histology of the primate urethra. Folia Primatol. 14, p59-69.
140. **Sâglik, S** (1938): Ovaries of gorilla, chimpanzee, orang-utan and gibbon. Carnegie Inst.Wash.Pub. Contrib.Embryol. 27, p179-189.
141. **Savage-Rumbaugh, ES** and **Wilkerson, BJ** (1978): Socio-sexual behaviour in *Pan paniscus* and *Pan troglodytes*. A comparative study. J.Hum.Evol. 7, p327-344.

142. **Schultz, AH** (1927): Studies on the growth of the gorilla and of other higher primates, with special reference to a fetus of gorilla preserved in the Carnegie Museum. Mem. Carneg. Mus. 11, p1-86.
143. **Schultz, AH** (1936): Characters common to higher primates and characters specific for man. Q. Rev. Biol. 11(3), p259-283, p425-455.
144. **Schultz, AH** (1938): The relative weight of the testes in primates. Anat. Rec. 72, p387-394.
145. **Scott, GBD** (1980): The primate caecum and appendix vermiformis: a comparative study. J. Anat. 131, p549-563.
146. **Selenka, E** (1903): Studien über Entwicklungsgeschichte, Heft 10. Menschenaffen, Entwicklung des Gibbon (*Hylobates* und *Siamanga*). Zur vergleichenden Keimgeschichte der Primaten, p163-201.
147. **Short, RV** (1981): Sexual selection in man and great apes. In: Graham, CE (ed); Reproductive biology of the great apes: comparative and biomedical perspectives. Academic Press, New York; p319-341.
148. **Short, RV** (1984): Testis size, ovulation rate, and breast cancer. In: Ryder, OA and Byrd, MI (eds); One Medicine. Springer-Verlag, Berlin; p32-44.
149. **Sigmon, BA** (1974): A functional analysis of pongid hip and thigh musculature. J. Hum. Evol. 3, p161-185.
150. **Sinzinger, H; Unterberger, H and Reisinger, L** (1973): Länge, Verlauf und Hilusaufzweigung der Arteria lienalis bei Primaten. Acta Morphol. Neerl-Scand. 11, p13-29.
151. **Smith, WC** (1923): The levator ani muscle; its structure in man, and its comparative relationships. Anat. Rec. 26(3), p175-204.
152. **Sonntag, CF** (1923): On the anatomy, physiology, and pathology of the chimpanzee. Proc. Zool. Soc. Lond. 23, p323-429.
153. **Sonntag, CF** (1924): On the anatomy, physiology, and pathology of the orang-utan. Proc. Zool. Soc. Lond. 24, p349-450.

154. **Sonntag, CF** (1924b): The morphology and evolution of the apes and man. John Bale Sons and Danielsson, Ltd, London.
155. **Sperino, G** (1897): Anatomia del cimpanzè (*Anthropopithecus troglodytes*). Unione Tipografica, Torino.
156. **Steiner, PE** (1954): Anatomical observations in a *Gorilla gorilla*. Am.J.Phys.Anthropol. 12, p145-165.
157. **Stinson, JM** (1971): Intrarenal arterial patterns in nonhuman primates. Folia Primatol. 14(1), p70-9.
158. **Straus, WL Jr** (1934): The structure of the primate kidney. J.Anat.Phys. 69, p93-108.
159. **Straus, WL Jr** (1936): The thoracic and abdominal viscera of primates with special reference to the orang-utan. Proc.Am.Phil.Soc. 76, p1-85.
160. **Straus, WL** (1937): The visceral anatomy of an infant chimpanzee. J.Mammal. 18, p501-507.
161. **Swan, KG; Spees, EK; Reynolds, DG; Kerr, JC and Zinner, MJ** (1978): Microvascular architecture of anthropoid primate intestine. Circ.Shock 5(4), p375-382.
162. **Swindler, DR. and Wood, CD** (1973): An atlas of primate gross anatomy; baboon, chimpanzee, and man. University of Washington Press, Seattle.
163. **Symington, J** (1890): On the viscera of a female chimpanzee. Proc.Roy.Phys.Soc.Edinb. 10, p297-312.
164. **Thomas, WD** (1958): Observations on the breeding in captivity of a pair of lowland gorillas. Zoologica N.Y. 43, p95-104.
165. **Thompson, P** (1901): On the arrangement of the fasciae of the pelvis and their relationship to the levator ani. J.Anat.Phys. 35, p127-141.
166. **Underhill, BML** (1955): Intestinal length in man. Brit.Med.J. 2, p1243-1246.
167. **Vallois, HV** (1929): Les preuves anatomiques de l'origine monophyletique de l'homme. Anthropologie. 39, p77-101.

168. **Vrolik, W** (1841): Recherches d'anatomie comparée, sur le chimpanzé. Johannes Miller, Amsterdam.
169. **Walmsley, R** (1937): The sheath of the rectus abdominis. *J. Anat. Phys.* 77, p404-414.
170. **Warwick, P** and **Williams, PL** (1973): Gray's Anatomy. 35th British Edition. Saunders Co., Philadelphia.
171. **Waterman, HC** (1929): Studies on the evolution of the pelvis of man and other primates. *Bull. Am. Mus. Nat. Hist.* 55, p585-642.
172. **Weber, M** (1904): Die Säugetiere. Einführung in die Anatomie und Systematik der Recenten und Fossilen Mammalia. Jena.
173. **Weinberg, M** (1904): Un cas d'appendicite chez le chimpanzé. *Ann. Inst. Pasteur, Paris.* 18, p323-331.
174. **Weinberg, M** (1906): Appendicitis et vers intestinaux chez le chimpanzee. *CR. Séances Soc. Biol (Paris).* 60, p661-662.
175. **Weinberg, M** (1908): Un cas d'appendicite chez le gorilla. *Bull. Soc. Pathol. Exot.* 1, p556-560.
176. **Weinert, H** (1932): Ursprung der Menschheit. Über den engeren Anschluss des Menschengeschlechts an die Menschenaffen. Stuttgart. 380pp. In <sup>143</sup>
177. **Welch, FD** (1911): Observations on different gibbons of the genus *Hylobates* now or recently living in the Society's Gardens, and on *Symphalangus syndactylus*, with notes on skins in the Natural History Museum, S. Kensington. *Proc. Zool. Soc. Lond.* p353-358.
178. **Wendell-Smith, CP** (1962): Adaptations of anal musculature. *J. Anat.* 97, p489.
179. **Winckler, G** (1950): Contribution a l'étude des muscles larges de la paroi abdominale. Étude d'anatomie comparée. *Arch. Anat. Histol. Embryol.* 33, p157-228.
180. **Wislocki, GB** (1932): On the female reproductive tract of the gorilla with a comparison with that of other primates. *Cont. Embryol. Carneg. Inst.* 23, p163-204.

181. **Wislocki,GB** (1933): Observations on the descent of the testes in the Macaque and in the chimpanzee. *Anat.Rec.* 57, p133-148.
182. **Wislocki,GB** (1936): The external genitalia of the simian primates. *Human Biol.* 8, p309-347.
183. **Wood-Jones,F** (1929): Man's place among the mammals. Longman, Green and Co., London.
184. **Young,WC** (1944): Genital cycles following incomplete oöphorectomy in the chimpanzee. *Anat.Rec.* 89(4), p475-493.
185. **Zuckerman,S** and **Fulton,JF** (1934): The menstrual cycle of the primates - VII. The sexual skin of the chimpanzee. *J.Anat.* 69, p38-46.
186. **Zuckerman,S** and **Parkes,AS** (1935): Observations on the structure of the uterus masculinus in various primates. *J.Anat.Phys.* 69, p484-496.

## 3.7 LOWER LIMB

### 3.7.1 MUSCLES

#### 3.7.1.1 Gluteal region

##### 3.7.1.1.1 Superficial

###### *Gluteus maximus*

In all apes and *Homo* gluteus maximus originates from the posterior iliac crest, thoracolumbar fascia, sacrum, coccyx, the sacrotuberal ligament and the fascia over gluteus medius<sup>3, 7, 8, 11, 12, 36, 39, 51, 67, 72, 76, 86, 87, 88, 97, 102, 103, 115</sup>. In all apes there is an origin from the ischial tuberosity<sup>3, 7, 11, 12, 22, 36, 39, 67, 87, 88, 97, 102, 103, 122</sup>, which may occur as a variation in *Homo*<sup>115</sup>. In *Homo*, *Gorilla* and *Hylobates* it also originates from the posterior superior iliac spine<sup>103, 115</sup>, and in African apes and *Hylobates* the muscle shares its origin with the long head of biceps femoris<sup>12, 103</sup>, while in *Pongo* it may fuse with biceps more distally<sup>102</sup>. In *Gorilla* it may originate from the intermuscular septum<sup>87</sup>, and in *Pongo* from the sacrospinous ligament<sup>97, 102</sup>.

A thin, flat muscle, with the proximal portion thinner than the distal portion in all apes<sup>39, 77, 97, 102, 122</sup>, it is a much larger muscle in *Homo* with the proximal portion equal to, or thicker than, the distal portion<sup>97</sup>. The gluteus maximus is usually continuous in all taxa, but it may be separated into two parts in apes<sup>11, 12, 39, 102</sup>, and into as many as three parts in *Pan* and *Hylobates*<sup>36</sup>. In *Gorilla* it has been described as multifasciculated<sup>87</sup>. The ischiofemoral head of biceps femoris described in *Pongo* is equivalent to a distal head of gluteus maximus<sup>83, 102, 103</sup>.

In all apes and *Homo* gluteus maximus inserts into the iliotibial tract (when present) and into the posterolateral aspect of the femur in the region of the gluteal tuberosity<sup>1</sup>.



7, 11, 12, 15, 36, 40, 67, 87, 97, 102, 115. In all apes *gluteus maximus* inserts into the aponeurosis of *vastus lateralis*<sup>11, 40, 67, 103</sup>, in all except *Gorilla* into the lateral intermuscular septum<sup>36, 103</sup> and in the great apes into the hypertrochanteric fossa on the lateral aspect of the femur<sup>1</sup>. The insertion of the muscle is generally more distal on the femur in apes than in *Homo*, extending almost to the lateral condyle in African apes<sup>22, 36, 39, 67, 97, 122</sup>, and two-thirds down the femur in *Gorilla*, *Pongo* and *Hylobates*<sup>36, 97, 103</sup>. In *Symphalangus* the insertion extends down the proximal four-fifths of the femoral shaft<sup>97</sup>.

Innervation is via the inferior gluteal nerve in *Homo*, *Gorilla* and *Pongo*<sup>87, 97, 115</sup>.

### *Gluteus medius*

*Gluteus medius* originates from the lateral surface of the ilium and the gluteal fascia in all apes and *Homo*<sup>3, 7, 12, 87, 97, 115</sup>. In *Homo* alone it has a specific origin from the iliac crest<sup>115</sup>. Great apes have an additional origin from the fascia lata<sup>3, 87</sup>, and in *Gorilla* also from the sacroiliac membrane and sacral spines<sup>87</sup>.

*Gluteus medius* is the largest of the gluteal muscles in great apes<sup>7, 12, 15, 77, 97</sup>, but is smaller than *gluteus maximus* in *Homo*<sup>115</sup> and *Hylobates*<sup>97</sup>. The tendon of insertion is split by *vastus lateralis* in *Pan*<sup>12, 39, 102</sup>.

The muscle always fuses with *piriformis* at its insertion in *Pongo* and *Hylobates*<sup>3, 7, 97, 102</sup>, and often fused with this muscle in *Homo* and African apes<sup>12, 22, 39, 97, 115</sup>.

Insertion is into the lateral aspect of the greater trochanter in all apes and *Homo*, extending anteriorly in African apes and *Hylobates*<sup>87, 97</sup>, superiorly in *Gorilla* and *Pongo*<sup>7, 87</sup>, and posteriorly in *Pan*<sup>12</sup>. A deep slip of the muscle may be attached to the superior border of the trochanter in *Homo*<sup>115</sup>.

Innervation is from the superior gluteal nerve in all apes and *Homo*<sup>87, 97, 115</sup>.

### *Gluteus minimus*

In all apes and *Homo* gluteus minimus originates from the dorsolateral surface of the ilium, extending from just distal to the anterior superior iliac spine, towards the acetabulum<sup>7, 12, 15, 87, 97, 102, 115</sup>. In great apes and *Homo*, but not *Hylobates*, the muscle originates from the margin of the greater sciatic notch<sup>3, 97, 115</sup>. In all apes, but not *Homo*, the origin extends to the ischial spine<sup>7, 97</sup>. The origin in great apes, and sometimes in *Homo*<sup>115</sup>, is in two parts<sup>12, 97</sup>, but is continuous in *Homo* and *Hylobates*<sup>97, 115</sup>. There may be fibres of origin from the sacrospinous ligament in *Pongo*<sup>7</sup>.

In all apes and *Homo* the muscle is triangular or fan-shaped<sup>87, 97, 115</sup>, larger in African apes than in Asian apes<sup>39, 102</sup>.

Insertion is into the anterior aspect of the greater trochanter in all apes and *Homo*<sup>12, 39, 97, 102, 115</sup>, extending medially in *Gorilla*<sup>87</sup>, and laterally in *Pongo*<sup>7</sup>. In *Gorilla* there is an insertion into the femoral neck<sup>87</sup>, and in *Homo* and *Pongo* into the capsule of the femoral head<sup>3, 115</sup>.

Innervation in all apes and *Homo* is via the superior gluteal nerve<sup>87, 97, 115</sup>.

### *Scansorius*

Scansorius is always present in *Pongo*<sup>2, 7, 84, 96, 116</sup> and has also been found occasionally in other apes<sup>3, 5, 12, 39, 65, 83, 96, 119</sup>. Scansorius in *Homo* is thought to be represented by a fascicle from the anterior margin of gluteus minimus, inserting onto the anterior border of the greater trochanter<sup>97</sup>.

In *Pan* and *Pongo* it originates from the anterolateral ilium adjacent to the acetabular rim<sup>3,7,22,101</sup>, in *Pongo* extending from the anterior superior iliac spine to the anterior inferior iliac spine<sup>7,97</sup>, while in *Pan* and *Gorilla* it originates from the fascia lata<sup>3,87</sup>.

When present, it is a flat triangular muscle<sup>3,7,87,97,119</sup>. Scansorius is fused with gluteus minimus in all apes except *Pongo*<sup>7,12,22,39,83</sup>, and with gluteus medius in *Gorilla* alone<sup>87</sup>. The rounded tendon of insertion is embraced by the origin of vastus lateralis in *Pongo*<sup>7</sup>, and scansorius is fused with this muscle in *Gorilla*<sup>87</sup>. In *Pongo* scansorius is fused proximally with iliacus<sup>97</sup>.

Insertion is onto the anterior border of the greater trochanter in *Pan* and *Pongo*, distal to that of gluteus minimus<sup>3,7,12,39,77,97,101,119</sup>, and in *Gorilla* onto the ventrolateral femur just distal to the greater trochanter in common with gluteus minimus<sup>83,87</sup>.

Innervation in *Pan* and *Pongo* is via the superior gluteal nerve<sup>7,12,96,97</sup>.

### 3.7.1.1.2 Deep

#### *Superior gemellus*

The superior gemellus is absent from all hylobatids<sup>97</sup>, although in one case a small fasciculus can be raised from obturator internus<sup>39</sup>. It is absent from some specimens of *Pongo*<sup>97</sup> and the majority of *Gorilla*<sup>87,97</sup>, but present in all specimens of *Pan*<sup>3,12,22,39,97</sup>. The muscle is unilaterally, or bilaterally, absent in 8.6 to 14.5% of *Homo*<sup>64,108,120</sup>.

When present, the superior gemellus originates in *Homo* and great apes from the region of the ischial spine<sup>7,12,39,115</sup>, in *Pan* and *Pongo* between the ischial spine and the ischial tuberosity<sup>7,97</sup>.

The inferior is the smaller of the two gemelli in *Pan*<sup>12, 22, 39</sup>, while the superior is the smaller in *Pan* and *Pongo*<sup>7, 39, 77, 102, 115</sup>.

In *Homo*, *Pan* and *Pongo* it has a common insertion onto the trochanteric fossa with the tendon of obturator internus, with which it is fused<sup>3, 7, 12, 97, 102, 115</sup>.

The superior gemellus, when present, is innervated in *Homo* and great apes by sacral nerves via the sacral plexus<sup>12, 97, 115</sup>.

#### *Inferior gemellus*

In all apes and *Homo* the inferior gemellus originates from the region of the ischial tuberosity<sup>7, 12, 39, 87, 115</sup>, just above the tuberosity in all apes<sup>7, 97</sup>.

The muscle is difficult to isolate from quadratus femoris in great apes<sup>39, 87</sup>, and is fused with the capsule of the hip and the ligamentum teres in *Gorilla*<sup>87</sup>.

Close to its insertion in all apes and *Homo* it fuses with the inferior border of obturator internus<sup>7, 39, 97, 115</sup>, and then the two muscles insert into the trochanteric fossa<sup>3, 12, 87, 97, 102, 115</sup>.

In all apes and *Homo* innervation is from the sacral nerves<sup>12, 87, 97</sup>, and from the fifth lumbar nerve in *Homo* alone<sup>115</sup>. In *Pan* the inferior gemellus is supplied by a branch from a single nerve, whereas in *Homo* the inferior gemellus may be innervated by its own nerve<sup>12</sup>.

#### *Obturator externus*

In all apes and *Homo* obturator externus originates from the external surface of the medial bony margin of the obturator foramen and from the obturator membrane<sup>7, 87, 97, 115</sup>.

In all apes and *Homo* it inserts into the trochanteric fossa<sup>7, 39, 87, 97, 102, 115</sup>, in *Pan* and *Hylobates* it is always fused with obturator internus<sup>39</sup> and is usually so fused in *Gorilla* and *Pongo*<sup>3, 39</sup>. In one case of *Gorilla* it inserts into the superior femoral neck<sup>87</sup>, and in *Pan* in one case posterior to the lesser femoral trochanter<sup>3</sup>.

Nerve supply in all apes and *Homo* is via the obturator nerve<sup>87, 97, 115</sup>.

#### *Obturator internus*

In all apes and *Homo* obturator internus originates from the margin of the obturator foramen and the obturator membrane<sup>7, 12, 87, 97, 106, 115</sup>, in all except *Hylobates* extending to the superior part of the descending pubic ramus and the medial surface of the inferior ischial ramus<sup>7, 12, 87, 97, 106, 115</sup>. In *Pan* the origin may extend to the ischial tuberosity and pubic symphysis, and a tendinous arch running across the obturator foramen<sup>12</sup>.

In all apes and *Homo* it is a flat muscle, running through the lesser sciatic foramen<sup>7, 39, 115</sup>. Unlike *Homo*<sup>115</sup>, in apes there are no ridges and grooves where the tendon takes a right-angled turn into the buttock<sup>39</sup>.

The insertion in all apes and *Homo* is common with the gemelli into the trochanteric fossa<sup>3, 7, 12, 87, 97, 115</sup>, anterosuperior to the insertion of obturator externus<sup>39, 102</sup>.

Nerve supply in all apes and *Homo* is via sacral nerves<sup>87, 97, 115</sup>, with additional innervation in *Homo* from the fifth lumbar nerve<sup>115</sup>. The muscle in *Gorilla* may take innervation from the third lumbar nerve<sup>87</sup>.

### *Piriformis*

In all apes and *Homo* piriformis originates by slips from the anterolateral surface of the distal half of the sacrum<sup>7, 12, 39, 97</sup>, extending as far proximally as S2 in great apes and *Homo*<sup>12, 39, 68</sup>; no information for *Hylobates*, and in one specimen of *Gorilla* as far proximally as S1<sup>87</sup>. The distal extent of the origin is to S4 in *Homo*<sup>68</sup>, S5 in African apes<sup>12, 39</sup> and even as far distally as Co1 in a single *Gorilla*<sup>87</sup>; no information for *Pongo* or *Hylobates*. An origin from the margin of the greater sciatic notch is present in great apes and *Homo*<sup>15, 97</sup>, but not in *Hylobates*<sup>97</sup>.

In a single specimen of *Pongo* the sacral portion of the origin is absent, leaving only the greater sciatic notch portion as representative of piriformis<sup>15</sup>. Piriformis may be partially or completely absent in *Homo* as a variant<sup>68</sup>. The muscle is always fused with gluteus medius in *Pongo* and *Hylobates*<sup>3, 7, 97, 102</sup>, and often fused with this muscle in *Homo* and African apes<sup>12, 22, 39, 97, 115</sup>.

Piriformis descends through the greater sciatic foramen to an insertion in all apes and *Homo* at the anteromedial aspect of the tip of the greater femoral trochanter<sup>3, 7, 12, 15, 39, 87, 97, 115</sup>.

Nerve supply is from branches of the sacral plexus in all apes and *Homo*<sup>97, 115</sup>. In a specimen of *Gorilla*, piriformis is described as three digitations separated by sacral nerves<sup>87</sup>, which occurs in *Homo* as a variant<sup>115</sup>.

### *Quadratus femoris*

In great apes and *Homo* quadratus femoris originates from the anterolateral aspect of the ischial tuberosity<sup>3, 7, 22, 72, 97, 102, 115</sup>, although in *Pongo* it may extend medially<sup>7</sup>.

No information for the origin in *Hylobates*.

A small, thick, fleshy muscle in all apes<sup>3, 97</sup>, it is flat in *Homo*<sup>115</sup>. In *Homo* and *Pongo* it is described as quadrilateral<sup>39, 115</sup>. In *Pongo*, *Hylobates* and some specimens of *Pan* there are two parts at insertion<sup>39, 102</sup>. In all apes and *Homo* the muscle is separated from adductor magnus<sup>39</sup>, and in all apes the superior border of the muscle is closely related to the inferior gemellus<sup>39</sup>. Quadratus femoris and adductor magnus may be fused, or quadratus may be absent from *Homo* as variations<sup>115</sup>.

The insertion in all apes and *Homo* is to the intertrochanteric crest<sup>7, 22, 39, 97, 115</sup>. In all apes the insertion extends to the posterior surface of the greater trochanter<sup>39, 102</sup>, and in *Pan* and *Pongo* posterior to the lesser trochanter<sup>12, 22, 39, 102</sup>, fusing with pectineus in one specimen of *Pongo*<sup>102</sup>.

Nerve supply to the muscle in all apes is solely via sacral nerves<sup>97</sup>, while in *Homo* there is an additional supply from the inferior gluteal nerve<sup>115</sup>.

### 3.7.1.2 Thigh

#### 3.7.1.2.1 Anterior femoral

##### *Articularis genu*

*Articularis genu* is present in all apes<sup>39</sup>, but may be absent from *Homo*, *Pan* and *Pongo*<sup>12, 102, 115</sup>. In *Gorilla*, and when present in *Homo*, it is a flat, ribbon-like, muscle lying deep to vastus intermedius, originating from the ventrodistal femur, and inserting on the superior convexity of the synovial membrane of the knee joint<sup>87, 115</sup>.

Supplied by a branch of the femoral nerve in *Homo* and *Gorilla*<sup>87, 115</sup>.

## *Quadriceps femoris*

### *Rectus femoris*

Rectus femoris possesses two heads in *Homo*<sup>115</sup>, 2/3 *Gorilla*<sup>39</sup>, 1/3 *Pan*<sup>22, 39, 114</sup>, 1/5 *Pongo*<sup>7, 39</sup> and no specimen of *Hylobates*<sup>39, 97</sup>. In a single specimen of *Pongo* the single head is divided by a fibrous septum<sup>102</sup>.

The short head, originating from the anterior inferior iliac spine, is usually present in all apes and *Homo*<sup>7, 12, 87, 97, 102, 115</sup>.

The reflected head, when present, originates from the ilium superior to the acetabulum<sup>3, 7, 39, 97, 115</sup>. It is absent from *Hylobates*<sup>97</sup>, sometimes absent from great apes<sup>15, 97</sup> and may be missing from *Homo* as a variant<sup>115</sup>.

In a single specimen of *Pan*, rectus femoris is fused with vastus lateralis<sup>3</sup>.

### *Vastus intermedius*

In all apes and *Homo* vastus intermedius originates from the anterior femoral shaft<sup>87, 97, 115</sup>. In *Homo* the origin extends laterally<sup>115</sup>, and in *Gorilla* medially<sup>87</sup>. The origin in *Gorilla* may include the capsule of the femoral neck<sup>87</sup>. The cranial extension is narrow in all apes<sup>7, 97</sup>.

### *Vastus lateralis*

In all apes and *Homo* vastus lateralis originates from the lateral aspect of the greater femoral trochanter and the distal two-thirds of the lateral femoral shaft, in the region of the lateral lip of the linea aspera<sup>3, 7, 97, 87, 102, 115</sup>. These two origins are continuous in *Hylobates*<sup>97</sup>. Great apes possess a further origin from the iliofemoral ligament<sup>87, 97</sup>.



In *Pan* and *Pongo* the vasti may be fused, forming a single vastus muscle<sup>3, 22, 102</sup>. In *Gorilla* vastus lateralis may be fused with vastus intermedius and scansorius<sup>87</sup>. In *Pan* vastus lateralis splits the tendon of gluteus medius<sup>102</sup>.

### *Vastus medialis*

In all apes and *Homo* vastus medialis originates from the posteromedial femoral shaft, in the region of the linea aspera<sup>3, 7, 12, 87, 97, 102, 115</sup>, more proximally in *Hylobates* than in other apes and *Homo*<sup>97</sup>. In all apes it also takes origin from the iliofemoral ligament<sup>3, 97</sup>, and in *Homo* from the distal part of the intertrochanteric line<sup>115</sup>. In both *Homo* and *Pongo* the muscle attaches to intermuscular septa<sup>102, 115</sup>.

Vastus medialis is fused with the other vasti in great apes<sup>3, 87, 102</sup>, and may be so fused as a variation in *Homo*<sup>115</sup>.

The common insertion of quadriceps femoris is to the superolateral border of the patella in all apes and *Homo*, and then via the patellar tendon, to the tibial tuberosity<sup>3, 7, 39, 87, 102, 115</sup>. In all apes the muscle along with the other vasti contributes to the anterolateral aspect of the knee capsule<sup>39</sup>.

Innervated by the femoral nerve in *Homo*<sup>115</sup> and *Gorilla*<sup>87</sup>.

### *Sartorius*

In all apes and *Homo* sartorius originates from the anterior iliac border<sup>3, 12, 39, 40</sup>, often stated as the region of the anterior superior iliac spine<sup>7, 40, 84, 87, 97, 102, 115</sup>. In *Gorilla*, *Pongo* and *Hylobates* the origin has been noted as the lateral iliac border<sup>87, 97</sup>.

The ribbon-shaped muscle in all apes and *Homo* courses obliquely over the thigh posterior to the medial femoral condyle<sup>3, 7, 14, 39, 97, 115</sup>.

In all apes, the insertion is the medial border of the tibial shaft<sup>3, 7, 39, 87, 97, 102, 115</sup>. An insertion to the crural fascia medial to the tibial tuberosity, as found in *Homo*<sup>115</sup>, was present merely as an extension in a few cases of each hominoid<sup>39, 54</sup>. In all apes and *Homo* the insertion of sartorius is superficial to those of gracilis and semitendinosus<sup>3, 7, 39, 115</sup>, while the level of insertion is more proximal in *Gorilla* than in other apes<sup>39</sup>.  
Innervated by the femoral nerve in all apes and *Homo*<sup>87, 97, 115</sup>.

### *Tensor fasciae latae*

This muscle is present in all taxa except *Pongo*, in the latter of which it is mostly<sup>7, 17, 39, 77, 97, 102</sup>, and diminutive when present<sup>15, 44</sup>. It has been suggested that it may have been replaced functionally by scansorius<sup>97</sup>.

No information on origin in *Pongo*. In all other apes and *Homo* it originates from the region of the anterior superior iliac spine<sup>12, 40, 44, 87, 97, 115</sup>. In apes, and as a variation in *Homo*, it may also originate from the gluteal fascia<sup>44, 97, 115</sup>. In *Pan* the origin is common with sartorius<sup>12</sup>.

The muscle is described as quadrangular in *Gorilla*<sup>87</sup>. The muscle is fused proximally with gluteus maximus in *Gorilla*, *Pongo* and *Hylobates*<sup>39, 97</sup>, but only infrequently in *Homo* and *Pan*<sup>97, 106</sup>. Laterally the muscle is fused with gluteus medius and minimus in African apes and *Hylobates*<sup>12, 97</sup>.

In all apes and *Homo* the insertion is into the iliotibial tract<sup>15, 21, 39, 44, 87, 97, 115</sup>.

Nerve supply is from the superior gluteal nerve in *Homo* and African apes<sup>83, 87, 97, 115</sup>, while the inferior gluteal nerve is cited as the nerve supply in *Pan paniscus*<sup>73</sup>. In *Hylobates*, the mediodorsal part of tensor fasciae latae is innervated by the superior gluteal nerve, the anterolateral part being innervated by the femoral nerve<sup>97</sup>.

### 3.7.1.2.2 Medial femoral

#### *Adductor brevis*

In all apes and *Homo* adductor brevis originates from the body of the pubis<sup>3, 22, 39, 97, 115</sup>, and solely from this origin when present in *Hylobates*<sup>39</sup>. In great apes and *Homo* it also originates from the inferior pubic ramus near the symphysis<sup>3, 87, 102, 115</sup>. This origin is single in *Homo* and *Hylobates*<sup>39</sup>, but in two parts in great apes<sup>39</sup>. In great apes alone there may be fibres of origin from the superior pubic ramus<sup>7, 97</sup>. In a single *Pan* adductor brevis has a secondary origin from the ischium and intermuscular septa<sup>3</sup>. In all apes and *Homo* the origin of adductor brevis lies between those of gracilis and obturator externus<sup>39, 97, 115</sup>, and in *Homo*, *Pan* and *Pongo* anterior to, or distal to the origin of adductor magnus<sup>3</sup>.

The division into two parts is present as a variation in *Homo*<sup>115</sup>, *Pan*<sup>3, 12, 39, 102</sup> and *Pongo*<sup>7, 39</sup> and a third of *Gorilla*<sup>97</sup>, but is absent from *Hylobates*<sup>39</sup>. Adductor brevis is partly fused with the short head of adductor magnus in all apes<sup>39, 87, 97</sup>, and also anteriorly with adductor longus in *Gorilla*<sup>87</sup>. Sigmon states that adductor brevis is completely fused with adductor magnus in *Hylobates*<sup>97</sup>, and this may occur as a variation in *Homo*<sup>115</sup>. In a single *Pan* the adductor muscles are described as being indistinguishable from each other, forming an "adductor mass"<sup>22</sup>.

Insertion of the muscle in *Homo* and African apes is distal to the lesser trochanter into the superior third of the medial lip of the linea aspera on the mid-dorsal femoral surface, onto the pectineal line<sup>1, 3, 7, 12, 22, 39, 87, 97</sup>. In great apes and *Homo* the insertion lies posterolateral to that of pectineus<sup>7, 39, 97, 115</sup>, and overlaps adductor longus in *Homo* and *Gorilla*<sup>39, 87, 115</sup>. It is inserted between pectineus and gluteus

maximus in *Pongo*<sup>3</sup>, and between pectineus and the superior part of adductor magnus in *Homo* and *Hylobates*<sup>39, 115</sup>.

Innervation of adductor brevis in all apes and *Homo* is from the anterior division of the obturator nerve<sup>12, 36, 97, 115</sup>.

#### *Adductor longus*

Adductor longus in all apes and *Homo* originates by a flat tendon from the anterior superior pubic ramus in the region of the pubic tubercle<sup>3, 22, 40, 87, 97, 102, 115</sup>. In a single specimen of *Pan* the adductor muscles are indistinguishable from each other, forming an "adductor mass"<sup>22</sup>. In a single specimen of *Pongo* adductor longus originates from the superior margin of pectineus<sup>7</sup>, otherwise being close to pectineus only in *Gorilla* and *Pongo*<sup>87</sup>. In *Pan* it may take origin also from the intermuscular septum<sup>3</sup>.

The insertion in all apes and *Homo* is to the middle of the medial lip of the linea aspera or mediodorsal femoral shaft<sup>1, 3, 7, 22, 39, 40, 87, 97, 102, 115</sup>, beside and anterior to the proximal half of the insertion of the short head of adductor magnus<sup>3, 97, 115</sup>, inserting more proximally in *Hylobates* than in great apes<sup>1</sup>. In *Pan* there may be an expansion to the medial condyle<sup>40</sup>. The insertion of adductor longus may be fused with adductor magnus in *Homo* and *Pan*<sup>3, 12, 115</sup>, with adductor brevis in *Homo* and *Gorilla*<sup>87, 115</sup>, and with vastus medialis in *Pongo*<sup>3, 102</sup>.

#### *Adductor magnus*

In all apes and *Homo* adductor magnus originates from the anterior surface of the inferior pubic ramus, lateral to the pubic symphysis, and from the inferior ischial ramus as far as the ischial tuberosity<sup>3, 7, 12, 22, 39, 40, 87, 97, 102, 115, 121</sup>. This origin is

continuous in *Pongo* and *Hylobates*<sup>3, 39, 97, 102</sup>, while the muscle divides distally in great apes<sup>3, 7, 12, 22, 87, 97, 102</sup>, 2/3 *Hylobates*<sup>97</sup> and *Homo*<sup>115</sup> into two parts distally, remaining joined until insertion in *Symphalangus* and 1/3 *Hylobates*<sup>97</sup>. In *Pan* and *Hylobates* adductor longus is described as fasciculated<sup>3, 12, 39, 102</sup>. In all apes, but not in *Homo*, adductor magnus may take origin from the inferomedial border of semitendinosus and the long head of biceps<sup>97</sup>.

The insertion in all apes and *Homo* is into the medial lip of the linea aspera or the posteromedial surface of the femur, and to the adductor tubercle of the medial epicondyle<sup>3, 7, 12, 22, 39, 40, 87, 97, 102, 115</sup>. The short head in African apes attaches also to the lateral border of the common tendon of insertion of adductor longus and adductor brevis<sup>3, 12, 87</sup><sup>115</sup>. In *Pongo* and *Hylobates* the attachment to the linea aspera runs upwards to the inferior border of the insertion of quadratus femoris<sup>39</sup>, while in *Pongo* alone there is an additional insertion to a curved line from the mid-point of the intertrochanteric line to the intertrochanteric surface of the lesser trochanter<sup>7</sup>.

Innervation of the short head of adductor magnus is via the obturator nerve in all apes and *Homo*<sup>12, 39, 87, 97, 105, 115</sup>. The long head is innervated by the tibial nerve in *Homo* and 1/2 *Gorilla*<sup>87, 115</sup>. In all other apes the long head is innervated by the flexores femoris nerve<sup>97</sup>, with the exception of two specimens of *Pan* in which the long head is innervated by the sciatic nerve<sup>12, 39</sup>, and two specimens of *Pongo* where the nerve supply is derived respectively also from the nerve to quadratus femoris, and the nerve to the hamstrings<sup>7</sup>. The flexores femoris nerve does not exist in *Homo*, and the tibial nerve in apes (except in a single *Gorilla*) does not supply adductor magnus<sup>97</sup>.

### *Adductor minimus*

Adductor minimus is absent from *Hylobates*<sup>97</sup>, although the adherence of adductor brevis to adductor magnus may represent a stage in its differentiation as an independent structure<sup>39</sup>. It is absent from a third of great apes<sup>39, 97</sup>.

When present it originates from the inferior pubic ramus<sup>7, 22, 39, 115</sup>, extending to the pubic body in *Gorilla*<sup>87</sup>.

Usually described as an superior subdivision of adductor magnus, it has been described in great apes as a deep slip of adductor brevis<sup>39</sup>, or as the most inferior of the accessory adductor muscles<sup>1</sup>.

The insertion in great apes and *Homo* is into the linea aspera on the posterior femoral shaft<sup>39, 115</sup>, or in great apes as a muscular insertion onto the lateral lip of the accessory adductor groove<sup>1</sup>. In *Pongo* the muscle may be in two parts, with an associated additional insertion around the insertion of quadratus femoris; it fuses with this muscle on the left side only<sup>7</sup>.

### *Gracilis*

In all apes and *Homo* gracilis originates from the inferior pubic ramus near to the pubic symphysis, slightly onto the ischial ramus<sup>3, 7, 12, 39, 87, 97, 102, 115</sup>. This origin extends to the whole pubic body in African apes and *Hylobates*<sup>39</sup>, and onto the superior pubic ramus in great apes<sup>7, 88, 102</sup>. The origin may be fused with adductor longus in *Pan*<sup>12</sup>.

A strap-like muscle in all taxa, it is wide and flat in great apes<sup>7, 12, 87, 97, 105</sup>, and slender in *Homo* and *Hylobates*<sup>97, 115</sup>.

In all apes and *Homo* the insertion of the muscle is to the anteromedial surface of the tibia<sup>7, 12, 39, 40, 84, 87, 97, 102, 115</sup>, and in all apes there is an aponeurotic expansion to the fascia of the leg<sup>7, 12, 22, 39, 102, 115</sup>. This insertion in all apes and *Homo* is between those of sartorius and semitendinosus, mediodistal to sartorius, and lateroproximal to semitendinosus<sup>3, 7, 12, 39, 77, 97, 102, 115</sup>. The insertion is more proximal in *Gorilla* than in the other apes<sup>39</sup>, and in *Homo* and *Pan* the insertion may be adherent to sartorius<sup>39, 102, 115</sup>.

Innervation in all apes and *Homo* is via the anterior branch of the obturator nerve<sup>87, 97, 115</sup>.

### *Pectineus*

In all apes and *Homo* pectineus originates from the superior pubic ramus<sup>7, 39, 87, 97, 102, 115</sup>.

It passes superiorly to adductor longus in *Homo*, African apes and most *Pongo*<sup>3, 97, 115</sup>, in the latter of which the two muscles may be partially fused<sup>97</sup>. The muscle is described as bilaminar in some specimens of *Pan*<sup>65</sup>, and may have two heads as a variation in *Homo*<sup>109, 115</sup>.

In all apes and *Homo* the muscle inserts onto the dorsal femur just distal to the lesser trochanter<sup>3, 7, 39, 87, 97, 102, 115</sup>, in *Homo* inserting onto the proximal part of the linea aspera<sup>115</sup>. The groove at insertion is well-marked in *Gorilla* and *Hylobates*, and less so in *Pan* and *Pongo*<sup>1</sup>.

Pectineus is supplied in all apes and *Homo* by the femoral nerve<sup>7, 12, 87, 97, 115</sup>, and in occasional specimens of *Pan* and *Pongo*, but not in *Gorilla*<sup>87</sup>, also from the anterior branch of the obturator nerve<sup>7, 12, 97</sup>. This occurs as a variant in *Homo*<sup>115</sup>.

### 3.7.1.2.3 Posterior femoral

#### *Biceps femoris*

The long head of biceps femoris in all apes and *Homo* originates from the ischial tuberosity in common with semitendinosus<sup>3, 7, 12, 36, 53, 77, 87, 97, 102, 82, 115</sup>. In great apes, it also arises in common with semimembranosus<sup>3, 12, 87</sup>. In all taxa except *Homo* the origin is common with gluteus maximus<sup>12, 97, 102, 103</sup>, in *Pan* with the posterior part of gracilis<sup>12</sup>, and in *Pongo* with quadratus femoris<sup>3</sup>.

The short head of biceps femoris originates in all apes and *Homo* from the posterolateral femur in the region of the lateral lip of the linea aspera<sup>3, 36, 53, 77, 97, 102, 82, 87, 115</sup>, extending more distally in great apes than in *Hylobates* and *Homo*<sup>26, 97</sup>. In *Homo*, *Pan* and *Hylobates* it also takes origin from the lateral intermuscular septum<sup>3, 36, 82, 115</sup>.

The short head may be absent as a variant in *Homo*<sup>115</sup> and is absent from a single specimen of *Pan*<sup>105</sup>. The two heads of the muscle are fused in *Homo*<sup>115</sup>, 21/26 *Pan*<sup>3, 12, 39, 82, 90, 97, 102</sup>, 1/4 *Gorilla*<sup>39</sup>, 4/9 *Pongo*<sup>3, 7, 39, 82</sup>, and 7/9 hylobatids<sup>39, 53, 82, 97</sup>, often close to the insertion in all apes and *Homo*<sup>3, 7, 36, 39, 53, 82, 97, 115</sup>.

The insertion of the long head of biceps femoris in all apes is to the tibial head<sup>39, 82, 87, 97</sup>, and to the tibial tuberosity, or condyle, in all taxa, including *Homo*<sup>7, 12, 22, 44, 45, 82, 97, 99, 101, 102, 115</sup>. In all taxa except *Gorilla*<sup>87</sup> it inserts into the fibular head and fascia of the leg<sup>3, 7, 12, 22, 36, 53, 77, 82, 87, 97, 115</sup>. In great apes it may insert into the iliotibial tract<sup>3, 36, 87, 97</sup>. In *Pongo* and *Hylobates* this head may also insert into the capsule of the knee joint<sup>39, 82</sup>, and in *Pongo* alone to the distal femur and intermuscular septum<sup>7, 17, 82, 97, 102</sup>. The long head may be bipartite in *Pongo*<sup>97</sup>, in



which case the part inserting onto the distal femoral surface has been named the "ischiofemoralis"<sup>82</sup>.

The short head in *Homo*<sup>115</sup>, and in all apes except *Symphalangus*<sup>82</sup> inserts onto the fibular head and fascia of the leg<sup>3, 7, 12, 22, 36, 39, 53, 77, 82, 87, 97, 102</sup>. In *Pongo* and *Hylobates* it inserts onto the tibial tuberosity<sup>7, 82, 97</sup>, and in *Pan* and *Pongo* onto the lateral intermuscular septum<sup>7, 82</sup>.

Innervation of the long head of biceps femoris is via the flexores femoris nerve in all apes<sup>12, 97</sup>, except in 1/2 *Gorilla*<sup>87</sup> in which it is innervated by the tibial nerve, as in *Homo*<sup>115</sup>. Innervation of the short head is via the common peroneal nerve in all apes and *Homo*<sup>12, 87, 97, 115</sup>.

#### *Semimembranosus*

In all apes and *Homo* semimembranosus has a long, flat, ribbon-like origin from the ischial tuberosity, inferior and lateral to semitendinosus<sup>7, 12, 87, 97, 115</sup>. In some *Pan*<sup>3, 12</sup> and a single *Pongo* these two muscles are fused at origin<sup>3</sup>, a variant that occurs in *Homo*<sup>115</sup>.

The muscle is larger than the long head of biceps and semitendinosus in *Homo*<sup>115</sup>, but smaller than semitendinosus and equal to the long head of biceps femoris in *Pan*<sup>12</sup>, and is described as fleshier in African apes than in *Homo*<sup>12, 13</sup>. As variations in *Homo*, the entire muscle may be absent or doubled, or the insertion into the knee joint capsule may be absent<sup>115</sup>.

The tendon of insertion is rounded in all apes and *Homo*<sup>7, 12, 39, 115</sup>. The insertion is to the posterior surface of the medial tibial condyle in all apes and *Homo*<sup>3, 7, 12, 97, 102, 115</sup>.

with additional insertions to the popliteal fascia, and the posterior wall of the knee capsule via the oblique popliteal ligament only in *Homo* and *Gorilla*<sup>39, 115</sup>.

Innervation is via the tibial nerve in *Homo* and 1/2 *Gorilla*<sup>87, 115</sup>, while in all other apes, including 1/2 *Gorilla*, the source of innervation is given as the flexores femoris nerve, which does not exist in *Homo*<sup>97</sup>.

### *Semitendinosus*

In all apes and *Homo* semitendinosus originates from the ischial tuberosity in common with the long head of biceps femoris<sup>7, 12, 39, 77, 87, 97, 102, 115</sup>. In some specimens of *Pan* and *Pongo* the origin is also common with semimembranosus<sup>3, 12, 39, 77, 97, 102</sup>, this variant is not present in *Gorilla* or *Hylobates*<sup>97</sup>, but may be present in *Homo*<sup>115</sup>.

An oblique tendinous intersection in the muscle belly of semitendinosus, present as a variation in *Homo*<sup>115</sup>, is occasionally present in all apes except *Gorilla*<sup>39, 65</sup>. The muscle is described as fleshy in great apes<sup>3, 13, 14</sup>.

The insertion is by a narrow, flat tendon in all apes<sup>3, 12, 77, 87</sup>, rounded in *Homo*<sup>115</sup>, to the medial tibial surface just distal to the tibial tuberosity<sup>7, 12, 39, 40, 77, 97, 115</sup>, extending further distally in *Pan*, *Pongo* and *Hylobates* than in *Homo* and *Gorilla*<sup>12, 39, 77</sup>. In some specimens of great ape and *Homo* there is, in addition, an aponeurotic expansion to the fascia of the leg in this region<sup>7, 12, 40, 77, 87, 102, 115</sup>. The insertion is distal to that of gracilis in all apes and *Homo*<sup>3, 39, 97, 115</sup>, although in some specimens of *Pongo* and *Hylobates* the insertion is medial to (both species)<sup>7, 97</sup>, or above (*Pongo*)<sup>3</sup> that of gracilis.

Innervation is from the tibial nerve in *Homo*<sup>115</sup> and 1/2 *Gorilla*<sup>87</sup>, while in all other apes and the second *Gorilla* innervation is via the flexores femoris nerve<sup>12, 97</sup>, which does not exist in *Homo*<sup>97</sup>.

### 3.7.1.3 Leg

#### 3.7.1.3.1 Anterior crural

##### *Extensor digitorum longus*

In all apes and *Homo* extensor digitorum longus originates from the head and medial crest of the fibula, and from the intermuscular septum<sup>3, 7, 61, 67, 73, 87, 102, 115</sup>. In all taxa except *Gorilla*, there is also an origin from the lateral tibial condyle<sup>3, 7, 44, 61, 67, 73, 115</sup>, and in great apes and *Homo* there is an additional origin from the interosseous membrane<sup>3, 44, 67, 87, 115</sup>. In *Homo* and *Pan* there is also an origin from the crural fascia<sup>3, 44, 115</sup>.

In all taxa the muscle inserts into the dorsal aponeurosis of digits II to V<sup>3, 7, 39, 61, 67, 73, 87, 102, 115</sup>. However, in *Pongo* the slip to digit II is reported as absent in two cases<sup>3, 77</sup>, and in *Pan* this slip has been noted as small<sup>3</sup>.

Innervated by branches of the deep peroneal nerve in *Homo*, *Pan paniscus* and *Gorilla*<sup>73, 87, 115</sup>.

##### *Extensor hallucis longus*

In all apes and *Homo* extensor hallucis longus originates from the medial surface of the fibula<sup>3, 61, 73, 87, 102, 115</sup>. In *Homo* and great apes there is an additional origin from the interosseous membrane<sup>3, 7, 61, 73, 87, 115</sup>, while in *Pan* and *Hylobates* there is a

further origin from the lateral tibial condyle<sup>61</sup>. In *Pan* it also originates from the crural fascia and intermuscular septa<sup>3</sup>.

In all apes and *Homo* the tendon of extensor hallucis longus passes along the shaft of MI<sup>3, 7, 39, 87, 115</sup> to the dorsal aponeurosis of the hallux<sup>73</sup>, and inserts into the terminal phalanx of the hallux<sup>3, 7, 61, 73, 77, 87, 102, 115</sup>. In *Pan paniscus*, *Gorilla*, and usually in *Homo*, the insertion is also onto the first phalanx<sup>73, 87, 115</sup>.

Innervated by branches of the deep portion of the peroneal nerve in *Homo*, *Pan paniscus* and *Gorilla*<sup>73, 87, 115</sup>.

#### *Peroneus tertius*

*Peroneus tertius* is present in 95% of *Homo*<sup>48, 50</sup> as an additional tendon attached to the base of MV and sometimes also to the base of MIV, with a separate origin from the distal third of the anterior edge of the fibula<sup>115</sup>.

It is reported as being present in 5% of *Pan*<sup>38, 64, 74, 89</sup>, 30% of *Gorilla*<sup>24, 48, 50, 74, 100</sup>, in 1/2 *Hylobates*<sup>43</sup>, but is absent from *Pongo*<sup>3, 7, 15, 39, 42, 77, 102</sup>  
<sup>24, 38, 43, 49, 50, 64, 74</sup>  
<sup>89, 100</sup>

When present in *Gorilla*, it has a fascial insertion to MV<sup>75</sup>.

#### *Tibialis anterior*

In all apes and *Homo* *tibialis anterior* originates from the lateral tibia<sup>3, 7, 61, 67, 73, 77, 87, 102, 105, 115</sup>. In great apes and *Homo* there is an additional origin from the interosseous membrane<sup>7, 73, 87, 115</sup>, while *Homo* and *Pongo* share an origin from the crural fascia<sup>3, 7, 115</sup>. *Pongo* may also have a more extensive tibial origin, from the anterior, posterior and medial surfaces<sup>102</sup>, and the origin in this species blends with extensor digitorum longus<sup>102</sup>.

In all apes except *Homo*, the muscle splits into two bellies relatively close to the origin rather than in the terminal portion<sup>3, 7, 12, 14, 15, 18, 39, 40, 61, 66, 67, 71, 73, 80, 87, 100, 102, 105, 114</sup>, although duplication of the muscle belly occurs occasionally in *Homo*<sup>56, 61</sup>.

All apes and *Homo* show an insertion into the plantar surface of the medial cuneiform<sup>3, 7, 12, 39, 40, 61, 66, 67, 73, 80, 87, 100, 102, 105, 115</sup>, this insertion being the larger of the two terminations. The insertion to the proximal end of MI is present in all taxa<sup>7, 12, 39, 40, 61, 67, 73, 77, 80, 87, 102, 105, 115</sup>, although in juvenile *Hylobates* the secondary insertion has been given as a cartilaginous "prehallux" in the tarsometatarsal joint<sup>61</sup>. A metatarsal insertion has been described as a separate muscle, abductor hallucis longus<sup>40, 105</sup>.

Innervated by a branch of the deep peroneal nerve in *Homo*, *Pan paniscus* and *Gorilla*<sup>73, 87, 115</sup>.

### 3.7.1.3.2 Lateral crural

#### *Peroneus brevis*

In all taxa except *Hylobates*, peroneus brevis originates from the distolateral fibula and from the intermuscular septa<sup>3, 7, 66, 67, 73, 77, 87, 102, 115</sup>. In *Hylobates* it originates from the anterior region of the fibula<sup>61</sup>, and in *Pongo* is reported to originate also from the anterior and posterior fibular surfaces<sup>77, 102</sup>, and from the fascia of the leg<sup>3</sup>.

The muscle in *Pongo* is fused with extensor digitorum longus and peroneus longus<sup>77, 102</sup>, and connected with flexor hallucis longus<sup>77</sup>.

In all taxa except *Gorilla*<sup>87</sup> the insertion of peroneus brevis is into the tuberosity at the base of MV<sup>3, 7, 12, 22, 39, 61, 67, 73, 77, 102, 115</sup>. In great apes an insertion is reported to the extensor digitorum tendon<sup>3, 12, 39, 40, 67, 87, 102</sup>. *Pan* sometimes has a double

insertion<sup>12</sup>, and *Pongo* has been reported with a triple insertion<sup>39</sup>, the third part inserting into connective tissue<sup>7</sup>. *Pan* has a small tendon to the first and second phalanges of digit V <sup>12, 67, 114</sup> <sup>97</sup> as is occasionally present in *Homo*<sup>67</sup> and *Gorilla*<sup>66, 87</sup>.

Innervated by branches of the superficial peroneal nerve in *Homo*, *Pan paniscus* and *Gorilla*<sup>73, 87, 115</sup>.

### *Peroneus longus*

In all apes and *Homo* peroneus longus originates from the fibular head and proximal fibula<sup>3, 7, 61, 67, 73, 77, 87, 91, 102, 115</sup>. In *Homo*, *Pan* and *Hylobates* it also originates from the lateral tibial condyle<sup>61, 73, 115</sup>, and with the exception of *Hylobates* has an attachment to the intermuscular septa<sup>3, 7, 87, 115</sup>. In *Homo* and *Pongo* there is an additional fascial origin<sup>7</sup>.

In *Pongo* the muscle is fused with peroneus brevis and extensor digitorum longus anteriorly<sup>3, 77, 102</sup>, and connected with flexor hallucis longus<sup>3, 77, 102</sup>.

In all taxa the tendon of peroneus longus runs in a groove on the cuboid bone<sup>7, 61, 115</sup>, and inserts onto the tuberosity of MII<sup>3, 7, 22, 39, 61, 67, 73, 77, 87, 102, 115</sup>. In *Homo* alone the tendon inserts into the medial cuneiform<sup>115</sup>. In *Pan* and *Hylobates* there is a fibrous attachment to MV<sup>61</sup>, which may occur as a variation in *Homo*<sup>115</sup>.

A sesamoid bone in the tendon of peroneus longus is present in 8-9% of *Homo*<sup>69, 78, 115</sup>. A slight thickening, or nodule, has been reported in the great apes<sup>69, 73, 78</sup>, while a small bony sesamoid is present in *Hylobates*<sup>69</sup>.

Innervated by branches of the superficial peroneal nerve in *Homo*, *Pan paniscus* and *Gorilla*<sup>73, 87, 115</sup>.

### 3.7.1.3.3 Posterior crural

#### 3.7.1.3.3.1 Superficial

##### *Gastrocnemius*

In all apes and *Homo* gastrocnemius has two heads and joins with soleus, originating from the medial and lateral femoral condyles and the capsule of the knee joint<sup>3, 7, 29, 39, 73, 87, 102, 112, 115</sup>.

In all apes the calf is relatively flat<sup>39, 67</sup>, and in great apes and *Homo* the muscular fibres of the medial head extend further distally than those of the lateral head<sup>39, 102, 112, 115</sup>. *Pongo* in one case shows a slip separating at the distal third of the tibia<sup>7</sup>. The lateral head in *Pan* connects with the gluteal musculature<sup>40</sup>, in one case fusing with plantaris<sup>3</sup>, and in *Pongo* the lateral head may have a common origin with the long head of flexor hallucis longus<sup>3, 7</sup>.

In all apes and *Homo* it inserts into the calcaneal tuberosity<sup>3, 7, 65, 73, 102, 115</sup>, being fleshy to, or close to, the insertion in the majority of great apes<sup>3, 12, 77, 87, 102, 105, 112, 119</sup>.

A sesamoid bone is present in both heads in *Hylobates*<sup>29, 39</sup>, being absent in all other taxa<sup>12, 29, 77, 87, 112</sup>, except as a variation in *Homo*<sup>115</sup>.

Innervated by branches of the tibial nerve in *Homo*, *Pan paniscus* and *Gorilla*<sup>73, 87, 115</sup>.

##### *Plantaris*

Plantaris is absent from 5-10% of *Homo*<sup>29, 56, 115</sup>. It has not been reported in *Hylobates*<sup>37, 39, 84, 107</sup> and *Gorilla*<sup>13, 19, 21, 37, 39, 84, 87</sup> and is not identified in all<sup>3, 7, 15, 17, 21, 27, 39, 71</sup> except in two cases *Pongo*<sup>84, 93</sup>.

In *Pan* the muscle is absent in two-fifths of all cases<sup>14, 25, 39, 52, 62, 63, 71, 90, 110, 112</sup>, unilaterally present in a fifth of cases<sup>12, 65, 119</sup>, and bilaterally present in two-fifths<sup>3, 19, 22, 29, 37, 40, 41, 67, 73, 105, 112, 114</sup>.

Innervated by a branch of the tibial nerve in *Homo* and *Pan paniscus*<sup>73, 115</sup>.

### *Soleus*

In all apes and *Homo* soleus has an origin from the head and superiodorsal aspect of the fibular shaft<sup>3, 7, 12, 13, 14, 39, 40, 41, 58, 65, 73, 87, 102, 105, 112, 115</sup>, although this origin is

sometimes reported as absent from *Pan*<sup>114</sup>. The tibial origin, which is the primary

origin in *Homo*<sup>59, 112, 115</sup>, is as often absent<sup>12, 14, 66, 67, 71, 112</sup> as present<sup>7, 12, 13, 14, 17, 21, 29, 39, 40, 90, 112, 114, 58, 59, 66, 67, 71, 87</sup>

in *Pan*, is absent, or trivial, in *Gorilla*<sup>13, 21, 87</sup> and absent from *Hylobates*<sup>39, 58</sup> and

*Pongo*<sup>7, 11, 77</sup>,

The tibial head may be included with the lateral part of gastrocnemius in those cases where it is "absent"<sup>71</sup>.

In all apes and *Homo* the insertion is to the calcaneal tuberosity<sup>3, 7, 65, 73, 102, 115</sup>, in the great apes remaining fleshy to, or close to, its insertion<sup>3, 12, 77, 87, 102, 105, 112, 119</sup>.

Innervated by branches of the tibial nerve in *Homo*, *Pan paniscus* and *Gorilla*<sup>73, 87,</sup>

115

### 3.7.1.3.3.2 Deep

#### *Flexor digitorum longus*

*Flexor digitorum longus* in great apes and *Homo* arises from the posterior aspect of the tibial shaft<sup>3, 67, 73, 87, 102, 105, 115</sup>. In *Pongo* the origin is more extensive, from the



anterolateral and medial tibia<sup>3, 7</sup>, and in common with *Homo* from the tibialis posterior fascia<sup>7, 115</sup>. In *Pan* it also arises from the intermuscular septum<sup>3</sup>.

The tendon to digit II in a specimen of *Hylobates* is fused with flexor hallucis longus<sup>39</sup>; this may also occur in great apes and *Homo*<sup>12, 14, 73, 87, 104, 115</sup>. In all apes the muscle may be fused to a lesser or greater degree with flexor digitorum brevis<sup>7, 87, 105</sup>.

The tendon distribution is variable in the apes.

Digit V is supplied in all apes and *Homo*<sup>3, 7, 12, 13, 14, 15, 20, 22, 39, 40, 47, 58, 67, 73, 77, 87, 102, 105, 115</sup>.

Digit IV is supplied in *Homo*<sup>115</sup>, in 4/23 *Pan*<sup>3, 14, 22, 39</sup>, in 3/6 *Gorilla*<sup>13, 20, 39</sup> in 12/22 *Pongo*<sup>7, 15, 39, 47, 77, 102</sup>, and all *Hylobates*<sup>39, 58</sup>, while digit III is supplied in *Homo*<sup>115</sup>, 2/23 *Pan*<sup>39, 47</sup>, 3/6 *Gorilla*<sup>20, 39, 87</sup>, 8/22 *Pongo*<sup>3, 47</sup> and 1/3 *Hylobates*<sup>39</sup>.

The tendon to digit II is present in *Homo*<sup>115</sup>, in 19/23 *Pan*<sup>3, 12, 22, 39, 40, 47, 58, 67, 73, 105</sup>, all *Gorilla*<sup>13, 20, 39, 47, 87</sup>, 15/22 *Pongo*<sup>3, 7, 15, 39, 47, 77, 102</sup> and 2/3 *Hylobates*<sup>58</sup>.

The most common distribution pattern appears to be II and V in *Pan*, either II, III, IV and V, or II, III and V, in *Gorilla* and II, IV and V in *Pongo* and *Hylobates*.

Innervated by a branch of the tibial nerve in *Homo*, *Pan paniscus* and *Gorilla*<sup>73, 87</sup>.

115

#### *Flexor hallucis longus*

Flexor hallucis longus originates from the interosseous membrane and posterior crural intermuscular septum in all apes and *Homo*<sup>3, 7, 67, 73, 87, 115</sup>, and in great apes and *Homo* also from the distoposterior fibula<sup>3, 7, 12, 73, 77, 87, 102, 105, 115</sup>. In one case of *Pan* the fibular origin is noted as the proximal two-thirds<sup>3</sup>. An origin of flexor

hallucis longus from the lateral femoral condyle is frequently present in *Pongo*<sup>3, 7, 39, 77, 102</sup>.

In *Pongo* there are frequently two heads to the muscle - a femoral and a fibular head, the femoral head fusing with gastrocnemius<sup>7, 77, 102</sup>. In *Pongo* in the space usually occupied by flexor hallucis longus there may be a small muscle arising from MI and inserting into the hallucial phalanx<sup>77</sup>.

In all apes and *Homo* the muscle inserts onto the base of the terminal phalanx of the hallux<sup>3, 12, 13, 39, 40, 47, 58, 67, 71, 73, 87, 105, 115</sup>, with the exception of *Pongo*<sup>7, 9, 15, 39, 77, 85</sup>. In *Homo*, insertions to digits II and III occur as a variant, and are rarely present to digit IV<sup>116</sup>. In all apes additional insertions to digits III and IV are present<sup>3, 7, 12, 13, 15, 39, 40, 47, 58, 67, 71, 73, 77, 87, 102, 105</sup>, an insertion to digit II occurring most frequently in *Hylobates*<sup>47</sup>, although present occasionally in *Gorilla*<sup>87</sup>. An insertion onto digit V has been noted in *Hylobates*<sup>47</sup> and *Gorilla*<sup>13</sup>.

Innervated by branches of the tibial nerve in *Homo*, *Pan paniscus* and *Gorilla*<sup>73, 87, 115</sup>.

### *Popliteus*

Popliteus has a lateral femoral condylar head of origin in all apes and *Homo*<sup>3, 7, 39, 73, 87, 102, 115</sup>. In great apes there is a second head of origin, from the fibular head and adjacent capsule in *Pongo*<sup>39</sup>, and from the capsule alone in *Pan* and *Gorilla*<sup>39, 73, 87</sup>. Fibres of popliteus originate from the lateral part of the capsule in *Homo*<sup>115</sup>.

A sesamoid bone in the tendon at the lateral tibial condyle is absent from all<sup>28, 47, 51, 113, 118</sup> except a single *Hylobates*<sup>79</sup>, in all *Pan*<sup>47, 79, 113</sup>, 6/8 *Gorilla*<sup>113, 118</sup> and from all

but exceptional cases of *Homo*<sup>46, 56, 79, 98</sup>. It is present in 2/8 *Gorilla*<sup>47, 66</sup> and 18/21 *Pongo*<sup>7, 28, 30, 57, 77, 79, 113, 118</sup>.

In all apes and *Homo* popliteus inserts into the posterior tibial surface<sup>3, 7, 73, 87, 102, 115</sup>.

Innervated by a branch of the tibial nerve in all apes and *Homo*<sup>39, 73, 87, 115</sup>.

### *Tibialis posterior*

Tibialis posterior in all apes and *Homo* originates from the interosseous membrane and the adjoining sides of the tibia and fibula<sup>3, 7, 73, 87, 115</sup>. In *Homo* and *Pan* it also takes origin from the intermuscular septa<sup>3, 115</sup>.

The sesamoid fibrocartilage in the tendon of tibialis posterior in *Homo*<sup>115</sup> is absent from *Pan* and *Pongo*<sup>12, 77</sup>.

The medial part in all apes and *Homo* inserts into the navicular bone<sup>7, 12, 39, 59, 73, 77, 87, 102, 104, 115</sup>, but the lateral part is more variable. In *Homo*, it inserts in 94% of cases onto the bases of MII-MIV and the cuboid bone<sup>59</sup>. The extended insertion to MII-MIV, but not the cuboid, is present in *Pan* and *Hylobates*<sup>59, 73</sup>, in which there may also be an insertion to the plantar ligaments<sup>3, 39</sup>. In all apes there is an insertion to the sheath of the tendon of peroneus longus<sup>7, 39, 40, 59, 87, 102</sup>, but not in *Homo*. In *Homo* a bursa intervenes between the two muscles<sup>115</sup>. A complete cuneiform insertion is present in *Homo*, *Pan paniscus* and *Pongo*<sup>7, 59, 73, 115</sup>, while in *Gorilla* it is only to the lateral cuneiform<sup>39, 87</sup>, while in *Pan* it can be to the medial<sup>40, 59</sup>, medial and lateral<sup>39</sup> or lateral cuneiforms<sup>12</sup>, but never to all three.

Innervated by a branch of the tibial nerve in *Homo*, *Pan paniscus* and *Gorilla*<sup>73, 87</sup>.

115

### 3.7.1.4 Foot

#### 3.7.1.4.1 Dorsal

##### *Extensor digitorum brevis*

Extensor digitorum brevis is very similar in all apes and *Homo*. The calcaneal origin and division into three tendons for the dorsal aponeuroses of digits II to IV is present in all apes and *Homo*<sup>3, 7, 12, 39, 61, 73, 77, 87, 91, 102, 115</sup>. However, in *Pan*<sup>61, 73</sup> and 1/2 *Hylobates*<sup>61</sup> there is an additional tendon for digit V which merges with peroneus brevis, absent from *Gorilla* and *Pongo*, and only occasionally present in *Homo*<sup>115</sup>.

The insertions of the digital tendons in *Gorilla* are to the second and third phalanges, fused with the tendons of extensor digitorum longus<sup>87</sup>, and in a specimen of *Pongo* there is a double insertion to digit II, one tendon to the proximal phalanx, and a second to the middle and distal phalanges<sup>77</sup>.

##### *Extensor hallucis brevis*

Extensor hallucis brevis is a separate muscle originating from extensor digitorum brevis in all apes and *Homo*<sup>3, 7, 12, 39, 61, 73, 102, 115</sup>. In *Pongo*, and as a variation in *Homo*, there is an additional navicular origin<sup>77, 91, 115</sup>, and in *Gorilla* the muscle takes origin from the calcaneus and the lateral limb of the cruciate ligament<sup>87</sup>.

The muscle in *Pongo* is fused with the tendon of extensor hallucis longus<sup>7</sup>.

In all apes and *Homo* the insertion is to the base of the first phalanx of the hallux<sup>7, 39, 61, 73, 77, 87, 102, 115</sup>. In a single specimen of *Pan* the insertion extends to the second phalanx<sup>22</sup>. *Gorilla* possesses an accessory slip to the first phalanx of digit II<sup>87</sup>, which has been found in *Homo* as a variant<sup>33</sup>.

Both muscles are innervated by the deep branch of the peroneal nerve in *Homo*, *Pan paniscus* and *Gorilla*<sup>73, 87, 115</sup>.

### 3.7.1.4.2 Plantar

#### 3.7.1.4.2.1 Superficial

##### *Abductor digiti minimi*

No information for *Hylobates*.

*Abductor digiti minimi* in great apes and *Homo* originates from the medial and lateral calcaneus<sup>3, 7, 12, 55, 73, 87, 102, 115</sup>, and from the plantar aponeurosis in *Homo*, *Pan* and *Pongo*<sup>3, 7, 12, 115</sup>. In *Pongo* alone there is an origin from the sheath of peroneus longus<sup>102</sup>.

In great apes and *Homo* the insertions are to the proximal phalanx of digit V<sup>3, 12, 73, 87, 102, 115</sup>, and to the base of MV<sup>3, 7, 12, 73, 87, 115</sup>. In *Pan* there may be an additional insertion to the second phalanx<sup>114</sup>, while in *Pongo* there may be a small insertion to the dorsal expansion of the extensor tendons<sup>7</sup>.

Innervated by the lateral plantar nerve in *Homo* and *Pan paniscus*<sup>73, 115</sup>.

##### *Abductor hallucis*

In all apes and *Homo* abductor hallucis originates from the medial and plantar surface of the calcaneus<sup>3, 7, 9, 39, 73, 87, 102, 115</sup>, and from the medial part of the plantar aponeurosis<sup>3, 17, 39, 87, 115</sup>, and in *Pongo* may also originate from the posterior surface of the calcaneus<sup>7</sup>, and in *Gorilla* from the cuboid<sup>87</sup>.

*Gorilla*, *Pongo* and *Hylobates* possess a separate slip (two tendons in *Gorilla*) to the base of MI<sup>9, 17, 39, 87, 102</sup>, which has been named the abductor ossis metacarpi hallucis.

In *Hylobates* there is a sesamoid bone in the tendon of this accessory muscle, and it amalgamates at its insertion with an extension of tibialis anterior<sup>9</sup>. In all apes and *Homo* there is some fusion of abductor hallucis with flexor hallucis brevis<sup>3, 4, 9, 12, 73, 87, 92, 115</sup>. The muscle in *Pan* and *Pongo* is laterally blended with flexor digitorum brevis<sup>12, 102, 105</sup>.

The muscle inserts onto the base of the proximal phalanx of the hallux in all apes and *Homo*<sup>3, 7, 39, 73, 77, 87, 102, 115</sup>. As is occasionally the case in *Homo*<sup>9</sup>, in *Pan* there is sometimes an additional insertion to the medial cuneiform, and in one case to the lateral cuneiform<sup>114</sup>.

Innervated by the medial plantar nerve in all apes and *Homo*<sup>9, 73, 87, 115</sup>.

#### *Abductor os metatarsi digiti minimi*

No information for *Hylobates*.

This muscle has been described in great apes as quite distinct from abductor digiti minimi<sup>14, 73, 84, 87, 105</sup>, and in *Homo* as a variant<sup>115</sup>.

In *Gorilla* it is described as a stout, short, quadrangular muscle on the lateral side of the foot between the plantar aponeurosis lateral and abductor digiti minimi medially. It originates from the lateral process of the calcaneal tuberosity, extending anteriorly to the peroneal trochlear process of the calcaneus<sup>87</sup>.

In *Gorilla* it converges to insert on the peroneal tubercle of MV immediately deep to the insertion of peroneus brevis<sup>87</sup> and is innervated by the lateral plantar nerve<sup>87</sup>.

In *Pongo* it arises from the plantar surface of the calcaneus in common with the lateral part of flexor digitorum brevis, immediately overlying the inner head of

abductor digiti minimi<sup>84</sup>, and inserts into the lateral and plantar aspects of the base of MV<sup>84</sup>.

### *Flexor digitorum brevis*

In all apes and *Homo* flexor digitorum brevis originates from the calcaneus, usually the medial and ventral surfaces<sup>3, 7, 12, 13, 22, 39, 67, 73, 87, 94, 102, 105, 115</sup>, although in *Pongo* the origin is more variable, extending anteriorly, medially or posteriorly<sup>7, 39, 77</sup>. There is an origin from the proximal plantar aponeurosis in *Homo*<sup>115</sup> and *Pan*<sup>12</sup>, and from the plantar aspect of flexor digitorum longus in *Pan*<sup>39, 67, 73, 105</sup>, *Gorilla*<sup>87</sup> and *Hylobates*<sup>39</sup>. The superficial head in *Pongo* may also originate from the distal plantar aponeurosis, calcaneal tendon and medial soleus<sup>7</sup>. The deep head in *Gorilla* may have an origin in the leg<sup>104</sup>.

In all apes and *Homo* the muscle is deep to the central plantar fascia<sup>39, 87, 115</sup>. In *Pan* and *Pongo* the muscle may be fused with abductor hallucis<sup>12, 102, 105</sup>. The tendon to digit V (when present) in *Pongo*, is fused with flexor digitorum longus, and a tendon from the deep head may join the fourth lumbrical muscle proximally<sup>7</sup>.

In all apes and *Homo*, the muscle supplies tendons to digits II and III<sup>3, 7, 12, 13, 14, 15, 22, 37, 39, 67, 73, 77, 85, 87, 94, 102, 105, 115</sup>, providing a tendon to digit IV in all hylobatids and *Homo*<sup>39, 94, 115</sup> and usually doing so in the great apes<sup>3, 7, 12, 22, 39, 67, 73, 85, 87, 94, 105</sup>. When present, the tendon to digit V is derived from a deep head in the apes<sup>7, 39, 67, 85, 87, 94</sup>, and this head occasionally supplies digit IV<sup>39, 94</sup>. When a deep head is present in *Homo* it may supply digit V, or IV and V, even digit III, and the superficial head is often smaller<sup>27, 35, 104, 111, 117</sup>. The deep head in *Hylobates* supplies digits III, IV and

V<sup>39, 94</sup>, although in *Symphalangus* the superficial head may contribute fibres to digit III<sup>95</sup>.

Innervated by the medial plantar branch of the tibial nerve in *Homo*, *Pan paniscus* and *Gorilla*<sup>73, 87, 115</sup>.

#### 3.7.1.4.2.2 Intermediate

##### *Quadratus plantae (flexor accessorius)*

No information for *Hylobates*.

In great apes and *Homo*, a lateral head originates from the lateral margin of the plantar surface of the calcaneus<sup>12, 15, 39, 87, 115</sup>. A medial head is always present in *Homo*<sup>115</sup>, is usually present in *Pongo*<sup>34, 58</sup>, but is absent from African apes<sup>12, 87</sup>.

Insertion is into the common tendon of flexor digitorum longus before the differentiation of flexor hallucis longus in *Homo*, *Pan* and *Gorilla*<sup>12, 39, 87, 115</sup>, with the exception of some specimens of *Pan* in which quadratus plantae is present unilaterally, and did not reach flexor digitorum longus<sup>12, 40</sup>. Insertions into individual tendons of the long flexor to digits II, III or IV are variably present in *Homo*<sup>115</sup>. In *Pongo*, the attachment to flexor digitorum longus has been reported as the tendon to digit V<sup>17</sup>, and in a specimen of *Pan* the insertion is into digital tendons III and IV<sup>22</sup>.

Innervated by the lateral plantar nerve in *Homo* and *Gorilla*<sup>87, 115</sup>.

##### *Lumbricals*

There are four lumbricals in all apes and *Homo*<sup>3, 7, 15, 22, 39, 73, 87, 102, 105, 115</sup>. One author reported seven lumbricals in *Pan*, but counting hallucial heads as separate muscles<sup>40</sup>. Another noted three lumbricals in *Pan*<sup>3</sup>.



The *first lumbrical* always has a single head from the flexor digitorum longus tendon to digit II<sup>3, 7, 12, 15, 22, 39, 73, 102, 105, 115</sup>, although in the specimen of *Pan* with three lumbricals, the first lumbrical is reported as having a double origin, with the additional head arising from the tendon of flexor hallucis longus to digit II<sup>3</sup>.

The *second lumbrical* has a double origin in all apes and *Homo*<sup>3, 7, 12, 15, 22, 39, 40, 73, 102, 105, 115</sup>. In a single *Pongo* the left second lumbrical had a single origin<sup>7</sup>.

The *third lumbrical* has a double origin in *Homo*<sup>115</sup>, African apes<sup>12, 22, 40, 73, 105</sup> and some specimens of *Pongo*<sup>3, 7</sup>. This lumbrical may have a single head in *Pongo*<sup>39, 102</sup>.

The *fourth lumbrical* has a double origin in *Homo*<sup>115</sup>, African apes<sup>3, 12, 22, 40, 73, 105</sup> and some specimens of *Pongo*<sup>84</sup>. In the majority of *Pongo* the fourth lumbrical has a single head of origin<sup>7, 39, 102</sup>.

In all apes and *Homo*, the tendons of the lumbricals radiate into the extensor aponeuroses of their respective digits<sup>7, 73, 87, 105</sup>.

Innervated by the medial plantar nerve to the first lumbrical and the lateral plantar nerve to the second, third and fourth lumbricals in *Homo* and *Gorilla*<sup>87, 115</sup>, and by the medial plantar nerve to the first and second lumbricals, and the lateral plantar nerve to the third and fourth lumbricals in *Pan paniscus*<sup>73</sup>.

### 3.7.1.4.2.3 Deep

#### *Adductor hallucis*

The two heads of adductor hallucis are variably united in *Pan*<sup>9, 12, 22, 14</sup>, separate in *Gorilla*<sup>21, 87</sup> and *Pongo*<sup>7, 84</sup> and always fused in *Hylobates*<sup>8</sup>.

The oblique head in all apes and *Homo* originates from MII and MIII<sup>3, 9, 12, 73, 87, 105, 115</sup>, with an additional origin from MIV in *Homo*, African apes and *Hylobates*<sup>9, 87, 105, 115</sup>. In *Homo*, *Pan* and *Pongo* the head also originates from the sheath of the tendon of peroneus longus<sup>3, 9, 12, 22, 73, 102, 105, 115</sup>. *Pongo* and *Hylobates* have an origin from the interosseous fascia<sup>7, 9</sup>, while *Pan* has been stated to have an origin from the cuboid<sup>114</sup>, *Gorilla* from the ligaments between MII and the intermediate cuneiform<sup>87</sup>, and *Pongo* from a slip between MII to the transverse head<sup>7</sup>.

The oblique head inserts into the base of the proximal phalanx of the hallux in all taxa<sup>9, 74, 105, 115</sup> except *Gorilla*. In all apes the muscle inserts onto MI<sup>3, 7, 9, 12, 87</sup>. In *Pan* and *Hylobates* the tendon extends to the distal phalanx<sup>9</sup>, and in *Homo*, *Pongo* and *Hylobates* inserts onto a sesamoid bone<sup>9, 115</sup>, which in *Pongo* is situated at the combined oblique head/flexor hallucis brevis insertion<sup>3, 9, 92</sup>.

The transverse head of adductor hallucis originates in all apes from MII and MIII<sup>3, 7, 9, 12, 22, 73, 105</sup>. An origin from MIV is present in African apes and *Hylobates*<sup>87, 114, 115, 22, 73, 87, 105</sup>, and an origin from the third and fourth metatarsophalangeal joints and ligaments<sup>114</sup> is present in *Homo*, *Pan* and *Hylobates*<sup>3, 9, 12, 115</sup>. In *Pan* and *Hylobates* there is an origin from the second metatarsophalangeal joint and interosseous fascia<sup>3, 9, 73</sup>, and in *Homo* alone sometimes from the fifth metatarsophalangeal joint and ligaments<sup>115</sup>. *Gorilla* has origins from the deep dorsal fascia and an aponeurotic sheet<sup>87</sup>, while *Pongo* has origins from connective tissue<sup>3, 7</sup> and from a fascial band extending from MII to the third tarsometatarsal joint<sup>9</sup>.

The insertion of the transverse head is to the base of the proximal phalanx in all apes and *Homo*<sup>7, 9, 73, 77, 87, 105, 115</sup>, and to MI in all apes<sup>3, 9, 12, 87</sup>. The combined muscle in *Hylobates* extends to the distal phalanx, sesamoid bone and capsular ligaments<sup>9</sup>. In

*Gorilla* the transverse insertion extends to the capsules of the metatarsophalangeal and interphalangeal joints<sup>87</sup>.

In all apes and *Homo* the muscle is innervated by the deep branch of the lateral plantar nerve<sup>9, 39, 73, 87, 101, 115</sup>, although an additional innervation from the medial plantar nerve has been found in *Pan* and *Pongo*<sup>9, 39, 101, 102</sup>. The same additional innervation occurs rarely in *Homo*<sup>9</sup>.

#### *Flexor digiti minimi*

No information for *Hylobates*.

Flexor digiti minimi in *Homo* and great apes originates from the base of MV<sup>7, 73, 87, 102, 115</sup>, extending dorsomedially in *Pongo*<sup>7</sup>. In *Homo* and *Pongo* it also originates from the sheath of the tendon of peroneus longus<sup>102, 115</sup>. In African apes the origin extends to the plantar interosseous ligaments<sup>87</sup>, and in *Pan* the origin may be shared with opponens digiti minimi and a plantar interosseous muscle<sup>12</sup>. There is an origin from MIV in *Gorilla*<sup>87</sup> and the muscle may originate from the plantar aponeurosis in *Pongo*<sup>7</sup>.

Flexor digiti minimi may be absent from *Pan*<sup>89</sup>.

In *Homo* and great apes the muscle inserts onto the base of the proximal phalanx of digit V<sup>7, 73, 87, 104, 115</sup>.

Innervated by the lateral plantar nerve in *Homo*, *Pan paniscus* and *Gorilla*<sup>73, 87, 115</sup>.

#### *Flexor hallucis brevis*

In all apes and *Homo*, flexor hallucis brevis is double-headed<sup>3, 9, 39, 77, 87, 102, 115</sup>, in great apes and *Homo* (except possibly *Pan*<sup>60</sup>) originating from the intermediate

cuneiform and the tendon of tibialis posterior<sup>7, 60, 87, 114, 115</sup>. In *Homo*, *Pan* and *Pongo* it also originates from the medial and lateral cuneiforms<sup>9, 12, 17, 20, 73, 115</sup>, in African apes, and as a variation in *Homo*, also from the calcaneus<sup>14, 87, 115</sup>, and in African apes and *Pongo* also from the metatarsophalangeal joint<sup>9, 87</sup>. In *Gorilla* and *Pongo* it originates also from the navicular bone<sup>20</sup>. In *Pongo* alone it arises from the plantar fascia<sup>17</sup>, and in *Gorilla* alone from the tarsometatarsal ligament<sup>87</sup>. In *Homo*, and a single *Pan*, an origin is present from the cuboid<sup>3, 115</sup>. No information available for the origin in *Hylobates*.

The lateral head is larger than the medial in all apes<sup>9, 102</sup>, being almost equally-sized in *Pan* and *Hylobates*<sup>9</sup>. In *Gorilla* and *Pongo* the medial and lateral heads are separated by a septum<sup>9, 87, 115</sup> not present in the fused muscles of *Homo* or *Hylobates*<sup>9</sup>.  
<sup>115</sup> The entire muscle is fused with abductor hallucis in *Pan* and *Hylobates*<sup>9, 12, 73</sup>, while only the medial head is fused with the abductor in *Homo*, *Gorilla* and *Pongo*<sup>3</sup>,  
<sup>4, 92, 115</sup>. The lateral head is fused with adductor hallucis in great apes and *Homo*<sup>3, 12, 74, 87, 92, 115</sup>, and with opponens hallucis in *Pongo*<sup>7</sup>.

The insertion in all apes and *Homo* is onto the proximal phalanx of the hallux<sup>3, 7, 9, 12, 14, 17, 73, 77, 87, 115</sup>, while in all taxa<sup>3, 8, 12, 17, 73, 87</sup> except *Homo*<sup>8</sup> there are additional insertions to MI. The muscle is observed in all taxa except *Gorilla* to contain sesamoids<sup>9, 12, 115</sup>.

In all apes and *Homo* the muscle is innervated by the medial plantar nerve<sup>9, 12, 73, 87,</sup>

115

### *Opponens digiti minimi*

No information for *Hylobates*.

Opponens digiti minimi consists of a deep fascicle from the flexor digiti minimi in *Homo*<sup>115</sup>, and as a separate muscle is often absent from *Pongo*<sup>7, 26, 39, 102</sup>. It has been described as present in *Pan* and *Gorilla*<sup>87</sup>. In *Pongo* the muscle is described as comparable to a part of flexor digiti minimi that originates from the plantar aponeurosis<sup>7</sup>.

When present, it originates from the tendon sheath of peroneus longus in *Pan paniscus*<sup>73</sup> and *Pongo*<sup>84</sup>. In *Gorilla* it originates from the base of MIV, and from a sesamoid bone between the bases of MIV and MV<sup>87</sup>, but is medially fused with flexor digiti minimi<sup>87</sup>. In *Pan* it has a common origin from flexor digiti minimi and the plantar interosseous muscle of digit V<sup>12</sup>.

In *Homo* and great apes it inserts into the lateral surface of MV<sup>12, 73, 84, 87</sup>, extending onto the plantar surface in *Pan*<sup>12</sup>.

Innervated by the lateral plantar nerve in *Homo* and *Pan paniscus*<sup>73, 115</sup>.

#### *Opponens hallucis*

Opponens hallucis has been described in detail in apes only in *Pongo*<sup>4, 7, 9, 12, 15, 17, 41, 54, 84, 114, 115</sup>, although it may be present in *Gorilla*<sup>21, 66</sup>, and as a variant in *Hylobates*<sup>4</sup>, *Pan*<sup>12</sup> and *Homo*<sup>9</sup>. In the latter, it may be present as a slip from adductor hallucis attaching to MI<sup>145</sup>.

In *Pongo* it originates from the medial cuneiform<sup>17</sup>, passes beneath abductor hallucis, and is entirely or partially fused with the lateral belly of flexor hallucis brevis<sup>7, 9, 84</sup>.

In a single *Pongo*, where the muscle was two-thirds fused with flexor hallucis brevis<sup>9</sup>, the separate third arose from a cartilaginous nodule in the tendon of tibialis posterior, and had a more dorsal insertion than the fused portion. Some fibres of

adductor hallucis can form a secondary "adductor opponens" which inserts onto MI in *Homo* and *Pongo*<sup>9, 17</sup>.

The insertion in *Pongo* is to the distal, middle third, or entire lateral length, of MI<sup>7, 9, 17, 41, 84</sup>, and to the phalangeal base<sup>7</sup>.

It is innervated by the medial plantar nerve in *Pongo*<sup>9</sup>.

#### *Transversus pedis*

*Transversus pedis* in *Homo* corresponds to the transverse head of adductor hallucis in apes<sup>9, 12, 39</sup>.

#### 3.7.1.4.2.4 Deepest

#### *Dorsal interossei*

The dorsal interossei number four in great apes and *Homo*<sup>7, 40, 73, 102, 115</sup>, with the exception of single specimen of *Pan* that possessed six<sup>22</sup>. Each muscle has two heads of origin, with the exception of the first dorsal interosseous of *Hylobates*<sup>9</sup>, and sometimes the fourth dorsal interosseous of *Pan*<sup>22</sup>. The first dorsal interosseous of *Hylobates* has a single head of origin from the medial side of MII<sup>9</sup>.

The reference line for action in great apes is through digit III, rather than digit II as in *Homo*<sup>7, 12, 21, 105</sup>.

In *Homo* and *Pan* the ~~first dorsal interosseous~~ <sup>medial</sup> originates from the lateral side of MI and the ~~medial~~ <sup>lateral</sup> side of MII<sup>9, 12, 22, 73, 115</sup>, although the hallucial head in *Pan*, *Pongo* and *Hylobates* may be rudimentary or absent<sup>9</sup>. In *Gorilla* and *Pongo* this muscle originates from the medial cuneiform and the medial side of MII<sup>7, 9, 87, 102</sup>. The muscle inserts into the medial aspect of the base of the proximal phalanx of digit II in

African apes and *Homo*<sup>22, 40, 73, 87, 115</sup>; the side of digit II not specified for *Pongo*<sup>7, 77</sup>.

In *Hylobates* the insertion is extended to the ungual phalanx via the extensor aponeurosis<sup>9</sup>.

The *second dorsal interosseous* originates from the lateral side of MII and the medial side of MIII in great apes and *Homo*<sup>7, 22, 73, 87, 115</sup>. No further information available for *Hylobates*. It inserts into the medial side of digit III in African apes<sup>22, 40, 73, 87</sup>; the side of digit III not specified for *Pongo*<sup>7, 9</sup>, but the insertion is into the lateral side of digit II in *Homo*<sup>115</sup>.

The *third dorsal interosseous* originates from the lateral side of MIII and the medial side of MIV in great apes and *Homo*<sup>7, 22, 73, 87, 115</sup>. It inserts into the lateral side of digit III in African apes and *Homo*<sup>22, 40, 73, 87, 115</sup>; the side of digit III not specified for *Pongo*<sup>7, 9</sup>.

The *fourth dorsal interosseous* originates from the lateral side of MIV and medial side of MV in *Homo*<sup>115</sup>, *Gorilla*<sup>87</sup>, *Pongo*<sup>7</sup>, and excluding accessory interossei, in *Pan*<sup>22, 40, 73, 87, 115</sup>. *Gorilla* has a tertiary origin from a sesamoid bone lying ventral to the bases of MIV and MV<sup>87</sup>. It inserts into the lateral aspect of the proximal phalanx of digit IV in African apes and *Homo*<sup>22, 73, 87, 115</sup>; side of digit IV not specified for *Pongo*<sup>7, 9</sup>.

A small first *accessory interosseous* in a specimen of *Pan* lies between the third and fifth dorsal interossei, originating from the dorsal side of MIV, and inserting to the medial side of digit IV. The second accessory interosseous arises with the true fourth dorsal interosseous from the lateral side of MIV and medial side of MV, inserting

into the medial side of digit V. The fourth dorsal and second accessory interossei might be considered as a single muscle with two separate insertions<sup>22</sup>.

The dorsal interossei are innervated by the deep ramus of the lateral plantar nerve in *Homo*, *Pan paniscus* and *Gorilla*<sup>73, 87, 115</sup>.

#### *Plantar interossei*

No information for *Hylobates*.

There are three plantar interossei in *Homo* and great apes<sup>7, 40, 73, 87, 102, 115</sup>, with the exception of a specimen of *Pan* stated to possess five plantar interossei<sup>22</sup>. The reference line for action is digit III in great apes, rather than digit II as in *Homo*<sup>7, 12, 87, 102, 105</sup>.

In *Homo*, *Pan* and *Pongo*, each interosseous muscle has a single head of origin<sup>7, 22, 40, 73, 115</sup>, while double heads of origin are present in *Gorilla*<sup>88</sup>.

The *first plantar interosseous* originates from MII in all apes<sup>7, 87</sup>, and from MIII in *Homo*<sup>115</sup> and as a second origin in *Gorilla*<sup>87</sup>.

It inserts into the lateral side of the proximal phalanx of digit II in all apes<sup>7, 22, 40, 73, 87</sup>, and into the medial side of digit III in *Homo*<sup>115</sup>, while *Gorilla* has a secondary insertion into the second metatarsophalangeal joint<sup>87</sup>.

The *second plantar interosseous* originates from the medial side of MIV in *Homo*, *Gorilla* and *Pongo*<sup>7, 87, 115</sup>, and excluding two accessory interossei, also in *Pan*<sup>22, 40</sup>. *Gorilla* has a secondary origin from a sesamoid bone at the bases of MIV and MV<sup>87</sup>.



It inserts into the medial side of digit IV in *Homo* and African apes<sup>22, 73, 87, 115</sup>, and into the lateral side of digit IV in *Pongo*<sup>7</sup>. *Gorilla* has a secondary insertion into the third metatarsophalangeal joint<sup>87</sup>.

The *third plantar interosseous* originates from the medial side of MV in *Homo*, *Gorilla* and *Pongo*<sup>7, 87, 115</sup>, and from the lateral side of MIV in *Pan*<sup>22</sup>. *Gorilla* has a secondary origin from the sesamoid bone at the bases of MIV and MV<sup>87</sup>.

It inserts into the medial side of digit V in *Homo* and African apes<sup>22, 40, 73, 87, 115</sup> and into the lateral side of digit V in *Pongo*<sup>7</sup>. *Gorilla* has a secondary insertion into the fourth metatarsophalangeal joint<sup>87</sup>.

No great ape has plantar interossei for digit III<sup>7</sup>, with the exception of the *Pan* specimen with five plantar interossei<sup>22</sup>. In the latter, the accessory interossei originate from the medial and lateral sides of MIII respectively, and insert onto the medial and lateral sides of the proximal phalanx of digit III<sup>22</sup>.

Plantar interossei are innervated by the lateral plantar nerve in *Homo*, *Pan paniscus* and *Gorilla*<sup>73, 87, 115</sup>.

## 3.7.2 VESSELS

### 3.7.2.1 Arteries

#### 3.7.2.1.1 Femoral<sup>b</sup>

No information for *Pongo*.

The deep circumflex iliac artery is a branch of the femoral artery in African apes<sup>70, 101</sup>, rather than the external iliac artery, as in *Homo*<sup>115</sup>.

Muscular branches of the femoral artery supply the adductor muscles in *Homo*, African apes and *Hylobates*<sup>31, 40, 70, 87, 115</sup>, vastus medialis in *Homo* and African apes<sup>31, 40, 87, 115</sup>, and sartorius in *Homo*<sup>115</sup>.

#### 3.7.2.1.1.1 Superficial

##### *Superficial epigastric*

No information for *Hylobates*.

The superficial epigastric artery is a branch of the femoral artery in *Homo*<sup>115</sup> and 1/2 *Pongo*<sup>70</sup>, but not in *Pan*<sup>70</sup>. In *Gorilla* the superficial epigastric is a branch of the lateral femoral circumflex<sup>81</sup>.

##### *Superficial circumflex iliac*

No information for *Hylobates*.

The superficial circumflex iliac artery is a branch of the femoral artery in great apes and *Homo*<sup>22, 31, 70, 83, 102, 115</sup>.

*Superficial external pudental*      See 3.7.2.1.1.2

#### 3.7.2.1.1.2 Deep

##### *Deep external pudental*

No information for *Hylobates*.

The external pudental arteries are branches of the femoral artery in *Homo*<sup>115</sup>, *Pan*<sup>31, 70</sup> and unilaterally in *Gorilla*<sup>81</sup>. No external pudental arteries are given off by the femoral artery in *Pongo*<sup>102</sup>.

### *Profunda femoris*

The profunda femoris artery in all apes and *Homo* originates from the femoral artery<sup>10, 22, 31, 70, 87, 101, 102, 106, 115</sup>.

Muscular branches supply the adductor muscles in all apes and *Homo*<sup>22, 31, 70, 101, 115</sup> the quadriceps muscles in *Homo*, *Pan* and *Pongo*<sup>31, 101, 102, 115</sup>, and the hamstrings in *Homo* and *Pan*<sup>101, 115</sup>. It also supplies the sartorius in *Pongo*<sup>102</sup>, and the pectineus, gracilis and iliopsoas muscles in *Pan*<sup>31</sup>.

The perforating branches of the profunda femoris are absent from 1/3 *Pongo*<sup>102</sup>. In the remaining specimen of *Pongo*, and in *Pan* and *Hylobates* there are two perforating branches<sup>31, 70, 81, 102, 115</sup> while in *Homo* and *Gorilla*, three perforating branches are present<sup>70, 115</sup>.

### *Lateral femoral circumflex*

The lateral femoral circumflex artery is a branch of the profunda femoris in all taxa<sup>10, 22, 23, 70, 80, 101, 102, 115</sup> except 1/2 *Gorilla*<sup>70</sup>. In *Homo* it may arise directly from the femoral artery<sup>115</sup>.

The lateral femoral circumflex artery divides into three branches in *Homo*, *Pan* and Asian apes<sup>70, 101, 102, 115</sup>. It may divide into five branches in *Pongo*<sup>81</sup>.

In *Gorilla* the ramus ascendens and descendens of the lateral femoral circumflex issue from the femoral artery independantly<sup>70</sup>.

### *Medial femoral circumflex*

The medial femoral circumflex artery is a branch of the femoral artery in *Gorilla* and *Pongo* and as a variation in *Homo*<sup>10, 31, 106, 23, 70, 81, 115</sup>, and of the profunda femoris in *Homo* and 2/4 *Pan*<sup>10, 70, 115</sup>.

In 2/4 *Pan*<sup>31, 106</sup> and *Hylobates*<sup>70</sup>, the medial femoral circumflex is a branch from the distal part of the external iliac artery.

### *Descending genicular*

No information for *Gorilla* and *Hylobates*.

A descending genicular artery is given off by the femoral artery in *Homo*, *Pan* and *Pongo*<sup>31, 81, 115</sup>.

### *Saphenous*

A large saphenous artery is given off by the femoral artery in all apes<sup>13, 15, 22, 23, 31, 70, 87, 101, 102, 105</sup>. In *Homo* the saphenous artery is a small branch of the descending genicular artery<sup>115</sup>.

The saphenous artery accompanies the saphenous nerve to the medial side of the knee, between sartorius and gracilis in *Homo* and *Pan*<sup>16, 22, 31, 115</sup>.

The saphenous artery runs on the medial side of the knee in *Homo* and great apes<sup>22, 31, 70, 115</sup>, subsequently being distributed to the skin of the proximomedial part of the leg and anastomosing with the medial inferior genicular artery in *Homo*<sup>115</sup>, while in apes the saphenous artery continues with the saphenous nerve to the foot<sup>22, 23, 40, 70, 81</sup>.

It enters the first interosseous space and completes the plantar arch in all apes<sup>70, 81, 101, 102</sup>.

In all apes, except 1/2 *Gorilla*<sup>70</sup>, the saphenous gives off close to its origin, a supra genu artery<sup>70, 87</sup>.

In *Pongo*, but in no other ape, a small posterior tibial artery arises from the saphenous artery<sup>70</sup>.

In *Pongo*, and in some specimens of *Pan*<sup>31</sup>, there is an anastomosis between the saphenous and anterior tibial arteries<sup>70</sup>, and in *Pan* and *Hylobates* between the saphenous and the perforating branch of the peroneal artery<sup>70</sup>.

The artery provides the dorsalis pedis in great apes<sup>16, 87, 101, 102</sup>.

### 3.7.2.1.2 Popliteal

#### *Popliteal*

The popliteal artery in all apes and *Homo* originates from the femoral artery<sup>31, 115</sup>.

The artery lies deep in the popliteal fossa of the knee in *Homo* alone<sup>71, 115</sup>.

In all taxa except *Pan* the popliteal artery divides into anterior and posterior tibial branches<sup>70, 102, 115</sup>, while in *Pan* it divides into a posterior tibial artery and a common branch for the anterior tibial and peroneal arteries<sup>31, 70</sup>. Variations in *Homo* include branching into anterior tibial and peroneal arteries, and a common trunk dividing into anterior tibial, posterior tibial and peroneal branches<sup>70, 115</sup>.

The genicular branches of the popliteal artery are the superior lateral genicular and the medial genicular in all apes and *Homo*<sup>31, 70, 81, 101, 115</sup> the superior medial genicular in all taxa except *Hylobates*<sup>70, 115</sup>, and inferior medial and inferior lateral genicular in *Homo*, *Pan* and *Hylobates*<sup>31, 70, 115</sup>.

### 3.7.2.1.3 Anterior tibial

#### *Anterior tibial*

No information for *Hylobates*.

The anterior tibial artery passes between the tibia and fibula in *Homo*, *Pan* and *Pongo*<sup>31, 102, 115</sup>.

An anterior tibial recurrent branch is given off in *Homo* and *Pongo*<sup>102, 115</sup>.

The peroneal artery arises from the anterior tibial artery in *Pan*<sup>123</sup> and *Pongo*<sup>70</sup>, rather than from the posterior tibial artery as in *Homo*<sup>115</sup>. The anterior tibial and peroneal arteries may arise from a common trunk in *Pan*<sup>31</sup>.

Unlike *Homo*<sup>115</sup> or *Pan*<sup>10, 22</sup> the artery does not reach the foot unilaterally in *Gorilla*<sup>81</sup>, or in *Pongo*<sup>81, 102</sup>.

It may be partially or entirely replaced distally by the saphenous artery in African apes<sup>14, 31, 40, 81</sup>.

#### *Dorsal artery of the foot*

No information for *Hylobates*.

The dorsalis pedis is the terminal branch of the anterior tibial artery in *Homo*<sup>115</sup>. In *Pan* there may be two terminal branches of the anterior tibial artery<sup>10</sup>.

In great apes the dorsalis pedis is a continuation of the saphenous artery<sup>14, 31, 87, 102</sup>, or of the posterior tibial artery in *Pan*<sup>101</sup>. It completes the plantar arch in *Homo*, *Pan* and *Pongo*<sup>31, 101, 102, 115</sup>.

#### 3.7.2.1.4 Posterior tibial

##### *Posterior tibial*

The posterior tibial artery is the terminal branch of the popliteal artery in all taxa<sup>70</sup> except *Pan*, in which the posterior tibial artery branches from the popliteal artery before its termination<sup>70</sup>.

It may be absent in *Homo*, in which case the peroneal artery takes its place<sup>115</sup>.

Calcaneal branches are present in *Homo* and great apes<sup>31, 70, 102, 115</sup>.

In all taxa, except *Hylobates*, the posterior tibial artery divides into medial and lateral plantar arteries<sup>31, 70, 101, 115</sup>. The lateral plantar artery is absent from *Hylobates*<sup>70</sup>.

##### *Peroneal*

In *Homo*, *Gorilla* and *Hylobates*, the peroneal artery is a branch of the posterior tibial artery<sup>31, 70, 115</sup>, in *Pongo* a branch of the anterior tibial artery<sup>70</sup>, and in *Pan* a branch of the popliteal artery<sup>31, 70</sup>.

The peroneal artery in all taxa except *Pongo* is larger than the posterior tibial artery<sup>70, 115</sup>.

In all apes and *Homo* the peroneal artery divides into perforating and lateral calcaneal rami<sup>31, 70, 115</sup>. In *Homo*, *Pan* and *Hylobates* the perforating branch anastomoses with the anterior lateral malleolar artery<sup>71, 115</sup>, which is a branch of the anterior tibial artery in *Homo*<sup>115</sup>, and of the saphenous artery in apes<sup>70</sup>.

##### *Medial plantar*


In *Homo* branches of the medial plantar artery supply the medial side of digit I<sup>115</sup>, and in *Homo* and *Pan* the first, second and third interosseous spaces<sup>70, 101, 115</sup>. In

*Pongo* branches of the medial plantar supply the second and third interosseous spaces<sup>70</sup>.

In *Hylobates* the medial plantar artery completes the plantar arch at the base of the first interosseous space<sup>70</sup>.

#### *Lateral plantar*

The lateral plantar artery is smaller than the medial plantar artery in 2/3 *Pongo*<sup>70</sup>, is of equal size in *Pan*<sup>70</sup>, and larger than the medial plantar artery in *Homo*<sup>115</sup>, *Gorilla*<sup>70</sup> and 1/3 *Pongo*<sup>81</sup>.



The lateral plantar artery is absent from *Hylobates*<sup>70</sup>.

In great apes and *Homo*, the artery crosses the sole obliquely, and completes the plantar arch by communicating with the dorsalis pedis<sup>31, 70, 101, 102, 115</sup>. However, in *Hylobates* the medial plantar artery completes the plantar arch<sup>70</sup>.

### 3.7.2.1.5 Anastomoses

#### *Deep plantar arch*

The deep plantar arch consists of the lateral plantar artery and dorsalis pedis in great apes and *Homo*<sup>31, 70, 115</sup>, and in *Hylobates* of the medial plantar artery and the dorsalis pedis<sup>70</sup>. The dorsalis pedis is a branch of the saphenous artery in apes<sup>70</sup>, and of the anterior tibial artery in *Homo*<sup>115</sup>.

Digital branches of the deep plantar arch run to the adjacent sides of digits III, IV and V in all apes and *Homo*<sup>31, 70, 115</sup>, II and III in all except *Pongo*<sup>70</sup> and 1/2 *Pan*<sup>70</sup>, the adjacent sides of digits I and II, and the lateral side of digit V in *Pongo* alone<sup>70</sup>, and both sides of digit I in 1/2 *Pan*<sup>81</sup>.



## *Plantar metatarsals*

No information for *Pongo*.

Four plantar metatarsal arteries are given off from the plantar arch in *Homo* and *Pan*<sup>70, 115</sup>, three in *Gorilla*<sup>70</sup> and a single vessel in *Hylobates*<sup>70</sup> which subsequently divides.

### 3.7.2.2 Veins<sup>b</sup>

#### 3.7.2.2.1 Superficial

##### 3.7.2.2.1.1 Foot

No information for *Hylobates*.

In *Pan* and *Pongo* three superficial veins arise from the dorsal venous arch<sup>101, 102</sup>, while only two are present in *Homo*<sup>115</sup>.

A medial and a lateral marginal vein are present in *Homo*<sup>115</sup>, while in African apes two medial veins and one lateral are found<sup>87, 101</sup>, and in *Pongo* one medial and two lateral veins are present<sup>102</sup>.

##### 3.7.2.2.1.2 Long saphenous

No information for *Hylobates*.

In *Homo* the medial marginal vein continues as the long saphenous vein<sup>115</sup>, while in great apes single (*Pan, Pongo*) or dual (*Gorilla*) lateral veins occupy this position<sup>87</sup>.

<sup>101, 102</sup>

A superficial medial vein may be absent from *Pan*<sup>16, 32</sup>.

There is no saphenous opening in *Pan*<sup>14, 101</sup>, unlike *Homo* and *Gorilla*<sup>14, 16, 115</sup>.

The medial vein of *Pongo*<sup>102</sup> and the two medial veins of *Gorilla* run with the saphenous artery<sup>87</sup>, while the two medial veins of *Pan* and *Gorilla* ascend to terminate in the femoral vein<sup>87, 101</sup>.

#### 3.7.2.2.1.3 Short saphenous

No information for *Hylobates*.

The lateral marginal vein of *Homo* continues as the small saphenous vein<sup>115</sup>, while one of two lateral veins occupies this position in *Pongo*<sup>102</sup>. In *Gorilla* the lateral marginal vein joins with a vein from the medial side of the heel to form the small saphenous vein, which subsequently divides into two branches, ascending to unite once more in the popliteal space<sup>87</sup>.

Two venae comitantes unite to form a popliteal vein in *Pan*<sup>101</sup>.

#### 3.7.2.3 Lymphatics

##### *Superficial inguinal nodes*

No information for *Pan*, *Pongo* and *Hylobates*.

In *Homo* there are nine to eleven superficial inguinal nodes<sup>115</sup>, and fourteen lymph nodes in the superficial inguinal region in *Gorilla*<sup>87</sup>.

##### *Popliteal nodes*

No information for *Hylobates*.

Present in *Homo*, *Gorilla* and *Pongo*<sup>87, 102, 115</sup>, but absent from *Pan*<sup>102</sup>.

Six or seven popliteal nodes are present in *Homo*<sup>115</sup>, compared with four in *Gorilla*<sup>87</sup>.

### 3.7.3 NERVES

#### 3.7.3.1 Lumbosacral plexus

##### *Lumbar plexus*

The lumbar plexus in *Homo*, *Pan* and *Pongo* consists of the first three lumbar nerves and the greater part of the fourth lumbar nerve<sup>101, 102, 115</sup>, the first lumbar nerve being supplemented by a branch from the last thoracic nerve in *Homo*<sup>115</sup>.

In *Pongo*, the plexus includes the first four lumbar nerves, but no branch from the last thoracic nerve was found<sup>102</sup>.

Five lumbar nerves are present in *Gorilla* and *Hylobates*<sup>39</sup>.

##### *Lumbosacral trunk*

The lumbosacral trunk is formed by the fourth and fifth lumbar nerves in *Homo*, *Gorilla* and *Hylobates*<sup>39, 115</sup>, and by the third and fourth lumbar nerves in 1/2 *Pan*<sup>101</sup> and *Pongo*<sup>39, 102</sup>. The lumbosacral trunk may involve only the fourth lumbar nerve in *Pan*<sup>39</sup>.

##### *Sacral plexus*

In all apes and *Homo* the lumbosacral trunk forms part of the sacral plexus<sup>39, 115</sup>. The first four lumbar nerves may be involved in *Pan*<sup>12</sup>.

The first four sacral nerves form the rest of the sacral plexus in *Homo* and 1/3 *Pan*<sup>101, 115</sup>, while only the first two sacral nerves are involved in the remaining great apes<sup>12</sup>.

### 3.7.3.2 Branches of lumbosacral plexus<sup>b</sup>

#### 3.7.3.2.1 Muscular branches

##### *Nerve to quadratus femoris and inferior gemellus*

This nerve originates from the first sacral nerve in all apes and *Homo*<sup>39, 115</sup>, from the second sacral nerve in *Pan* and *Pongo*<sup>39</sup> and from the fourth and fifth lumbar nerves in *Homo*<sup>115</sup>.

It may be given off by the tibial nerve<sup>6</sup> or the sciatic nerve<sup>101</sup> in *Pan*.

The nerve for the inferior gemellus arises independently from the sacral plexus in *Pongo*<sup>39</sup>.

##### *Nerve to obturator internus and superior gemellus*

This nerve arises from the first and second sacral nerves in all apes and *Homo*<sup>39, 87, 101, 115</sup>, from the fifth lumbar nerve in *Homo*<sup>115</sup>, and from the third and fourth lumbar nerves in *Gorilla*<sup>87</sup>.

##### *Nerve to piriformis*

No information for *Hylobates*.

This nerve originates from the first sacral nerve in *Homo*, *Gorilla* and *Pongo*<sup>39, 87, 115</sup>, and from the second sacral nerve in *Homo*<sup>115</sup>, *Pan*<sup>12, 39, 101</sup> and 1/2 *Gorilla*<sup>87</sup>. An origin from the lumbosacral trunk is present in 1/2 *Gorilla* and in *Pongo*<sup>39</sup>.

The contribution from the first sacral nerve may be absent from *Homo* as a variation<sup>115</sup>.

It may originate from the peroneal nerve in *Pan*<sup>6</sup>.

**3.7.3.2.2 Genitofemoral** See 3.6.3.2

**3.7.3.2.3 Lateral cutaneous nerve of thigh**

*Lateral cutaneous nerve of the thigh*

The lateral cutaneous nerve of the thigh has spinal components from the second lumbar nerve in all apes and *Homo*<sup>6, 12, 39, 101, 102, 115</sup>, from the first lumbar nerve in 2/4 *Pan*<sup>6, 12</sup> and *Pongo*<sup>39, 102</sup>, and from the third lumbar nerve in all taxa<sup>39, 101, 115</sup>, except *Pongo*<sup>39</sup> and 2/4 *Pan*<sup>6, 12</sup>.

The nerve runs across the surface of iliacus, and its distribution is to the skin over the anterior and lateral surfaces of the thigh in all apes and *Homo*<sup>39, 87, 102, 115</sup>.

**3.7.3.2.4 Femoral**

*Femoral*

The femoral nerve has spinal components from the second and third lumbar nerves in all apes and *Homo*<sup>6, 12, 39, 101, 102, 115</sup>, additionally from the first lumbar nerve in *Pan*<sup>6, 12, 39, 101</sup> and *Pongo*<sup>39, 102</sup>, and from the fourth lumbar nerve in all taxa<sup>12, 39, 115</sup>, except 3/4 *Pan*<sup>6, 39, 101</sup> and *Pongo*<sup>39</sup>.

The average central point of origin for the femoral nerve is more cranial in *Pongo* than in African apes and *Homo*; and most caudal in *Hylobates*<sup>48</sup>.

Muscular branches innervate iliacus, psoas major, pectineus, sartorius and quadriceps in all apes and *Homo*<sup>12, 39, 87, 101, 102, 115</sup>, psoas minor in African apes and *Homo*<sup>87, 106, 115</sup> and gracilis in *Pan* alone<sup>101</sup>.

In all taxa, the femoral nerve divides into medial and middle cutaneous nerves, and the saphenous nerve<sup>39, 87, 102, 115</sup>.

### 3.7.3.2.5 Obturator

#### *Obturator*

The obturator nerve in all apes and *Homo* has spinal components from the second, third and fourth lumbar nerves<sup>6, 12, 39, 87, 101, 102, 115</sup>, and may also contain elements from the first lumbar nerve in *Pan* and *Pongo*<sup>6, 12, 39, 101</sup>. The origin from the second lumbar nerve may be absent from *Hylobates*<sup>39</sup>, and that from the fourth lumbar nerve may be absent from African apes<sup>12, 87</sup>.

In *Homo* the points of origin of the femoral and obturator nerves are practically the same<sup>115</sup>. In *Gorilla* and Asian apes the origin of the obturator is distal to that of the femoral nerve, while in *Pan* the origin of the obturator is slightly proximal to that of the femoral<sup>48</sup>.

The obturator nerve pierces the oblique posterior ligament of the knee in *Homo*<sup>115</sup>, but does not do so in apes<sup>39</sup>.

Muscular branches innervate the adductor muscles, obturator externus and gracilis in all apes and *Homo*<sup>12, 36, 39, 87, 97, 101, 115</sup>, also pectineus in 1/2 *Pan*<sup>101</sup>, and frequently in *Homo*<sup>115</sup>.

### 3.7.3.2.6 Superior gluteal

#### *Superior gluteal*

The superior gluteal nerve arises from the lumbosacral trunk in all apes and *Homo*<sup>12, 39, 102, 115</sup>, and also from the first sacral nerve in *Homo* and great apes<sup>12, 39, 102, 115</sup>, but not in *Hylobates*<sup>39</sup>.

### 3.7.3.2.7 Inferior gluteal

#### *Inferior gluteal*

No information for *Gorilla* or *Hylobates*.

The inferior gluteal nerve originates from the second sacral nerve in *Homo*, *Pan* and *Pongo*<sup>6, 102, 115</sup>, the first sacral nerve in *Homo* and *Pan*<sup>6, 115</sup>, and from the fifth lumbar nerve in *Homo*<sup>115</sup>, and the fourth lumbar nerve in *Pan*<sup>6</sup>.

It may originate from the superior gluteal nerve in *Pan*<sup>101</sup>.

### 3.7.3.2.8 Posterior femoral cutaneous

#### *Posterior femoral cutaneous*

This nerve arises from the first, second and third sacral nerves in *Homo*<sup>115</sup>, from the superior part of the sacral plexus in apes<sup>12, 39</sup>, and from the third and fourth lumbar nerves in *Pan*<sup>12</sup>.

It originates from the sciatic nerve in *Gorilla*<sup>87</sup>.

The nerve enters the thigh between two heads of gluteus maximus in *Pongo*<sup>39</sup>, and subjacent to this muscle in *Homo*, African apes and *Hylobates*<sup>39, 87</sup>.

Cutaneous branches of the nerve supply the gluteal region, perineum and flexor aspect of the thigh and leg in all apes and *Homo*<sup>39, 115</sup>.

### 3.7.3.2.9 Sciatic

The sciatic nerve is formed by the lumbosacral trunk and all the sacral nerves in *Homo*<sup>115</sup>, and from the lumbosacral trunk and the first two sacral nerves in apes<sup>6, 12, 39, 101, 102</sup>. It may also include the upper lumbar nerves in *Pan*<sup>12</sup>. Keith places the

central point of origin for the sciatic nerve almost equally in *Homo* and African apes, but further proximally in *Pongo*, and further distally in *Hylobates*<sup>48</sup>.

Muscular branches of the sciatic nerve supply biceps femoris, semitendinosus, semimembranosus and the ischial head of adductor magnus in *Homo* and great apes<sup>12, 87, 101, 102, 115</sup>.

The sciatic nerve divides into tibial and common peroneal nerves in all apes and *Homo*<sup>102, 115</sup>, at the inferior third of the thigh in *Homo* and *Pongo*<sup>102, 115</sup>, and in the popliteal space in *Pan*<sup>12, 101</sup>, although the bifurcation can be artificially carried more proximally in all apes and *Homo*<sup>39, 115</sup>.

#### 3.7.3.2.9.1 Tibial

##### *Tibial*

The tibial nerve is the larger continuation of the sciatic nerve in all apes and *Homo*<sup>39, 102, 115</sup>, involving the first two sacral nerves in all apes and *Homo*<sup>39, 115</sup>. It also includes the fourth and fifth lumbar and third sacral nerves in *Homo*<sup>115</sup>.

Muscular branches innervate gastrocnemius, soleus and popliteus in all apes and *Homo*<sup>39, 87, 102, 115</sup>, flexor digitorum longus in African apes and *Homo*<sup>73, 87, 115</sup>, tibialis posterior and flexor hallucis longus in *Homo* and *Gorilla*<sup>87, 115</sup>, abductor hallucis in *Gorilla*<sup>87</sup>, and plantaris in *Homo*<sup>115</sup>.

It supplies the lateral side of the foot and digit V in all apes and *Homo*<sup>39, 87, 102, 115</sup>.



### 3.7.3.2.9.1.1 Medial plantar

#### *Medial plantar*

The medial plantar nerve is a terminal division of the posterior tibial nerve in all apes and *Homo*<sup>39, 101, 115</sup>.

Muscular branches innervate flexor digitorum brevis, flexor hallucis brevis, and abductor hallucis in all apes and *Homo*<sup>12, 39, 87, 101, 102, 115</sup>, adductor hallucis in *Pan* and *Pongo*<sup>39, 101, 102</sup>, the medialmost lumbrical alone in *Homo* and *Gorilla*<sup>39, 87, 115</sup>, and the second inner lumbrical in *Pan*, *Pongo* and *Hylobates*<sup>39, 101</sup>.

Cutaneous branches run to the adjacent sides of digits I to IV in all apes and *Homo*<sup>39, 87, 101, 102, 115</sup> except *Hylobates* in which they reach the adjacent sides of digits I to III<sup>39</sup>.

### 3.7.3.2.9.1.2 Lateral plantar

#### *Lateral plantar*

The lateral plantar nerve is a terminal division of the posterior tibial nerve in all apes and *Homo*<sup>39, 101, 115</sup>.

Muscular branches innervate abductor digiti minimi, flexor digiti minimi brevis, and the muscles of the fourth interspace, the interossei and lumbricals in all apes and *Homo*<sup>39, 87, 101, 115</sup>, flexor accessorius (when present) in great apes and *Homo*<sup>39, 115</sup>, and adductor hallucis in all apes and *Homo*<sup>9, 39, 73, 87, 101, 115</sup>.

Cutaneous branches run to the lateral one and a half digits in all apes and *Homo*<sup>39, 87, 115</sup>, extending to the adjacent sides of digits III and IV in great apes<sup>39</sup>.

### 3.7.3.2.9.2 Common peroneal

#### *Common peroneal*

The second main division of the sciatic nerve, the common peroneal nerve arises from the lumbosacral trunk in all apes and *Homo*<sup>39, 115</sup>, and from the first and second sacral nerves in *Homo*<sup>115</sup>.

The nerve ends deep to peroneus longus in *Homo* and 1/2 *Gorilla*<sup>87, 115</sup>, but in the substance of peroneus longus in *Pan*, 1/2 *Gorilla* and Asian apes<sup>39</sup>, in all taxa by dividing into superficial and deep peroneal nerves<sup>39, 87, 101, 115</sup>.

#### 3.7.3.2.9.2.1 Deep peroneal (anterior tibial)

##### *Deep peroneal*

No information for *Hylobates*.

Muscular branches are given to tibialis anterior, extensor hallucis longus, extensor digitorum longus in *Homo*, *Gorilla* and *Pongo*<sup>87, 102, 115</sup>, peroneus tertius in *Homo*<sup>115</sup> and flexor digitorum brevis in *Pan*<sup>101</sup>.

The nerve does not reach the foot in *Pongo*<sup>39, 91, 102</sup>, unlike *Homo* and African apes<sup>39, 87, 115</sup>.

The digital supply of the deep peroneal nerve involves digits II and III in *Homo* and African apes<sup>39, 87, 101, 115</sup>, digit I in *Homo* and *Pan*<sup>101, 115</sup> and IV in *Homo*<sup>115</sup>.

#### 3.7.3.2.9.2.2 Superficial peroneal

##### *Superficial peroneal*

The superficial peroneal nerve in all apes and *Homo* innervates the peroneal muscles, and the skin of the dorsum of the foot with the exception of the borders of the sole,

the lateral side of digit V and the medial side of digit I<sup>39, 87, 91, 102, 115</sup>. In *Homo* and *Pan* it does not supply the medial side of digit II<sup>39, 101, 115</sup>.

## BIBLIOGRAPHY

1. **Appleton, AB** (1922): On the hypotrochanteric fossa and accessory adductor groove of the primate femur. *J. Anat. Phys.* 56, p295-306.
2. **Barnard, WS** (1875): Observations on the membral musculation of *Simia satyrus* (Orang) and the comparative myology of man and the apes. *Proc. Am. Assoc. Advanc. Sci.* 24, p112-144.
3. **Beddard, FE** (1893): Contributions to the anatomy of the anthropoid apes. *Trans. Zool. Soc. Lond.* 13, p177-218.
4. **Bischoff, TLW** (1870): Beiträge zur Anatomie des *Hylobates leuciscus* and zu einer vergleichenden Anatomie der Muskeln der Affen und des Menschen. *Abh. Bayer. Akad. Wiss. München. Math. Phys. Kl.* 10, p197-297.
5. **Blake, ML** (1967): The quantitative myology of the hind limb of Primates with special reference to their locomotor adaptations. PhD Thesis, Magdalene College, University of Cambridge.
6. **Bolk, L** (1921): The relations between the ductless glands and evolution of the Primates. *Lancet.* p588-592.
7. **Boyer, EL** (1935): The musculature of the inferior extremity of the orang-utan *Simia satyrus*. *Am. J. Anat.* 56(2), p192-256.
8. **van den Broek, AJ** (1914): Studien zur Morphologie des Primatenbeckens. *Morphol. Jahrb.* 49, p1-118.
9. **Brooks, HSJ** (1887): On the short muscles of the pollex and hallux of the anthropoid apes, with special reference to the opponens hallucis. *J. Anat. Phys.* 22, p78-95.
10. **Brown, JM** (1881): The femoral artery in apes. *J. Anat. Phys.* 15, p523-535.

11. **Brown, B** (1983): An evaluation of primate caudal musculature in the identification of the ischiofemoralis muscle. *Am.J.Phys.Anthropol.* 60, p177-178 (Abst).
12. **Champneys, F** (1872): On the muscles and nerves of a chimpanzee (*Troglodytes niger*) and a cynocephalus anubis. *J.Anat.Phys.* 6, p176-211.
13. **Chapman, HC** (1878): On the structure of the gorilla. *Proc.Zool.Soc.Lond.* p385-394.
14. **Chapman, HC** (1879): On the structure of the chimpanzee. *Proc.Zool.Soc.Lond.* p52-63.
15. **Chapman, HC** (1880): On the structure of the orang outang. *Proc.Zool.Soc.Lond.* p160-174.
16. **Chapple, CR and Wood, BA** (1980): Venous drainage of the hind limb in the monkey (*Macaca fascicularis*). *J.Anat.* 131, p157-171.
17. **Church, WS** (1861/2): On the myology of the orang utang (*Simia morio*). *Nat.Hist.Review.* 1, p510-516; 2, p89-94, 414-423.
18. **Deniker, J** (1885/6): Recherches anatomiques et embryologiques sur les singes anthropoides: Foetus de gorille et de gibbon. *Arch.Zool.Exp.Gen. Ser.2*, 3(3), p1-265.
19. **Duckworth, WLH** (1898): Note on a foetus of *Gorilla savagei*. *J.Anat.* 33, 82-90.
20. **Duvernoy, M** (1853): Cited in Brooks(1887).
21. **Duvernoy, M** (1855-6): Des caractères anatomiques de grands singes pseudo-anthropomorphes. *Arch.Mus.Natl.Hist.Nat.(Paris)*. 8, p1-248.
22. **Dwight, T** (1895): Notes on the dissection and brain of the chimpanzee "Gumbo". *Mem.Boston Soc.Nat.Hist.* 5, p31-51.
23. **Eisler, P** (1890): Das Gefäss- und periphere Nervensystem des Gorilla. Tausch and Grosse, Halle.
24. **Eisler, P** (1895): Die Homologie der Extremitäten. *Abh.Naturforsch.Ges. Halle.* 19, p87-346.

25. **Embleton** (1864): Cited in Chapman(1879)
26. **Fick,R** (1895): Vergleichend-anatomische Studien an einem erwachsenen Orang-utang. Arch.Anat.Physiol. Anat.Abt. p1-100.
27. **Flower,WH and Murie,J** (1867): Account of the dissection of a bushwoman. J.Anat.Phys. 1, p189-208.
28. **Forster,A** (1903): Die Insertion des Musculus semimembranosus. Arch.Anat.Physiol. Anat.Abt. p257-320.
29. **Frey,H** (1913): Der Musculus triceps surae in der Primatenreihe. Morphol.Jahrb. 47, p1-192.
30. **Fürst,CM** (1903): Der Musculus Popliteus und seine Sehne. E.Malstrom, Lund.
31. **Glidden,EM and De Garis,CF** (1936): Arteries of the chimpanzee. I. The aortic arch; II. Arteries of the upper extremity; III. The descending aorta; IV. Arteries of the lower extremity. Am.J.Anat. 58(2), p501-527.
32. **Gratiolet,LP and Alix,PHE** (1866): Recherches sur l'anatomie de *Troglodytes aubryi*, chimpanzé d'une espèce nouvelle. Nouv.Arch.Mus.Natl.Hist.Nat.(Paris). 2, p1-264.
33. **Gregory,WK(ed)** (1950): The anatomy of the Gorilla. Columbia University Press, New York.
34. **Hafferl,A** (1929): Bau und Funktion des Affenfusses. Ein Beitrag zur Gelenk und Muskel-mechanik. Z.Anat.Entwicklungsgesch. 88, p749-783.
35. **Hallisy,JE** (1930): The muscular variations in the human foot. A quantitative study. Am.J.Anat. 45, p411-442.
36. **Hamada,Y** (1985): Primate hip and thigh muscles: comparative anatomy and dry weights; In: Kondo,S(ed); Primate Morphophysiology, Locomotor Analyses and Human Bipedalism. University of Tokyo Press, Tokyo; p131-152.
37. **Hartmann,R** (1883): Cited in MacDowell(1910).
38. **Hecker,P** (1922): Formation du peronier anterieur chez un chimpanzee. Arch.Anat.Histol.Embryol. 1, p147-155.

39. **Hepburn, D** (1892): The comparative anatomy of the muscles and nerves of the superior and inferior extremities of the anthropoid apes. *J. Anat. Phys.* 26, p149-186, 324-356.
40. **Humphry, GM** (1866/7): On some points in the anatomy of the chimpanzee. *J. Anat. Phys.* 1, p254-268.
41. **Huxley, TH** (1864): Lectures on the structure and classification of the Mammalia. *Med. Times and Gaz. (London)*. 1, p564-565.
42. **Jungers, WL; Meldrum, DJ and Stern, JT** (1993): The functional and evolutionary significance of the human peroneus tertius muscle. *J. Hum. Evol.* 25, p377-386.
43. **Kanefff, A** (1986a): Die Aufrichtung des Menschen und die morphologisches Evolution der Musculi extensores digitorum pedis unter dem Gesichtspunkt der evolutiven Myologie. Teil I. Gegenbaur's *Morphol. Jahrb.* 132, p375-419.
44. **Kaplan, EB** (1958a): The iliotibial tract. Clinical and morphological significance. *J. Bone. Jt. Surg.* 40A, p817-832.
45. **Kaplan, EB** (1958b): Comparative anatomy of the extensor digitorum longus in relation to the knee joint. *Anat. Rec.* 131(2), p129-149.
46. **Keats, TE** (1988): Atlas of normal roentgen variants that may simulate disease. Year Book Medical Publ., Chicago.
47. **Keith, A** (1894): The myology of the catarrhini: A study in evolution. PhD thesis. University of Aberdeen.
48. **Keith, A** (1902): The extent to which the posterior segments of the body have been transmuted and suppressed in the evolution of man and allied primates. *J. Anat. Phys.* 37, p18-40.
49. **Keith, A** (1923): The adaptational machinery concerned in the evolution of man's body. *Nature.* 112, p257-268.
50. **Kimura, K and Takahashi, Y** (1985): The peroneus tertius muscle in the crab-eating monkey (*Macaca fascicularis*). *Okajimas Folia Anat. Jpn.* 62, p173-186.

51. **Kohlbrügge, JHF** (1890/91): Versuch einer anatomie des Genus *Hylobates*. Muskeln und periphere Nerven. Zoologische Ergebnisse einer Reise in Niederländisch Ost-Indien. 1, p211-354; 2, p139-206. E.J.Brill; Leiden.
52. **Kohlbrügge, JHF** (1897): Muskeln und Periphere Nerven der Primaten, mit besonderer Berücksichtigung ihrer Anomalien. Verh.K.Akad.Wet.Amsterdam. Section 2, 5(6), p1-246.
53. **Kumakura, H** (1989): Functional analysis of the biceps femoris muscle during locomotor behavior in some primates. Am.J.Phys.Anthropol. 79, p379-391.
54. **Langer, C** (1879): Die Muskeln der Extremitäten des Orang als Grundlage einer vergleichend-anatomischen Untersuchung. Sitzungsber.Kaiserl.Akad.Wiss.Wien. Math.-Naturwiss.Cl. 80, p177-222.
55. **Latimer, B and Lovejoy, CO** (1989): The calcaneus of *Australopithecus afarensis* and its implications for the evolution of bipedality. Am.J.Phys.Anthropol. 78, p369-386.
56. **Le Double, F** (1897): Traité des variations du système musculaire de l'homme et de leur signification au point de vue de l'anthropologie zoologique, I et II. Librairie C.Reinwald, Paris.
57. **Le Minor, JM** (1992): Brief communication: The popliteal sesamoid bone (cyamella) in primates. Am.J.Phys.Anthropol. 87, p107-110.
58. **Lewis, OJ** (1962): The comparative morphology of M.flexor accessorius and the associated long flexor tendons. J.Anat. 96, p321-333.
59. **Lewis, OJ** (1964a): The evolution of the long flexor muscles of the leg and foot. Int.Rev.Gen.Exp.Zool. 1, p165-185.
60. **Lewis, OJ** (1964b): The tibialis posterior tendon in the primate foot. J.Anat. 98, p209-218.
61. **Lewis, OJ** (1966): The phylogeny of the cruropedal extensor musculature with special reference to the primates. J.Anat. 100, p865-880.
62. **Loth, E** (1908): Die Aponeurosis plantaris in der Primaten reihe. Gegenbaurs Morphol.Jahrb. 38, p194-322.

- 63.**Loth,E** (1914): Zur Anthropologie der Plantaraponeurose. *Morphol.Jahrb.* 48, p83-96.
- 64.**Loth,E** (1931): Anthropologie des parties molles (muscles, intestins, vaisseaux, nerfs peripheriques). Mianowski-Masson et Cie, Varsovie, Paris.
- 65.**MacAlister,A** (1871): On some points in the myology of the chimpanzee and of the primates. *Ann.Mag.Nat.Hist.* 7(2), p341-351.
- 66.**MacAlister,A** (1873): The muscular anatomy of the gorilla. *Proc.Royal Irish Acad.* 11, p501-506.
- 67.**MacDowell,EC** (1910): Notes on the myology of *Anthropopithecus niger* and *Papio-thoth ibeanus*. *Am.J.Anat.* 10, p431-460.
- 68.**McMinn RMH** (1990): *Last's Anatomy: regional and applied*; 8th ed. Churchill Livingstone, Edinburgh.
- 69.**Manners-Smith,T** (1908): A study of the cuboid and os peroneum in the primate foot. *J.Anat.Phys.* 42, p397-414.
- 70.**Manners-Smith,T** (1912): The limb arteries of primates. Part 1. *J.Anat.Phys.* 46, p95-172.
- 71.**Michaëlis,P** (1903): Beiträge zur vergleichenden Myologie des *Cynocephalus babuin*, *Simia satyrus*, *Troglodytes niger*. *Arch.Anat.Phys. Anat.Abt.* p205-256.
- 72.**Miller,RA** (1945): The ischial callosities of primates. *Am.J.Anat.* 76, p67-87.
- 73.**Miller,RA** (1952): The musculature of *Pan paniscus*. *Am.J.Anat.* 91(2), p182-232.
- 74.**Morton,DJ** (1922): Evolution of the human foot. Part 1. *Am.J.Phys.Anthropol.* 5, p305-336.
- 75.**Morton,DJ** (1924): The peroneus tertius muscle in gorillas. *Anat.Rec.* 27(5), p323-328.
- 76.**Mysberg,WA** (1917): Über die Verbindungen zwischen dem Sitzbeine und der Wirbelsäule bei den Säugetieren. *Anat.Hefte.* 54, p641-668.



77. **Owen, R** (1830/1): On the anatomy of the orangutan (*Simia satyrus*, L.).  
Proc.Zool.Soc.Lond. 1, p4-5,9-10, p28-29,66-72.
78. **Oxnard, CE** and **Lisowski, FP** (1980): Functional articulation of some hominoid foot bones: Implications for the Olduvai (Hominid 8) foot.  
Am.J.Phys.Anthropol. 52, p107-117.
79. **Pearson, K** and **Davin, AG** (1921): On the sesamoids of the knee joint.  
Biometrika. 13, p133-175, 350-400.
80. **Pira, A** (1914): Beiträge zur Anatomie des Gorilla. I. Das Extremitätenmuskelsystem. Morphol.Jahrb. 48, p167-238.
81. **Popowsky, J** (1895): Das Arteriensystem der unteren Extremitäten bei den Primaten. Anat.Anz. 10, p55-80, 99-114.
82. **Prejzner-Morawska, A** and **Urbanowicz, M** (1971): The biceps femoris muscle in lemurs and monkeys. Folia Morphol. 30, p465-482.
83. **Preuschoft, H** (1961): Muskeln und Gelenke der Hinterextremität des Gorillas. Morphol.Jahrb. 101, p432-540.
84. **Primrose, A** (1899): The anatomy of the Orang-outang (*Simia satyrus*), an account of some of its external characteristics; and the myology of the extremities. Trans.R.Can.Inst. 6, p507-594.
85. **Primrose, A** (1900): The anatomy of the orang-outang. Univ.of Toronto Studies. Anat.series 1, p1-94.
86. **Ranke, K** (1897): Muskel- und Nervenvariationen der dorsalen elemente des Plexus ischiadicus der Primaten. Arch.Anthropol. 24, p117-144.
87. **Raven, HC** (1950): Regional anatomy of the Gorilla. In: Gregory, WK(ed); The anatomy of the Gorilla. Columbia University Press, New York; p 15-188.
88. **Robinson, JT**; **Freedman, L** and **Sigmon, BA** (1972): Some aspects of pongid and hominid bipedality. J.Hum.Evol. 1, p361-369.
89. **Rolleston, G** (1867/8): Cited in Champneys(1872).
90. **Rózycki, S** (1922): Cited in Urbanowicz and Prejzner-Morawska(1972).

91. **Ruge,G** (1878a): Untersuchung über die Extensorengruppe aus Unterschenkel und Füße der Säugethiere. *Morphol.Jahrb.* 4, p592-643.
92. **Ruge,G** (1878b): Zur vergleichenden Anatomie der tiefen Muskeln in der Fusssohle. *Morphol.Jahrb.* 4, p644-659.
93. **Sandifort,G** (1840): Ontleedkundige beschouwing van een' volwassen Orang-oetan (*Simia satyrus*, Linn.) van het mannelijk geslacht. In: Temminck,CJ; Verhandelingen over de Natuurlijke geschiedenis der Nederlandische overzeesche bezittingen, door de leden der Natuurkundige commissie in Indië en andere Schrijvers(Zoologie). 3, p29-56, Leiden.
94. **Sarmiento,EE** (1983): The significance of the heel process in anthropoids. *Int.J.Primatol.* 4, p127-152.
95. **Sawalaschin,M** (1911): Die musculus flexor communis brevis digitorum pedis in der Primatenreihe mit spezieller Berücksichtigung des Menschlichen Varietäten. *Morphol.Jahrb.* 42, p557-663.
96. **Sigmon,BA** (1969): The scansorius muscle in pongids. *Primates.* 10, p247-261.
97. **Sigmon,BA** (1974): A functional analysis of pongid hip and thigh musculature. *J.Hum.Evol.* 3, p161-185.
98. **Slanina,J** (1956): Fabella distalis: A new sesamoid bone. *Radiol.Clin.* 25, p274-277.
99. **Sneath,RS** (1955): The insertion of the biceps femoris. *J.Anat.* 89, p550-553.
100. **Sommer,A** (1907): Das Muskelsystem des Gorilla. *Jena.Z.Naturwiss.* 42, p181-308.
101. **Sonntag,CF** (1923): On the anatomy, physiology, and pathology of the chimpanzee. *Proc.Zool.Soc.Lond.* 23, p323-429.
102. **Sonntag,CF** (1924): On the anatomy, physiology, and pathology of the orang-outan. *Proc.Zool.Soc.Lond.* 24, p349-450.
103. **Stern,JT** (1972): Anatomical and functional specializations of the human gluteus maximus. *Am.J.Phys.Anthropol.* 36, p315-340.

104. **Straus, WL Jr** (1930): The foot musculature of the highland gorilla (*Gorilla beringei*). Q.Rev.Biol. 5, p261-317.
105. **Sutton, JB** (1883): On some points in the anatomy of the chimpanzee (*Anthropopithecus troglodytes*). J.Anat.Phys. 18, p66-85.
106. **Swindler, DR.** and **Wood, CD** (1973): An atlas of primate gross anatomy; baboon, chimpanzee, and man. University of Washington Press, Seattle.
107. **Tappen, NC** (1955): Relative weights of some functionally important muscles of the thigh, hip and leg in a gibbon and in man. Am.J.Phys.Anthropol. 13(3), p415-420.
108. **Terry, RJ** (1942): Absence of the superior gemellus muscle in American whites and Negroes. Am.J.Phys.Anthropol. 29, p47-56.
109. **Testut, L** (1884): Les anomalies musculaires chez l'homme expliquées par l'anatomie comparée. Leur importance en anthropologie. G.Masson, Paris.
110. **Traill, T** (1817): Anatomy of a chimpanzee. Mem.Wernerian Nat.Hist.Soc.Edinb. 3, p1-149.
111. **Turner, W** (1864): Cited in Lewis(1962).
112. **Urbanowicz, M** and **Prejzner-Morawska, A** (1972): The triceps surae muscle in chimpanzees. Folia Morphol. 31, p433-440.
113. **Vallois, H** (1914): Étude anatomique de l'articulation du genou chez les Primates. L'Abeille, Montpellier.
114. **Vrolik, W** (1841): Recherches d'anatomie comparée, sur le chimpansé. Johannes Miller, Amsterdam.
115. **Warwick, P** and **Williams, PL** (1973): Gray's Anatomy. 35th British Edition. Saunders Co., Philadelphia.
116. **Waterman, HC** (1929): Studies on the evolution of the pelvis of man and other primates. Bull.Am.Mus.Nat.Hist. 55, p585-642.
117. **Wells, LH** (1952): The flexor digitorum brevis muscle in the foot of the South African negro. J.Anat. 86, p486.

118. **Van Westrienen, A** (1907): Das Kniegelenk der Primaten, mit besonderer Berücksichtigung der Anthropoiden. Petrus Camper. 4, p1-60.
119. **Wilder, B** (1862): Contributions to the comparative myology of the chimpanzee. Boston J.Nat.Hist. 6, p352-384.
120. **Wood, J** (1867): On human muscular variations and their relation to comparative anatomy. J.Anat.Phys. 1, p44-59.
121. **Yirga, S** (1987): Interrelation between ischium, thigh extending muscles and locomotion in some primates. Primates. 28(1), p79-86.
122. **Zihlman, A** and **Brunker, L** (1979): Hominid bipedalism: Then and now. Yearb.Phys.Anthropol. 22, p132-162.
123. **Zuckerman, S** (1895): Cited in Glidden and De Garis (1936).

## CHAPTER 4

### STATISTICAL RESULTS AND DISCUSSION

#### 4.1 RESULTS OF PARSIMONY AND BOOTSTRAP ANALYSES

##### 4.1.1 First hypothesis

The principal hypothesis tested in this thesis was the ability of soft tissue anatomical characters to reconstruct a pattern of cladistic relationships among the extant hominoids that was consistent with the consensus molecular phylogenetic tree (see Figure 4.1).

The results of the bootstrap analysis, and the length and fit measures for the most parsimonious trees of Datasets A and B (after the exclusion of the uninformative characters) are shown below.

Of the original 200 characters of Dataset A, 45 were excluded as uninformative, while of the original 130 characters of Dataset B, 16 were excluded as uninformative.

	Dataset A	Dataset B
Potential clade	Frequency	Frequency
<i>Pan-Homo</i>	92	42
<i>Gorilla-Pan-Homo</i>	85	96
<i>Pongo-Pan-Homo</i>	12	>0.1
<i>Gorilla-Homo</i>	3	13
<i>Pongo-Pan</i>	2	1
<i>Pongo-Gorilla</i>	2	3
<i>Pongo-Gorilla-Homo</i>	1	-
<i>Pongo-Gorilla-Pan</i>	1	4
<i>Pongo-Homo</i>	1	>1
<i>Gorilla-Pan</i>	>1	42
Length	293	182
CI	0.65	0.75
RI	0.34	0.60

**Table 4.1. Bootstrap values (%) for datasets A and B, and lengths, CI and RI of tree 2 (Dataset A, 155 characters) and tree 3 (Dataset B, 114 characters). CI = Consistency index, RI = Retention index.**

Bootstrap analysis of Dataset A supports the hypothesis that soft tissue anatomy can be used to reconstruct the cladistic relationships between the Hominoidea.

Both the *Homo-Pan* and *Homo-Gorilla-Pan* cladistic groups are significantly favoured, with bootstrap values of 92% and 85% respectively.

Neither *Gorilla-Homo* or *Gorilla -Pan*, the main alternative cladistic groupings, are significantly supported by Dataset A. Dataset B differs from Dataset A in weakly supporting *Gorilla-Pan* (42%), in fact, at a very similar level to that at which Dataset B supports the favoured molecular consensus clade *Pan-Homo*<sup>156</sup>.

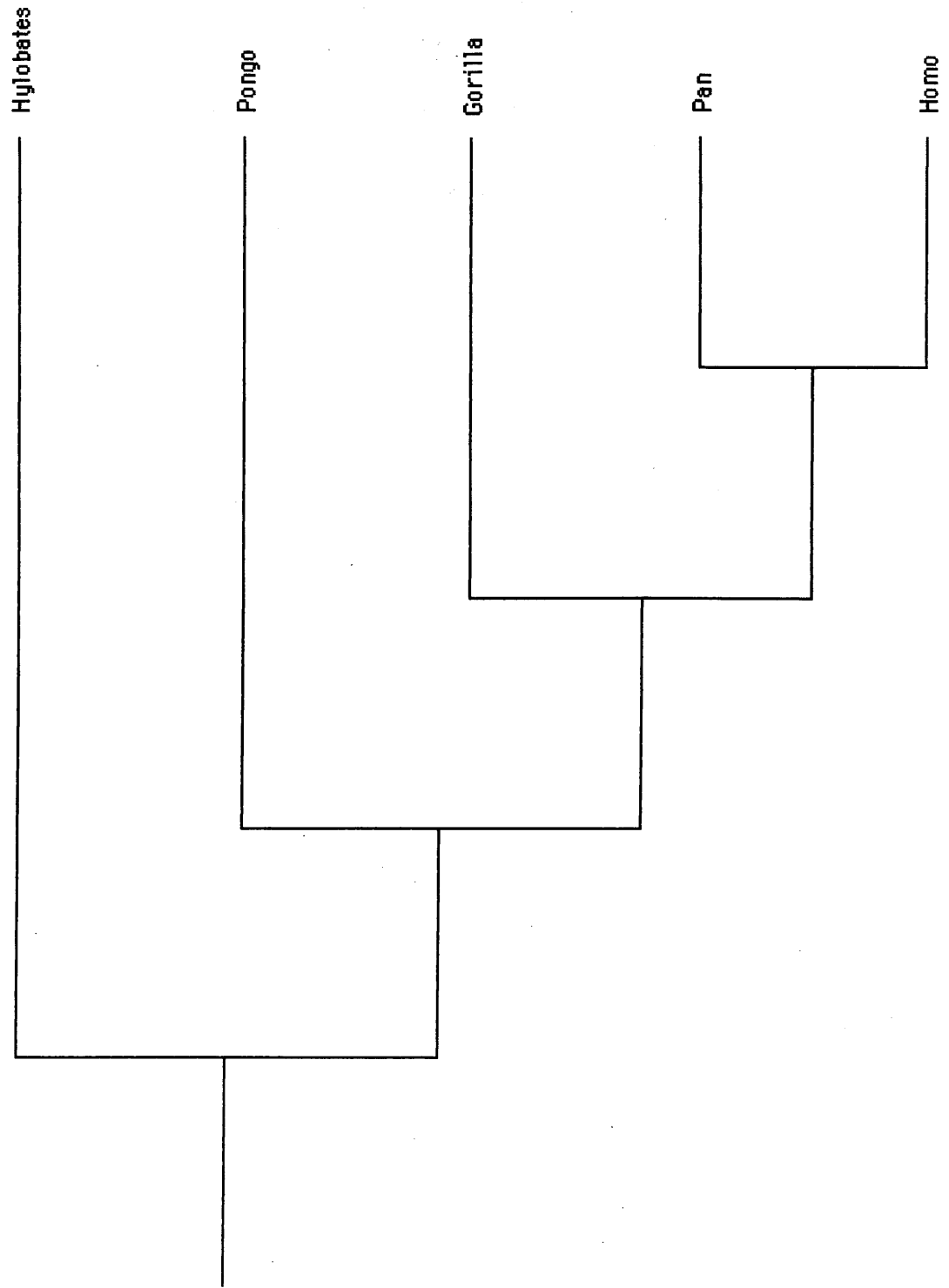
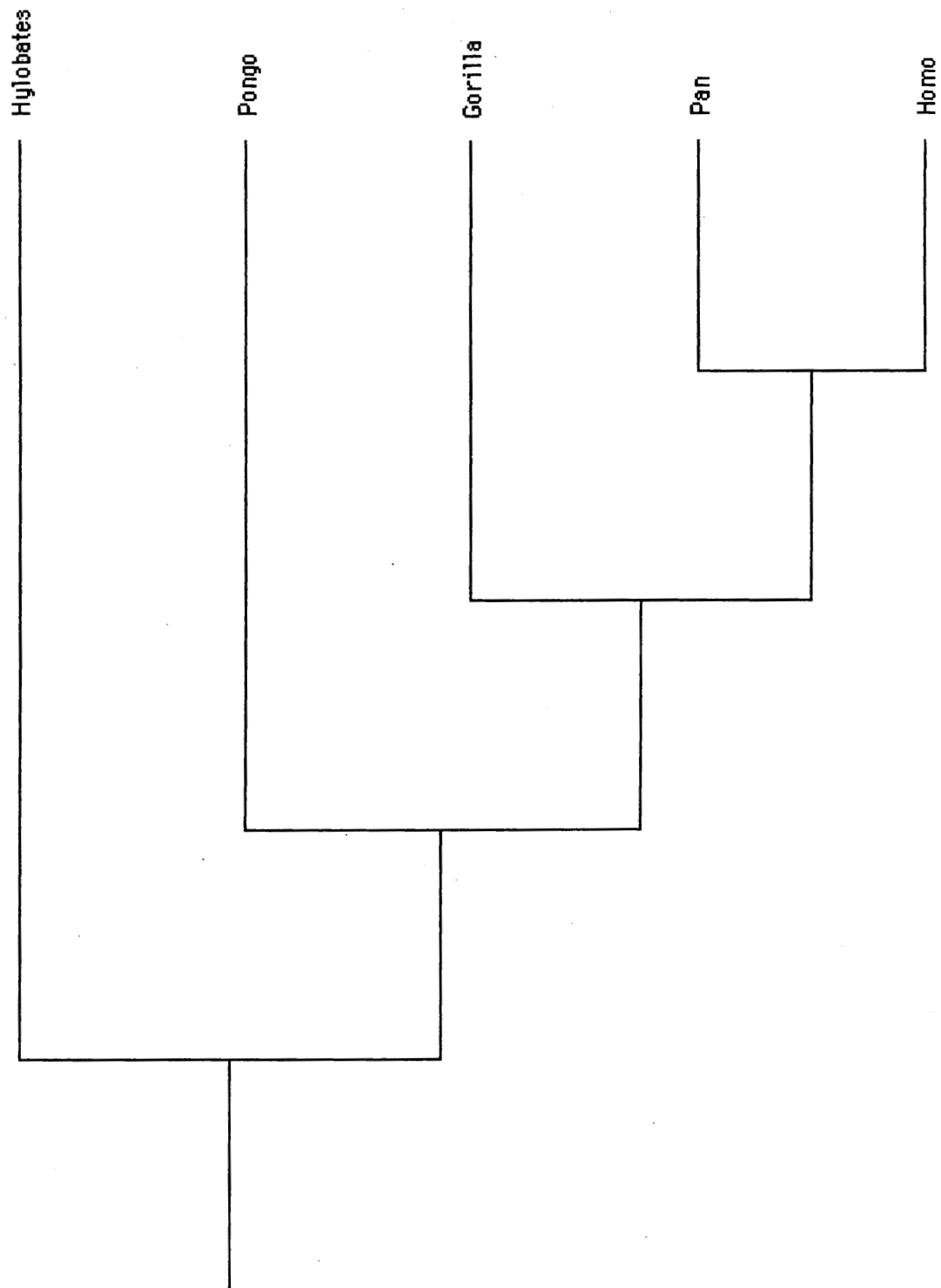


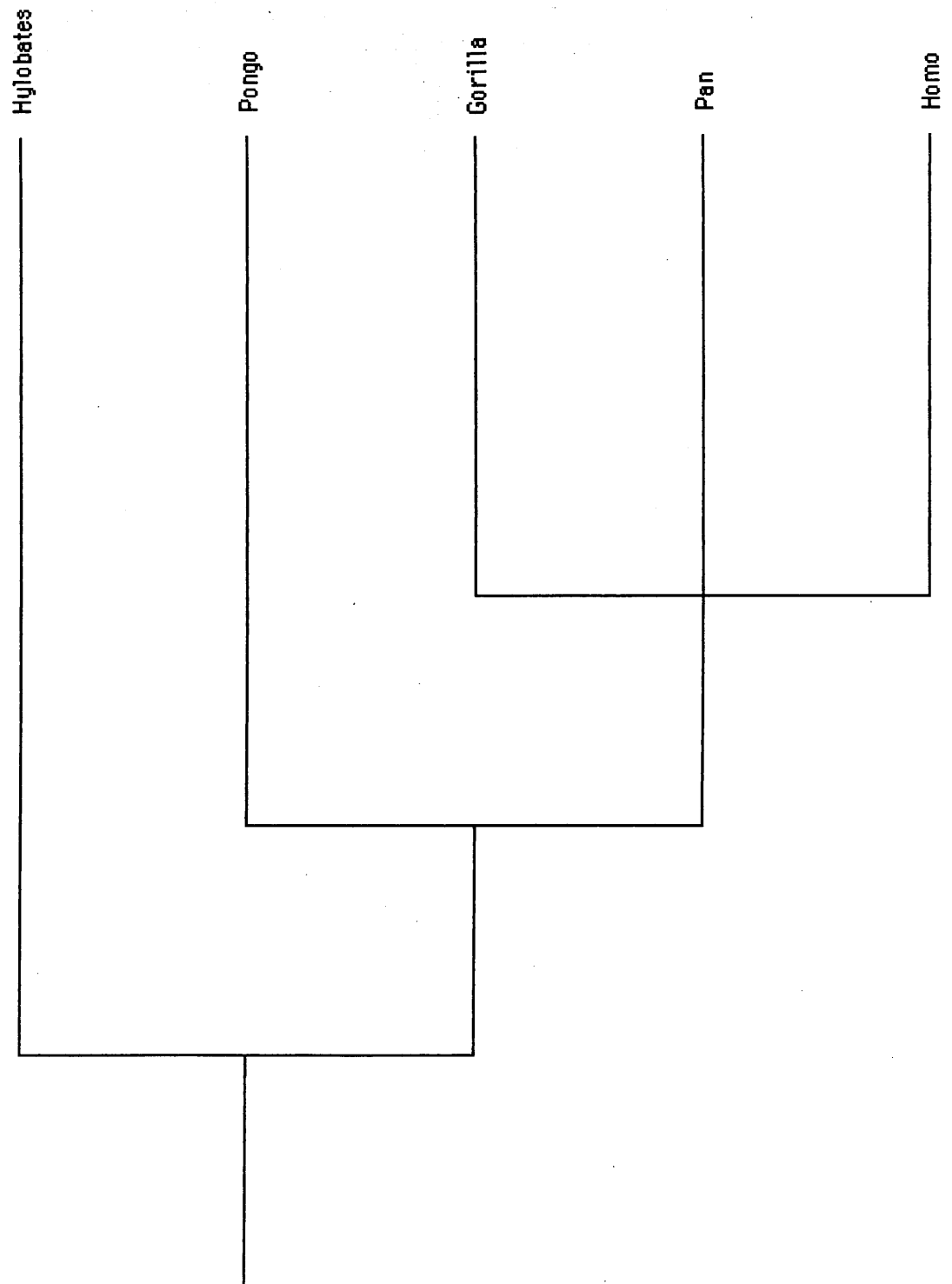
Figure 4.1. Tree 1. Consensus molecular tree.



Treelength: 293  
CI: 0.65  
RI: 0.34

Figure 4.2. Tree 2. Most parsimonious tree generated by Dataset A (155 characters).





Treelength: 213+  
CI: 0.78  
RI: 0.60

Figure 4.3. Tree 3. Most parsimonious tree generated by Dataset B (114 characters).

As Dataset B consists mainly of skeletal and dental characters, it is possible that these anatomical structures are subject to more homoplasy than the soft tissue characters of Dataset A. Collard found cranial and dental characters to be unreliable in the reconstruction of cladistic relationships between catarrhine species and genera<sup>21</sup>.

#### **4.1.2 Second hypothesis**

The second hypothesis tested was whether different regions of the body differ in their ability to reconstruct the cladistic relationships between the genera.

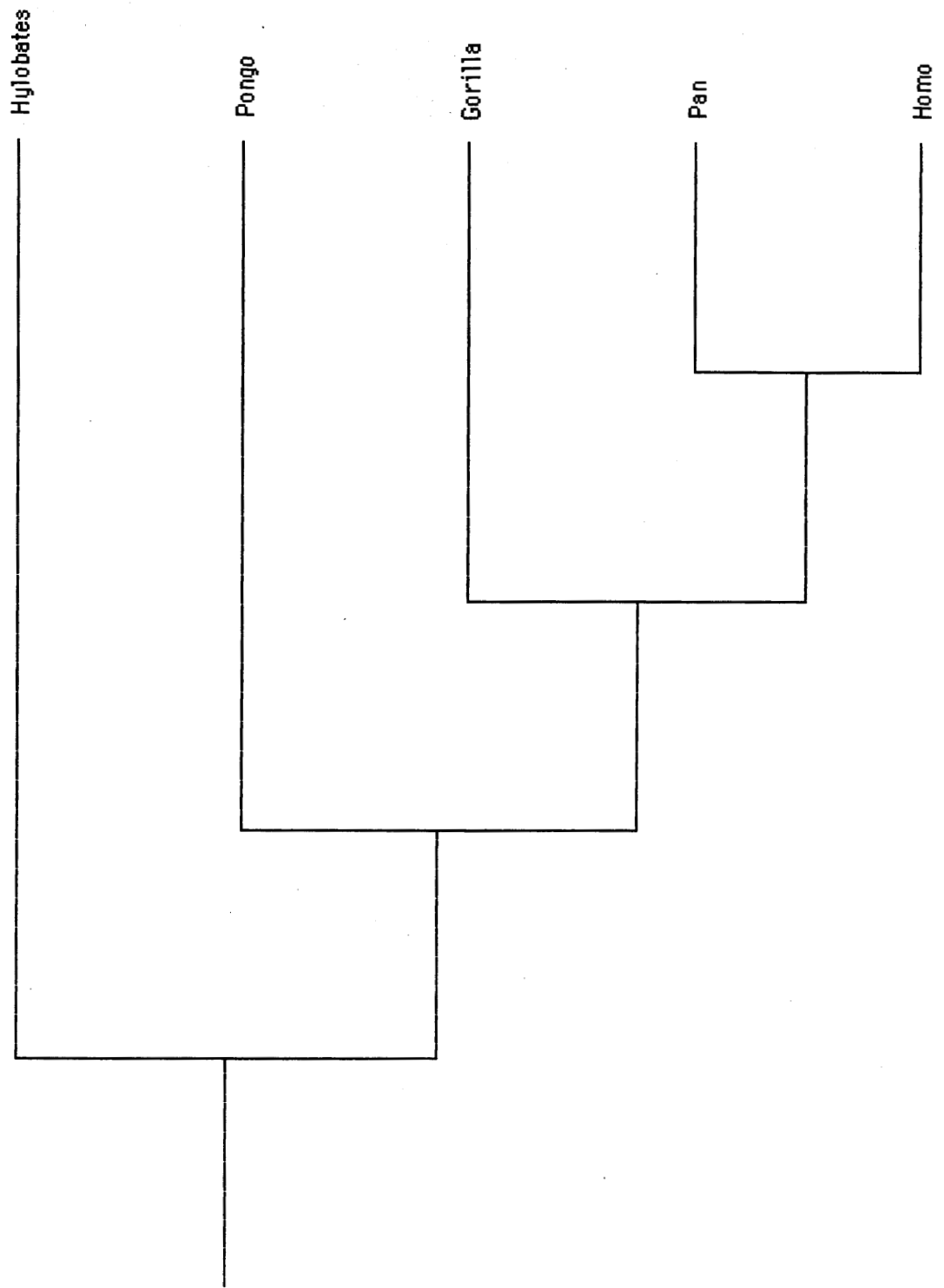
The results of the bootstrap analysis, and the length and fit measures for the most parsimonious cladograms of subsets A1 and A2 (after the exclusion of the uninformative characters) are shown below.

Of the original 71 characters of Subset A1, 15 were excluded as uninformative, while of the original 71 characters of the Subset A2, 16 characters were excluded as uninformative.

	A1 (upper limb)	A2 (lower limb)
Potential clade	Frequency	Frequency
<i>Pan-Homo</i>	69	73
<i>Gorilla-Pan-Homo</i>	74	15
<i>Pongo-Pan-Homo</i>	12	8
<i>Gorilla-Homo</i>	13	5
<i>Pongo-Pan</i>	10	4
<i>Pongo-Gorilla</i>	5	69
<i>Pongo-Gorilla-Homo</i>	>1	5
<i>Pongo-Gorilla-Pan</i>	10	20
<i>Pongo-Homo</i>	>1	>1
<i>Gorilla-Pan</i>	9	>0.1
Tree length	102	100
CI	0.65	0.65
RI	0.36	0.36

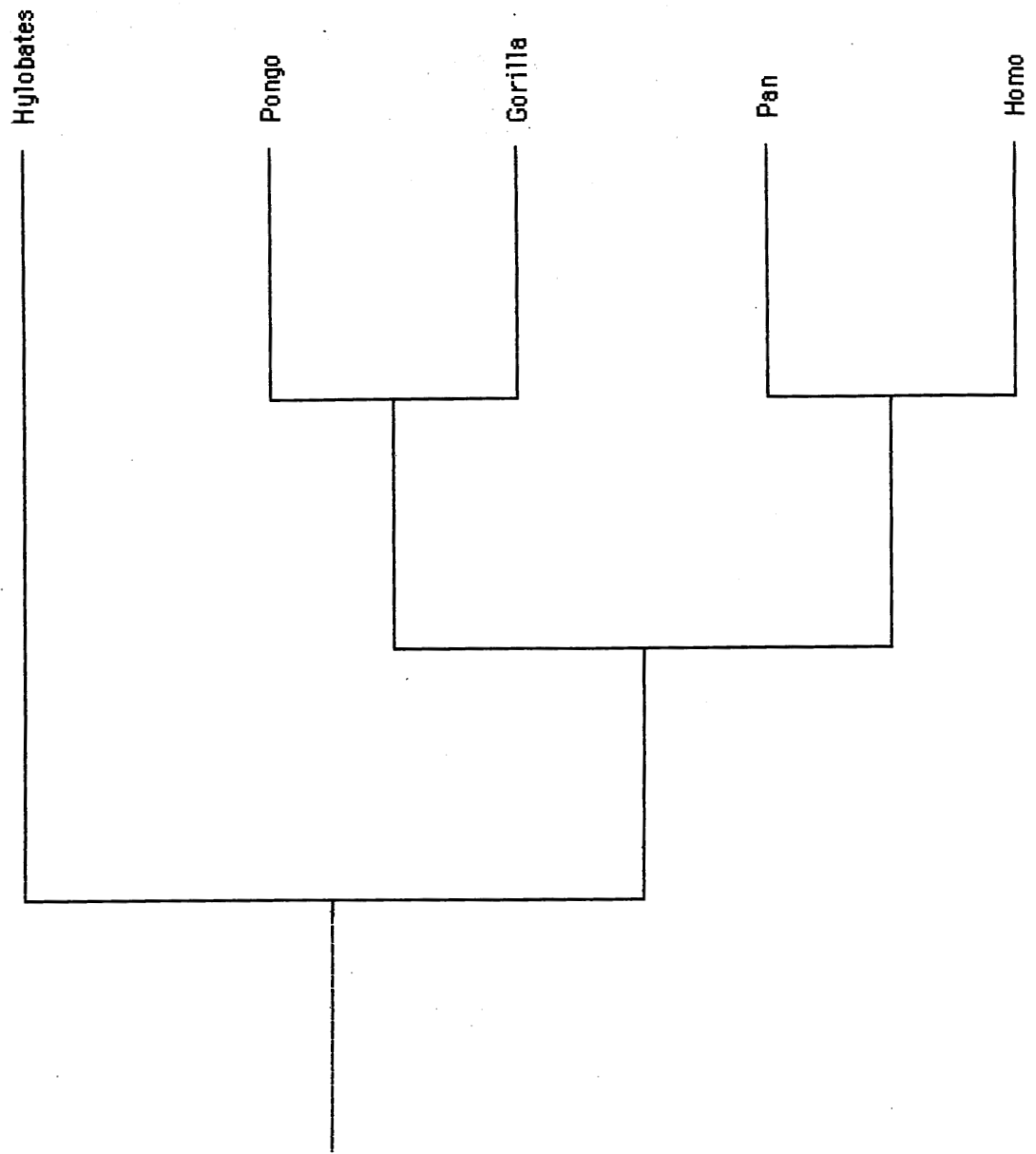
**Table 4.2. Bootstrap values (%) for subsets A1 and A2, with tree lengths and CI for corresponding trees 4 (56 characters) and 5 (55 characters). CI = Consistency index, RI = Retention index.**

The bootstrap analysis does show a difference in the clades reconstructed using the two regional subsets. Both subsets provide good support for the *Pan-Homo* clade, although A1 provides a bootstrap value slightly less than the 70% level required for strong support (69%). A2 shows a slightly higher bootstrap value (73%) than for A1. However, Subset A1 also provides strong support for the African ape-*Homo* clade (74%), which is not the case for Subset A2 (20%).



Treelength: 102  
CI: 0.65  
RI: 0.36

Figure 4.4. Tree 4. Most parsimonious tree generated by subset A1 (56 characters).



Treelength: 100  
CI: 0.65  
RI: 0.36

Figure 4.5. Tree 5. Most parsimonious tree generated by subset A2 (55 characters).

Additionally, Subset A2 gives good support, although at less than 70%, to a *Pongo-Gorilla* clade (69%). This grouping is not favoured by the consensus molecular cladogram.

This may suggest that with regard to *Pongo* and *Gorilla* the lower limb is subject to different levels of homoplasy than the upper limb, the "true" cladistic relationships being masked by convergence, reversals or parallelisms.

## 4.2 RESULTS OF BRANCH SWAPPING WITH MACCLADE

### 4.2.1 Dataset A

Relationships	Tree length (steps)	Number of extra steps	CI; RI
<i>Pan-Homo</i>	293	0	0.65; 0.34
<i>Pongo-Pan-Homo</i>	301	8	0.63; 0.28
<i>Gorilla-Homo</i>	304	11	0.63; 0.26
<i>Pongo-Gorilla</i>	306	13	0.62; 0.25
<i>Gorilla-Pan</i>	307	14	0.62; 0.25
<i>Pongo-Pan</i>	309	16	0.61; 0.23
<i>Pongo-Homo</i>	311	18	0.61; 0.22
<i>Pongo-Gorilla-Pan</i>	312	19	0.61; 0.21
<i>Pongo-Gorilla-Homo</i>	313	20	0.61; 0.21

Table 4.3. Results of branch-swapping within the Hominoidea, based on dataset A and tree 2.

CI = Consistency index, RI = Retention index.

Based on branch-swapping, the following phylogenetic groupings are all within 5% of the tree length of the most parsimonious tree: *Pongo-Pan-Homo*, *Gorilla-Homo*, *Pongo-Gorilla* and *Gorilla-Pan*. Therefore, the two alternative groupings within the African ape-*Homo* clade are not significantly less supported by the tree topology than

the preferred *Pan-Homo* clade, although *Gorilla-Pan* appears to be less supported than *Gorilla-Homo*.

#### 4.2.2 Upper limb

Relationships	Tree length (steps)	Number of extra steps	CI; RI
<i>Pan-Homo</i>	102	0	0.65;0.36
<i>Gorilla-Homo</i>	105	3	0.63;0.30
<i>Gorilla-Pan</i>	106	4	0.62; 0.29
<i>Pongo-Pan-Homo</i>	107	5	0.62; 0.27
<i>Pongo-Gorilla-Pan</i>	108	6	0.61; 0.25
<i>Pongo-Pan</i>	109	7	0.61; 0.23
<i>Pongo-Gorilla</i>	113	11	0.58; 0.16
<i>Pongo-Gorilla-Homo</i>	113	11	0.58; 0.16
<i>Pongo-Homo</i>	115	13	0.57; 0.13

**Table 4.4. Results of branch-swapping within the Hominoidea, based on Subset A1 and tree 4. CI = Consistency index, RI = Retention index.**

Similarly to the branch-swapping results for Dataset A, the two main alternative groupings among the Hominoidea are less than 5% from the tree length of the most parsimonious tree. However, *Pongo-Gorilla*, which in Dataset A was within the 5% boundary, is significantly less supported by the upper limb Subset A1.

### 4.2.3 Lower limb

Relationships	Tree length (steps)	Number of extra steps	CI; RI
<i>Pongo-Gorilla</i>	100	0	0.65; 0.36
<i>Pan-Homo</i>	103	3	0.63; 0.31
<i>Pongo-Pan-Homo</i>	104	4	0.63; 0.29
<i>Pongo-Gorilla-Homo</i>	107	7	0.61; 0.24
<i>Gorilla-Homo</i>	109	9	0.60; 0.20
<i>Pongo-Pan</i>	110	10	0.59; 0.18
<i>Pongo-Gorilla-Pan</i>	110	10	0.59; 0.18
<i>Pongo-Homo</i>	111	11	0.59; 0.16
<i>Pan-Gorilla</i>	112	12	0.58; 0.15

**Table 4.5. Results of branch-swapping within the Hominoidea, based on Subset A2 and tree 5. CI = Consistency index, RI = Retention index.**

Despite the appearance of a *Pongo-Gorilla* clade as the most parsimonious reconstruction for Subset A2, *Pan-Homo* and *Pongo-Pan-Homo* are within 5% of the tree length. The two main alternative groupings within the African ape-*Homo* clade, *Pan-Gorilla* and *Gorilla-Homo*, are significantly less supported by lower limb Subset A2.

## 4.3 SYNAPOMORPHIES FOR *HOMO*, *PAN* AND *GORILLA*

### 4.3.1 Dataset A

Using Dataset A, there are 60 synapomorphies for African apes and *Homo*, of which a total of 38 synapomorphies have a CI of 1.0, as follows:

1 (0→1), 10 (0→2), 16 (0→1), 32 (0→1), 33 (0→1), 58 (0→2), 59 (0→1), 62 (0→1), 66 (1→0), 69 (0→1), 71 (0→1), 82 (0→1), 83 (0→1), 86 (0→1), 96 (0→1), 99 (0→2), 101 (0→1), 103 (0→1), 110 (0→1), 113 (0→1), 120 (0→2), 121 (0→1),



123 (0→2), 129 (0→1), 131 (1→0), 140 (0→1), 142 (0→1), 145 (0→1), 147 (0→1),  
153 (0→3), 161 (0→2), 163 (0→1), 166 (0→1), 173 (0→1), 174 (0→1), 179 (0→1),  
184 (0→1), 189 (0→1) and 198 (0→2).

In addition, there are seven other relatively good synapomorphies, but with a CI of less than 1.0. They are characters 13 (0→1, 0.67), 102 (0→1, 0.67), 108 (0→1, 0.67), 124 (0→1, 0.67), 125 (0→2, 0.67), 156 (0→2, 0.67) and 196 (0→2, 0.67).

This clade is well supported by dataset A, with a bootstrap value of 85%.

Shoshani *et al.* also found this clade well supported, quoting a bootstrap value of 99%<sup>158</sup>. However, having rerun their dataset (Dataset B), I have found a bootstrap value of 96% for the African ape-*Homo* clade.

Of the characters with a CI of 1.0, some appear more informative and will be discussed by region.

#### 4.3.1.1 Lower limb and pelvic girdle

Characters that appear to be particularly informative for the African ape-*Homo* clade are character 1 (state 1), piriformis sometimes unfused with gluteus medius; character 16 (state 1), the absence of the insertion of adductor magnus into the inferior border of the insertion of quadratus femoris; character 32 (state 1), peroneus brevis may insert onto the second and third phalanges of digit V; and character 189 (state 1), psoas minor innervated by the femoral nerve.

*Piriformis* in *Homo* rotates the extended thigh laterally, but abducts the flexed thigh<sup>193</sup>, also playing a role in extension of the thigh<sup>51</sup>. Actions produced by *piriformis* in all apes are lateral rotation and abduction at the hip<sup>160</sup>. It appears that

piriformis in apes, including African apes, has a reduced role in extension of the thigh. In human bipedal gait, extension of the hip is important at the midstance phase of the stride when the whole weight of the body is over the supporting foot and at toe-off when the body weight passes over the hallux.

The anterior fibres of *gluteus medius* in *Homo* act as a medial rotator and flexor of the hip, and the posterior part as a lateral rotator and extensor of the hip, while the whole muscle can function as an abductor<sup>51, 64</sup>. Along with *gluteus minimus*, *gluteus medius* acts to counteract the dipping of the pelvis on the unsupported side during walking, running and the carrying of loads in one hand<sup>64, 106</sup>, and is inactive during symmetrical standing<sup>193</sup>. In apes, *gluteus medius* is an important thigh extensor, and also acts in abduction and medial rotation of the thigh at the hip joint<sup>1, 160, 201</sup>. In African apes, the *gluteus medius* is relatively much larger than the *gluteus medius* of *Homo*, reflecting its increased importance in African apes as an extensor of the thigh at the hip joint<sup>1</sup>.

That these two muscles are sometimes unfused in African apes and *Homo* may reflect the necessity for a greater range of independent muscular action at the hip joint, enabling the muscles to respond at slightly different times. The motor point for *gluteus medius* is adjacent to the superior margin of the *piriformis* in *Homo*<sup>14</sup> while other studies on the innervation of the two muscles suggest that *piriformis* consists of a caudal element of *gluteus medius*, and possibly also a caudal element of *gluteus minimus*<sup>3</sup>. The inconsistent appearance of this feature leads to the supposition that either this is a derived feature relative to the Asian apes, and thus an adaptation for terrestrial locomotion as opposed to the mainly arboreal locomotor activity of the Asian apes, or that it is a symplesiomorphic feature, perhaps related to vertical

climbing activity, which was subsequently lost in *Pongo* and *Hylobates*. However, a similar separation of functionally-related components, in this case of the gluteus minimus into the ventrolateral scansorius and the caudomedial gluteus minimus component, occurs in *Pongo*<sup>159</sup>. It seems unlikely that *Pongo*, with its predisposition toward a flexible hip joint, would have secondarily lost one adaptation for freedom of movement, only to develop another, very similar one. Therefore, as a synapomorphy of African apes and *Homo*, the lack of fusion between piriformis and gluteus medius indicates either a adaptation for terrestrial locomotion, or to a variety of arboreal activity not shown by *Pongo*.

*Adductor magnus* in *Homo* is essentially a synergist and controller of posture<sup>105, 193</sup>, and a powerful adductor, particularly in crossing the legs<sup>51</sup>. The part that reaches the medial epicondyle is responsible for medial rotation of the laterally rotated and flexed leg<sup>26, 51, 131</sup> and extension of the thigh at the hip joint, also showing activity during flexion and extension of the knee<sup>48</sup>. However, other authors state that in *Homo* the adductor magnus has lost its function of thigh extension and has become exclusively an adductor<sup>125</sup> due to the downward orientation of the human ischium, unlike the posteriorly-protruded ischium of nonhuman primates (NHPs). Gluteus maximus has taken over the thigh extension function in *Homo*<sup>199</sup>. In apes, as in *Homo*, adductor magnus functions as a thigh extensor, powerful adductor and medial rotator of the thigh<sup>124, 160</sup>. However, Sigmon also states that in apes the long head of adductor magnus is responsible for lateral rotation of the thigh, while the short head also acts as a flexor of the thigh<sup>160</sup>. In human bipedal gait at heel strike the hip is flexed, the knee extended and the leg laterally-rotated. The adductor muscles then pull the weight of the body over the supporting limb.

*Quadratus femoris* in *Homo* is a strong lateral rotator and adductor of the thigh<sup>51</sup>.

Sigmon however, states that in apes *quadratus femoris* is an abductor and a lateral rotator of the thigh at the hip joint<sup>160</sup>. The apparent disparity in function between humans and apes may be real, or could be the result of typographic error.

In a similar fashion to character 1, this character reveals a lack of fusion between two muscles acting at the hip joint in African apes and *Homo*, once more indicating a greater range of independent muscular action at the joint.

*Peroneus brevis* in *Homo* may prevent excessive inversion of the foot, relieving the stress on the lateral part of the interosseous talocalcaneal, lateral talocalcaneal and calcaneofibular ligaments. It participates in the eversion of the foot, and may help to steady the leg on the foot<sup>193</sup>, pronating and plantar flexing the foot along with *peroneus longus*<sup>61</sup>, and limiting ankle dorsiflexion, particularly in fast pace running<sup>128</sup>. In *Homo* *peroneus brevis* is active during the second half of the stance phase when weight is transferred onto the anterior part of the foot and medially onto the ball of the foot<sup>50, 130, 166</sup>. However, in *Pan*, *peroneus brevis* is inactive in terrestrial locomotion but active in arboreal locomotion<sup>166</sup> and also during part of the stance and swing phases of bipedal locomotion<sup>50</sup>. Eversion of the foot in arboreal locomotion may control the transfer of weight to the anterior part of the foot between the opposed digit I and digit II<sup>166</sup>. Skeletal features such as a wide peroneal groove on the fibular malleolus<sup>90</sup> and a large peroneal trochlea on the calcanei<sup>69, 71</sup> indicate that the lateral crural musculature was well-developed in *Australopithecus afarensis*, with the possibility that the peroneal musculature in this hominid may have provided a somewhat greater proportion of plantarflexion force than in modern *Homo*<sup>70</sup>. Based on the above, however, there can be no justification for assuming from this either a

terrestrial bipedal gait as in modern *Homo*, or a tendency toward arboreal locomotion, as in modern *Pan*.

The consistent insertion of peroneus brevis onto the middle and distal phalanges of digit V in African apes and *Homo*, in contrast to the inconstant insertion in Asian apes, may indicate an increased reliance on the muscle, either in an arboreal, or a terrestrial locomotor configuration.

The innervation of *psoas minor* by a muscular branch of the femoral nerve in African apes and *Homo*, or rather, the absence of an independent muscular branch of the femoral nerve for *psoas minor* in Asian apes, may indicate the greater importance of *psoas minor* in the former group, as the emergence of a muscle as a separate entity brings about the formation of separate nerve to supply it<sup>100</sup>. However, this does not seem to be the case, as in *Homo* *psoas minor* is present as a separate muscle in less than half of all subjects<sup>51</sup>. Quite possibly, rather than being truly absent, the muscle has simply fused with *psoas major*, as occurs in *Hylobates*<sup>160</sup>. In *Homo*, and in all apes, *psoas minor* flexes the trunk in the lumbar region<sup>1, 160</sup>. *Psoas major* is involved in lateral bending, and with the iliopsoas, flexes the thigh and bends the trunk forward<sup>12, 51, 138</sup>. It is possible that the increased level of fusion of the *psoas* muscles in *Homo* represents an increased requirement for anteroposterior stabilization of the trunk, and that the separate femoral-based nerve supply pertains to those cases where the muscle remains separate, as in African apes.

#### 4.3.1.2 Upper limb and shoulder girdle

Characters that appear to be particularly informative for the African ape-*Homo* clade are character 59 (state 2), palmaris brevis present; character 62 (state 1), the

humeral head of flexor digitorum superficialis originates from the intermuscular septum; character 66 (state 0), palmaris longus sometimes absent; character 71 (state 1), flexor pollicis longus originates from the anterior radius and the interosseous membrane; character 82 (state 1), a slip from the extensor digitorum tendon for digit IV to digit II is present; character 83 (state 1), coracobrachialis originates from the intermuscular in some specimens; character 96 (state 1), extensor pollicis brevis originating from the ulna and interosseous membrane; character 120 (state 1), subclavius originates from the first rib only; character 145 (state 1), lateral thoracic artery usually originates directly from the axillary artery; character 147 (state 1), presence of a supreme thoracic artery; character 173 (state 1), radial artery enters the palm at the dorsum of the first interosseous space, rather than the second interosseous space; character 174 (state 1), superior ulnar collateral artery originates from the brachial artery; and character 179 (state 1), the median nerve supplies 3.5 rather than 2.5 digits.

*Palmaris brevis* in *Homo* wrinkles the skin on the ulnar side of the palm and deepens the hollow in the palm by accentuating the prominence of the hypothenar eminence, also called cupping<sup>193</sup>. This is important in the squeeze grip, for grasping cylindrical objects, the spherical grip, where large spherical objects are held against the palm by the flexed thumb and fingers, and the five-jaw chuck grip, where the tip of digit V must be finely adjusted to the size and shape of large objects<sup>1</sup>.

*Flexor digitorum superficialis* in *Homo* flexes first the middle, and then the proximal phalanges, flexes the wrist<sup>193</sup>, and is a weak flexor of the elbow<sup>51</sup>. Its action on the digits is impaired when the wrist is maximally flexed<sup>51</sup>. It may also provide some stabilization for the medial aspect of the elbow<sup>25</sup>. The short, tendonized flexor

digitorum superficialis of African apes, preventing full extension of the digits, has been viewed as a knuckle-walking adaptation<sup>179, 183</sup>, the short tendons preventing the wrist from buckling in the knuckle-walking posture by maintaining the metacarpophalangeal joints of digits II to V in the close-packed position of hyperextension with minimal muscle activity<sup>179</sup>. A tendency toward shortening of the flexor digitorum tendons has been noted in adult *Pongo* that have fist-walked for several years, while adult orangutans that retain palmigrade locomotion maintain the ability to fully extend the digits<sup>181</sup>. Others allege the shortened tendons of the digital flexors create a perpetual partial flexion of the digits that is useful in brachiation<sup>200</sup>. An origin from the intermuscular septum may provide a more extensive origin, and therefore provides stability<sup>20</sup> and spreads the force of the muscle over a wider area at origin. Flexor digitorum superficialis in *Homo* is responsible mainly for forceful flexion, while finer flexion movements are controlled primarily by flexor digitorum profundus<sup>73</sup>.

*Palmaris longus* is variably present in African apes and *Homo*, rather than constantly present as in Asian apes. In *Homo*, palmaris longus flexes the wrist and tenses the palmar aponeurosis<sup>193</sup>. Possibly with the increased importance of the long digital flexors, the wrist flexion function of palmaris longus is no longer essential. Certainly, a recent study observed that in 4/11 forearms in which the muscle was present, it was not recruited during wrist flexion<sup>33</sup>.

In *Homo*, *flexor pollicis longus* flexes the terminal phalanx of the thumb<sup>162</sup>, and may also abduct the thumb slightly in the radial direction<sup>51</sup>. In *Pan*, since the flexor pollicis longus is often non-functional, and flexor pollicis brevis acts only on the proximal phalanx, about half of all chimpanzees cannot flex the distal phalanx of the

thumb<sup>200</sup>. This suggests a selective pressure on *Homo* for the retention of flexor pollicis longus for manipulative ability, particularly with reference to tool making and tool use<sup>42</sup>, and a recent study finds that neural control of this muscle is more specialized than for the muscles controlling digit II<sup>58</sup>. The expanded origin in comparison with Asian apes, however, would suggest some similarity between the manipulatory abilities of the African apes and *Homo*.

In *Homo*, *extensor digitorum* is involved with the fine movements of the hand, and extends and spreads the digits at the metacarpophalangeal and interphalangeal joints, as in opening the hand to relax the grip in preparation for grasping. It is also an equal prime mover with the carpal extensors in extending the wrist<sup>91</sup>, and the strongest dorsiflexor of the wrist<sup>51</sup>. It tends to abduct digits II, IV and V as it extends them, but not so for digit III<sup>193</sup>. Architecturally, in *Homo* *extensor digitorum* is designed more for velocity and excursion than for force generation<sup>144</sup>. In knuckle-walking there is considerable hyperextension at the metacarpophalangeal joints of the four fingers<sup>179</sup>,<sup>180</sup>. It has been suggested that the increased size of *extensor digitorum* in *Pan* is related to the use of the extended proximal phalanges in quadrupedal terrestrial locomotion rather than to manipulation ability<sup>200</sup>.

Slips between the tendons of *extensor digitorum* are present in all apes. They may affect independent extension of the digits, so that in African apes and *Homo*, digits II, IV, and indeed V, all tend to extend simultaneously. Certainly, if one attempts to extend digit IV in isolation, it is impossible without first consciously flexing the remaining digits, particularly against resistance. From the author's own observations, the extensors of digit IV appears to be connected with those of digit V and digit III, but not of digit II. However, there is variation in these interconnections in *Homo*<sup>193</sup>,



particularly on the ulnar side of the hand<sup>142, 144</sup>. The greater interconnection of the digits in African apes and *Homo* does not appear to correlate with fine movements, but rather with the unified release of power grips in which the ulnar side of the hand acts as a component.

In *Homo*, *coracobrachialis* draws the arm anteriorly (flexion) and medially (adduction), especially from the posteriorly swung position. When the arm is raised from the side, it acts with the anterior fibres of the deltoid to prevent side-sway<sup>193</sup>. It also holds the head of the humerus in the joint socket<sup>51</sup>.

As the attachments of *coracobrachialis* are similar in apes, its action can be assumed to be fundamentally the same. An origin from the medial intermuscular septum will provide the same benefits as described for *flexor digitorum superficialis*, that is, the spreading of the force generated in the muscle over a wider area.

*Extensor pollicis brevis* in *Homo* extends and also abducts the thumb because of its close relationship with *abductor pollicis longus*<sup>51, 112, 162</sup>. The pollex takes no part in the knuckle-walking posture in *Pan*, and the increased size of the pollicial extensors in this species may be due to their role as supinators rather than to movements of the thumb itself<sup>200</sup>.

An expanded origin of *extensor pollicis brevis* could indicate the increased importance of this muscle in the African apes and *Homo*, although a recent study has found non-functional, or absent, *extensor pollicis brevis* muscles in 23% of human hands<sup>15</sup>. However, if Ziegler is right, this expanded origin may be homoplastic rather than synapomorphic. Alternatively, this suggests another factor in the similarity of the manipulative abilities of these taxa, and casts some doubt on the assertion of

Marzke *et al.* that skeletal evidence of tool use in fossil hominids will be in the regions of the hand stressed by, among others, the intrinsic muscles of the thumb<sup>98</sup>.

*Extensor indicis* in *Homo* extends digit II, and assists in dorsiflexion of the wrist and midcarpal joints<sup>51</sup>.

In African apes and *Homo*<sup>143</sup> *extensor indicis* inserts most frequently onto digit II alone, while in Asian apes it inserts most frequently onto digits II and III (*Pongo*) or digits II, III and IV (*Hylobates*). This appears to be a variation on the same mechanism as the interconnecting tendons of *extensor digitorum*, although in this case, it suggests that the importance of the independent extension of digit II has increased in the African apes and *Homo*, compared to Asian apes. In *Homo*, *extensor indicis proprius* is responsible for more than two-thirds of the extension of digit II<sup>142</sup> and may have a double tendon as a variant<sup>38</sup>. It may be that these two groups have independently arrived at different methods of producing this specialized extensor outcome. From another viewpoint, both these extensor muscles are also involved in dorsiflexion of the wrist in *Homo*<sup>51</sup>, and thus a reduction in the number of terminal tendons of *extensor indicis* could be seen as a reduction in its importance as a dorsiflexor, since *extensor digitorum* is the strongest dorsiflexor of the wrist in *Homo*, to become a specialized extensor for digit II. The similarity in the insertion of *extensor indicis* in African apes and *Homo*, as for *extensor pollicis brevis*, casts some doubt on the theory of skeletal evidence of tool use in fossil hominids of Marzke *et al.*<sup>98</sup>.

In *Homo*, *subclavius* pulls the point of the shoulder anteroinferiorly, and steadies the clavicle during movements of the shoulder by bracing it against the disc of the

sternoclavicular joint. However, the muscle is inaccessible to palpation and difficult to investigate by electromyography<sup>193</sup>.

The costal origin of subclavius is most extensive in hylobatids, less so in *Pongo*, and least of all in African apes and *Homo*. From a locomotor viewpoint, it might be suggested that a more extensive origin of subclavius is related to arboreal locomotion with habitual use of an elevated arm, particularly brachiation, where a greater degree of stability is required in the shoulder girdle. This does not, however explain why chimpanzees, who are modified brachiators, do not share this character with the Asian apes. The external appearance of the clavicle in apes shows that the chimpanzee clavicle is closest to the S-bend formation of the modern human clavicle<sup>146</sup>. Perhaps it is the high-stress use of arm-hanging beneath the bough rather than simply arboreal locomotion *per se* that separates the extensive costal origin of Asian apes, particularly hylobatids, from the minimal costal origin of the African apes and *Homo*.

In African apes and *Homo*, the *lateral thoracic artery* originates directly from the axillary artery, rather than as a branch of the thoracoacromial artery as in Asian apes. The latter origin may also be present as a variant in *Pan*. In *Homo*, this artery supplies serratus anterior, subscapularis and the pectoral muscles, and in females gives off lateral mammary branches<sup>193, 197</sup>.

The *supreme or superior thoracic artery* in *Homo* provides a partial supply for the pectoralis major<sup>117</sup>. This arterial branch appears to be absent from Asian apes.

The last two arterial characters may be explained as the result of an increase in the size and usage of a muscle, such as pectoralis major, producing an increase in the bloodflow to that structure, requiring larger and more numerous vessels<sup>95, 120</sup>.

The *radial artery* enters the palm at the dorsum of the first interosseous space in African apes and *Homo*, rather than the second interosseous space. It is the dominant vessel to the hand in *Homo*<sup>177</sup>. The incidence in *Homo* of the radial artery entering the dorsum of the second interosseous space, as in Asian apes, is around 16%<sup>110</sup>.

The *superior ulnar collateral artery* originates from the brachial artery in African apes and *Homo*, rather than from the profunda brachii as in Asian apes. In *Homo* it supplies the medial aspect of the arm<sup>72, 99</sup>.

The *median nerve* in *Homo* and African apes supplies 3½ rather than 2½ digits as in Asian apes. Despite its larger area of cutaneous supply<sup>68</sup>, and its innervation of the thenar muscles<sup>109</sup>, the median nerve in *Homo* is less important in grip strength and pinching movements than the ulnar nerve<sup>62</sup>. The artery that accompanies the median nerve is distributed to flexor digitorum superficialis in *Homo*<sup>132</sup>, while the muscular supply of the nerve involves pronator teres, flexor carpi radialis, flexor digitorum superficialis, palmaris longus and flexor digitorum superficialis, and the anterior interosseous nerve<sup>41</sup>.

#### **4.3.1.3 Others**

##### **4.3.1.3.1 Skin**

*Sternal glands* and glandular concentrations in many non-human primate species<sup>29, 37, 43, 92, 103, 104, 120</sup>. In *Pongo* a sternal gland is found chiefly in young males, and has been described as being in a stage of regressive evolution. In *Symphalangus* the

colouration of the sternal patch is produced by a glandular secretions staining the skin and can be removed. The fresh secretion is a pungent-smelling yellowish sticky substance, somewhat similar to human earwax. In the skin of the lateral chest, only sebaceous glands, attached to hair follicles, were observed. In contrast to this, the skin in the sternal region contained a conspicuous concentration of coiled tubular glands, thus forming a specialized glandular field. High secretory activity and especially strong body odour has been observed mainly on hot days and in arousal. Geissmann suggests that the sternal gland is derived from a gland used for marking behaviour, subsequently altering in function to converge with the independently evolved axillary gland of African apes and *Homo*<sup>37</sup>. Apocrine glands form the major element of the axillary organ, marked by transverse rows of hairs on the axillary surface. The apocrine glands producing a thicker secretion than the more widespread eccrine glands and are involved in temperature regulation by the evaporation of sweat<sup>193</sup>. Like the sternal gland of Asian apes, the axillary organ produces and propagates specific human odours<sup>102</sup>, and may have a similar function in African apes.

#### 4.3.1.3.2 Alimentary

In Asian apes, but not in African apes and *Homo*, *conical filiform papillae* of the tongue predominate in number over *cylindrical filiform papillae*. The author has been unable to find any references to possible functional differences between these forms of papillae.

#### 4.3.1.3.3 Genital

In *Homo*, *transverse rugae in the vaginal mucosa* are most pronounced on the posterior wall of the vagina, and near the vaginal orifice, particularly before

parturition<sup>193</sup>. These epithelial folds account in part for the ability of the vagina to distend. Stretching of the vaginal walls is caused by sexual intercourse, and increased by parturition. Repeated parturition leads to obliteration of the rugae, causing the vagina to become smooth-walled. Even in nulliparous women, the vagina loses its rugae after the menopause<sup>49</sup>.

Well-developed transverse vaginal rugae are present in *Homo* and African apes, and those in *Homo* are even more developed than in African apes. The rugae are practically absent from Asian apes, although they may be more developed in fetal *Hylobates*.

As a tentative suggestion, if the expansive ability of the vagina is a selective factor, it may be related to neonatal size. Many studies have correlated pelvic dimensions with neonatal dimensions<sup>75, 76, 78, 79, 149, 172</sup>, but none have examined the role of soft tissues in the birth process.

Gibbons have larger infants than great apes, with *Homo* occupying an intermediate position. In fact, relative neonatal head size within the Hominoidea forms two groups, *Homo* and *Hylobates*, and great apes. However, in *Gorilla*, the main diameters of the female pelvic canal are remarkably large compared with the head dimensions of the neonate, permitting easy delivery<sup>75, 76, 77, 79</sup>. This does not appear to support a correlation between transverse rugae and increased expansion ability of the vagina. Nor do penile dimensions appear to be a factor (see 3.6.5.2.1.5.1). Average penis length in adult *Homo* is 13 cm, while penis lengths of up to 14 cm have been reported for *Pan* and *Gorilla*, up to 9 cm in *Pongo*, and up to 2 cm in hylobatids. A far larger sample size is required, especially for the Asian apes, including a range of ages and parities, before any conclusions can be drawn on the function of transverse vaginal rugae.

#### 4.3.2 Upper limb

Having analysed the Subset A1 of 71 characters, there are 24 characters synapomorphic for African apes and *Homo*, of which there are 17 characters synapomorphic for African apes and *Homo* with a CI of 1.0.

They are: 58 (0→2), 59 (0→1), 62 (0→1), 66 (1→0), 69 (0→1), 71 (0→1), 82 (0→1), 83 (0→1), 86 (0→1), 96 (0→1), 99 (0→2), 161 (0→2), 163 (0→1), 166 (0→1), 173 (0→1), 174 (0→1) and 184 (0→1).

The clade is well supported by Subset A1, with a bootstrap value of 74%.

#### **4.3.3 Lower limb**

Subset A2 shows only weak support for the African ape-*Homo* clade, with a bootstrap value of 20%.

However, this subset does show relatively strong support for a *Pongo-Gorilla* clade, with a bootstrap value of 69%.

Of the 71 characters involved in the subset, there are 23 synapomorphies for this *Pongo-Gorilla* clade, of which 12 have a CI of 1.0.

They are: 11 (0→1), 23 (0→1), 31 (0→1), 35 (0→1), 43 (0→1), 47 (0→2), 48 (0→1), 49 (0→2), 51 (0→2), 150 (0→1), 154 (0→1) and 155 (0→3).

There is an additional synapomorphic character with a relatively good CI, but less than 1.0; this is 156 (0→1, CI = 0.67).

Nine of these apparently good synapomorphies for *Pongo* and *Gorilla* deserve some investigation.

##### **4.3.3.1 Putative synapomorphies for *Pongo* and *Gorilla***

These are character 23 (state 1), absence of an origin of the short head of biceps femoris from the lateral intermuscular septum; character 31 (state 1), absence of an origin for peroneus longus from the lateral tibial condyle; character 35 (state 1),

absence of a tendon of extensor digitorum brevis to digit V; character 48 (state 1), presence of a separate opponens hallucis; character 49 (state 2), presence of a separate abductor os metatarsi digiti minimi; character 51 (state 2), origin of the first dorsal interosseous from the medial cuneiform; character 150 (state 1), absence of the anastomosis between the perforating branch of the peroneal artery with the anterior lateral malleolar artery; character 154 (state 1), absence of the inferior medial and inferior lateral genicular branches of the popliteal artery; and character 155 (state 3), the medial femoral circumflex artery originates from the femoral artery.

In *Homo*, *biceps femoris* flexes the leg on the thigh, and draws the trunk upright against gravity when it is raised from the stooping position. With a semi-flexed knee, *biceps femoris* can act as a lateral rotator of the leg. It also laterally rotates the thigh when the hip is extended<sup>51, 193</sup>. It is possible that *biceps femoris* can produce movement at either the hip or the knee whilst simultaneously offering no resistance to the antagonistic movement of the other joint<sup>96</sup>. During bipedal gait, near the end of the legs swing the hamstrings, including *biceps femoris*, contract to stop it and the foot is planted<sup>89</sup>. In all apes, the long head functions as a thigh extensor and knee extensor, also laterally rotating the thigh, while the short head is a knee flexor in all apes<sup>160</sup>.

Assuming that the molecular consensus tree is accurate, the lack of an origin from the intermuscular septum in these two great apes must be the result either of homoplasy, or of symplesiomorphy. In the former case, the loss of the origin from the septum must be the result of functional convergence. In the latter case, it is then the possession of such an origin that has been independently acquired in the *Pan-Homo* clade and the hylobatids, while *Pongo* and *Gorilla* retain the ancestral trait.



Assuming that an origin from the intermuscular septum is a result of the increased importance of that muscle, then why would the biceps femoris, particularly the short head, be reduced in *Pongo* and *Gorilla* or conversely, enlarged in *Homo*, *Pan* and the hylobatids? It has been stated that biceps femoris is particularly large, relative to the anterior femoral musculature, in terrestrial quadrupeds<sup>44</sup>, but this would not account for its reduction in *Gorilla*, the most terrestrial of all extant apes. An alternative function for biceps femoris is the lateral stabilization of the knee<sup>53</sup>, which may well be important in extended leg positions such as bipedal standing. However, all hominoids are known to stand bipedally for at least short periods, and in humans at least, biceps femoris is silent during symmetrical standing, although any action that carries the line of body weight in front of the transverse axis of the hip joints, such as forward arm raising, forward sway at the ankle joint, or forward bending at the hips, is accompanied by strong contraction of biceps femoris<sup>193</sup>. Injury to the short head of biceps femoris in *Homo* causes an anterior translation instability in the flexed knee, where the tibia can be pulled anteriorly<sup>174</sup>. In *Pan*, the short head of biceps femoris is active during the stance phase of climbing when the knee is extended, and also during the stance and swing phases of bipedal walking with a flexed knee<sup>65</sup>.

*Peroneus longus* in *Homo* can evert and dorsiflex the foot, and may help to steady the leg on the foot<sup>193</sup>, although the latter function decreases with increased speed<sup>88</sup>. There is little or no peroneal activity in standing, and peroneus longus maintains the concavity of the foot at take-off and in tip-toeing<sup>193</sup>. It also aids plantar flexion<sup>51, 61</sup> and abducts the forefoot in the transverse plane<sup>176</sup>. It maintains the first metatarsal in an adducted position in *Homo*<sup>13</sup>. In *Homo* peroneus longus is recruited during the support phase of walking, usually just after midphase. Although peroneus longus is

active during part of the support phase in some bipedal steps of *Pan* and *Hylobates*, this muscle is also frequently recruited during swing phase<sup>50</sup>.

The absence of an origin for peroneus longus from the lateral tibial condyle is another feature that appears to be either derived separately in *Pan-Homo* and hylobatids, or to be homoplastically lost in *Pongo* and *Gorilla*. In an interesting aside, there appears to be a functional relationship between the muscles of mastication, and the peroneus longus and gastrocnemius. Artificially induced alteration in occlusion produces marked changes in the activity of both these muscles, but not in tibialis anterior. This is a consequence of complex nervous reflexes<sup>192</sup>. Is it possible that similarities in the masticatory complexes of *Pongo* and *Gorilla*<sup>127, 175, 196</sup> are responsible for this observed similarity in the origin of peroneus longus?

*Extensor digitorum brevis* in *Homo* assists in the dorsiflexion of digits II to IV, also acts on only the first phalanx of digit I<sup>193</sup>. It plays a major role in stabilizing posture<sup>141</sup>.

The absence of a tendon of extensor digitorum brevis to digit V, found commonly in *Pongo* and *Gorilla*, also occurs in *Homo* as a variant<sup>193</sup>.

In *Homo*, *opponens hallucis* corresponds to the part of adductor hallucis that inserts onto M1<sup>193</sup>. Adductor hallucis in *Homo* is a tensor of the plantar arches, also adducting digit I and may then plantar flex the proximal phalanx of digit I<sup>51</sup>.

Adductor hallucis obliquus is one of the largest intrinsic foot muscles in *Homo* indicating its functional importance<sup>66</sup>.

A separate opponens hallucis is not exclusive to *Pongo* and *Gorilla*, being found as a variant in all other hominoids, including *Homo*, in latter of which, opposition of the hallux is no longer part of the foot movement repertoire. Despite the obvious function of this muscle in opposition of the hallux, a reduced hallux is normally present in *Pongo*<sup>188</sup>, and has been reported in a lowland gorilla, suggesting a similar hereditary trend<sup>45</sup>.

The *abductor os metatarsi digiti minimi* corresponds in *Homo* to the part of abductor digiti minimi that originates from the lateral calcanean process and inserts onto the tip of the tuberosity of MV<sup>193</sup>. Abductor digiti minimi in *Homo* supports the arch of the foot, plantarflexes digit V and acts to a small extent as an abductor<sup>51</sup>.

The presence of this muscle separate from abductor digiti minimi may reflect an increased grasping potential of the fibular side of the foot in *Pongo* and *Gorilla*, or alternatively, a reduced grasping function in the other hominoids. The variable presence of this muscle as a separate entity in *Homo* represents a 'throwback' to this prehensile foot condition, suggesting that with a larger sample of ape material, a variable incidence of abductor os metatarsi digiti minimi may also be revealed.

The *first dorsal interosseous* in *Homo* is an abductor, also working with the plantar interossei as plantar flexors at the metatarsophalangeal joint<sup>51</sup>. According to its innervation it also contains elements derived from flexor digitorum brevis in *Homo*<sup>4</sup>.

The medial cuneiform, to which the first dorsal interosseous attaches in *Pongo* and *Gorilla*, shows more morphological differences between humans and apes than the other cuneiforms, specifically the facet for MI on the anterior surface of the human medial cuneiform is markedly different from that of apes with prehensile great toes.

The medial edge of the human joint projects further posteriorly than the lateral edge, the opposite plane to apes. The opposite condition in apes accentuates the abducted position of digit I<sup>1</sup>.

The absence of the anastomosis between the *perforating branch of the peroneal artery* with the *anterior lateral malleolar artery*, and the absence of the *inferior medial genicular* and *inferior lateral genicular branches of the popliteal artery* may reflect the increased importance of the structures supporting the knee joint and the ankle in *Pan-Homo* and the hylobatids. The inferior lateral genicular artery supplies the lateral femoral condyle, in combination with the superior lateral genicular artery, in *Homo*<sup>129</sup>.

The origin of the *medial femoral circumflex artery* from the femoral artery can be seen as part of a process whereby the artery originates progressively more distally. Thus, in hylobatids it originates from the external iliac artery, in *Pongo* and *Gorilla* from the femoral artery, and in *Homo* from the profunda femoris. However, in *Pan* the origin varies between the profunda femoris, as in *Homo*, and the external iliac as in *Hylobates*. In addition, as a variant in *Homo* the medial femoral circumflex may originate from the femoral artery, as in *Pongo* and *Gorilla*<sup>193</sup>. Therefore, although there appears to be a phylogenetic distal progression of the origin of the medial femoral circumflex artery, it is by no means clear-cut.

#### 4.4 SYNAPOMORPHIES FOR *HOMO* AND *PAN*

##### 4.4.1 Dataset A

Based on dataset A, there are fifty-two synapomorphies for the *Homo-Pan* clade, of which 30 have a CI of 1.0.

They are characters 5 (0→1), 29 (0→1), 34 (0→2), 36 (0→1), 41 (0→1), 43 (0→1), 45 (0→1), 51 (2→1), 52 (0→1), 88 (0→1), 93 (0→1), 100 (1→2), 115 (0→1), 116 (2→1), 123 (2→3), 126 (1→2), 131 (0→2), 138 (1→2), 139 (2→1), 140 (1→2), 155 (3→1), 157 (0→1), 165 (0→1), 170 (0→1), 172 (0→1), 175 (0→1), 182 (0→1), 193 (0→1), 195 (0→1) and 199 (0→1).

In addition, there are five other relatively good synapomorphies with a CI less than 1.0. They are characters 30 (0→1, CI = 0.67), 73 (0→1, CI = 0.67), 76 (0→1, CI = 0.67), 146 (0→1, CI = 0.67), 178 (0→1, CI = 0.67).

The *Homo-Pan* clade is strongly supported by dataset A, with a bootstrap value of 92%.

In addition, Shoshani *et al.* list seven characters synapomorphic for *Homo-Pan* with a CI of 1.0, and five such characters with a CI of 0.67<sup>158</sup>. Shoshani *et al.*, however, found the *Homo-Pan* clade to be weakly supported, with a bootstrap value of 42%<sup>158</sup>.

Of the characters with a CI of 1.0, some appear to be particularly informative.

#### 4.4.1.1 Lower limb and pelvic girdle

Characters that appear to be particularly informative for the *Pan-Homo* clade are character 5 (state 1), tensor fascia latae sometimes unfused proximally with gluteus maximus; character 29 (state 1), extensor digitorum longus originates from the crural fascia; character 36 (state 1), absence of a slip from abductor hallucis to the base of MI; character 41 (state 1), abductor hallucis inserts onto the medial cuneiform; character 43 (state 1), absence of a slip from abductor hallucis to the base of MI; character 45 (state 1), flexor hallucis brevis has no insertion onto MI; character 51

(state 1), the first dorsal interosseous originates from the lateral side of MI; character 52 (state 1), flexor digitorum brevis originates from the plantar aponeurosis; character 157 (state 1), presence of muscular branches of the profunda femoris artery for the hamstrings (posterior femoral muscles); character 193 (state 1), genitofemoral nerve does not pierce psoas major in some specimens; character 195 (state 1), presence of muscular branches of the obturator nerve for the pectineus; and character 199 (state 1), absence of superficial peroneal nerve supply for the medial side of digit II.

In *Homo*, *tensor fasciae latae*, through the iliotibial tract, extends the knee with lateral rotation of the leg, and may also assist in abduction and medial rotation of the thigh<sup>8, 51</sup>, although its role as an abductor has been denied<sup>52</sup>. In the erect posture, it helps to steady the pelvis on the head of the femur<sup>51</sup>, and through the iliotibial tract it steadies the condyles of the femur on the tibia, and thus helps maintain erect posture<sup>16, 105</sup>. It is also active in flexion of the thigh with the knee extended and assists the anterior bundles of the gluteus medius and minimus<sup>51</sup>. On the basis of innervation, *tensor fasciae latae* is closely-related to the anteromedial muscle layer of gluteus medius<sup>2</sup>. In African apes and *Hylobates*, *tensor fasciae latae* has a different orientation to that in *Homo*, so it flexes rather than extends the knee, although it also flexes, abducts and medially rotates the hip joint, and tenses the iliotibial band to brace the extended knee, as in *Homo*<sup>1, 160</sup>. Perhaps in *Pongo* the antero-laterally placed *scansorius* has functionally-replaced *tensor fasciae latae*, as the *scansorius* also abducts and flexes the thigh, and is located in a position similar to that which *tensor fascia latae* would occupy if present<sup>160</sup>.

*Gluteus maximus* in *Homo* acts from the pelvis to extend the flexed thigh and bring it in line with the trunk<sup>9</sup>. It may prevent the forward momentum of the trunk from causing flexion of the hip during bipedal gait<sup>9, 105</sup>. In standing, the muscle is inactive and remains so in forward swaying at the ankle joints, or during bending at the hip to touch the toes. However, with the posterior femoral muscles (hamstrings) it is active in raising the trunk after stooping, by rotating the pelvis posteriorly on the head of the femur<sup>163</sup>. It is intermittently active in climbing upstairs, and continuously active in strong lateral rotation of the thigh<sup>9</sup>. Its upper fibres are active in powerful abduction of the thigh<sup>193</sup>. *Gluteus maximus* in *Homo* is active at the end of the recovery (swing) phase, and the beginning of stance phase<sup>9</sup>. It has a significant role as a stabilizer of the sacroiliac joint, and thus the whole vertebral column<sup>163</sup>. The poorly-developed proximal part of *gluteus maximus* acts as an abductor and lateral rotator in great apes, while the more distal portion, known as the *ischiofemoralis* in *Pongo*, acts as an extensor of the ape hip joint<sup>135, 160, 161, 164, 189, 190, 191, 201</sup>. Along with tensor fasciae latae, the proximal part acts to tense the iliotibial band and thus brace the extended knee<sup>201</sup>.

*Pan* and *Homo* share an absence of proximal fusion between tensor fasciae latae and *gluteus maximus*. Both these muscles act to steady the pelvis on the head of the femur, and to abduct the thigh. In addition, through the iliotibial tract, both are involved in the stabilization of the extended knee. As has been stated previously, the separation of muscles that are normally fused may reflect the necessity for a greater range of independent muscular action at the hip joint, enabling these muscles to respond at slightly different times. The large size of *gluteus maximus* relative to the other gluteal muscles in *Homo*, compared with great apes<sup>160</sup>, may be related to its

increased activity in extension at the hip during bipedal walking, as opposed to the flexed hip bipedal posture of apes<sup>1</sup>. Alternatively, as stated above, the thin cranial part of gluteus maximus in great apes acts with tensor fasciae latae to tense the iliotibial tract to brace the extended knee, which may reflect a increased requirement for knee stabilization in *Homo*.

In *Homo*, in the non-weight bearing leg, *extensor digitorum longus* extends the digits and dorsiflexes the foot and with extensor hallucis longus tautens the plantar aponeurosis<sup>193</sup>. In the weight-bearing leg, it approximates the leg to the dorsum of the foot, as for example in skiing or rapid walking<sup>51</sup>.

Extensor digitorum longus originates from the crural fascia in *Homo* and *Pan*. This fascia is continuous with the fascia lata, and around the knee is attached to the patella, the ligamentum patellae, the tubercle and condyles of the tibia and the fibular head<sup>193</sup>.

In *Homo*, *abductor hallucis* acts as an abductor and a weak flexor, and helps to maintain the arch of the foot<sup>51</sup>. Electromyography (EMG) studies show that abductor hallucis in *Homo* is important to stabilize the foot during bipedal locomotion<sup>39, 94</sup>, and particularly the positioning of the anterior part of the foot relative to the posterior part of the foot and to the leg<sup>130</sup>. Abductor hallucis has a greater cross-sectional area than any other intrinsic foot muscle except adductor hallucis obliquus, indicating its functional importance<sup>66</sup>. An abnormal insertion of abductor hallucis in *Homo* may result in a varus deformity of MI, giving the appearance of an ape-like foot<sup>56</sup>.

The absence of two metatarsal slips in *Homo* and *Pan* may reflect a decrease in the importance of the hallux for prehensile grasping. In *Homo*, however, it maintains its



importance as a stabilizer of the foot, as can be seen from the large cross-sectional area of the muscle<sup>66</sup>. The insertion of abductor hallucis onto the medial cuneiform is variable in both *Homo* and *Pan*, but absent from other apes. Given the relatively small ape sample sizes involved, further study would be required to detect whether this is a true reflection of the situation in these species.

In *Homo*, *flexor hallucis brevis* is an important plantar flexor, especially in ballet dancing<sup>51</sup>. The size of this muscle in *Homo* reflects the importance of the flexion of digit I in bipedal locomotion, while in African apes this muscle is much smaller<sup>1</sup>.

The lack of an insertion onto MI in *Homo* and *Pan* may reflect a decrease in the importance of prehensile movements of the hallux.

The role of the *first dorsal interosseous* has been discussed in 4.3.3.

In *Homo*, *flexor digitorum brevis* plantarflexes the middle phalanges of the digits<sup>51</sup>.

An origin from the calcaneus allows it to stabilize the human longitudinal arch during locomotion and the muscle plays a major role in stabilizing upright posture<sup>141</sup>.

EMG studies show it to be active when the force of flexor digitorum longus is insufficient, or when more force is needed at the interphalangeal joints to enable the toes to grip the substrate<sup>130</sup>. In addition, contraction of the digital plantar flexors helps to counteract the strain placed on the metatarsals by body weight<sup>156</sup>. In African apes, the part of flexor digitorum brevis leading to the lateral digits originates from the tendon of flexor digitorum longus and not from the calcaneus; this arrangement may increase the grasping power of the lateral digits<sup>55</sup>.

Flexor digitorum brevis originates from the plantar aponeurosis in *Homo* and *Pan*, which may increase its function as a stabilizer of the arch of the foot during locomotion.

Muscular branches of the *profunda femoris* for the posterior femoral muscles (hamstrings) may be related to increased bloodflow to these structures.

Generally, when a muscle is pierced by a nerve, this indicates that at some point in its development, the muscle has incorporated more than one element, that have subsequently fused<sup>100</sup>. That the *genitofemoral nerve* does not pierce *psaos major* in some specimens of *Pan* and *Homo* may indicate a greater degree of fusion in these species. The author has been unable to find any developmental anatomy for the *psaos major* muscle, but greater fusion of *psaos major* may reflect its increased role in stabilizing the trunk<sup>12, 51, 138</sup>, particularly during sitting in *Homo*<sup>54</sup>. With the *iliopsoas*, *psaos major* in *Homo* flexes the thigh<sup>51</sup>.

The arrangement of the branches of the *obturator nerve* for the *pectineus* in *Homo* and *Pan* can be taken as part of the general trend for increased innervation of more active structures<sup>100</sup>. In *Homo*, *pectineus* flexes the hip, adducts the thigh and may act as a weak medial rotator<sup>51</sup>.

The innervation of the medial side of digit II by the deep peroneal nerve in *Homo* and *Pan* rather than by the *superficial peroneal nerve* as in other hominoids, appears to have no obvious functional implication.

#### 4.4.1.2 Upper limb and shoulder girdle

Characters that appear to be particularly informative for the *Pan-Homo* clade are character 88 (state 1), the lateral head of *triceps* originates from the intermuscular

septum; character 93 (state 1), extensor carpi ulnaris attains the first phalanx of digit V in some specimens; character 123 (state 3), cranial extension of the costal origin of pectoralis major; character 126 (state 2), origin of pectoralis major from the medial third of the clavicle; character 165 (state 1), posterior interosseous artery originates from a common trunk; character 170 (state 1), superficial palmar artery passes over the thenar muscles in some specimens; and character 172 (state 1), dorsalis pollicis artery absent.

In *Homo*, *triceps brachii* extends the forearm on the arm at the elbow joint. The action of the lateral head is, however, minimal except when the forearm is acting against resistance<sup>8</sup>, such as forward thrusting or pushing, or when the body weight is partly supported on the hands, with semiflexed elbow joints. Carlsöö and Johansson observed that triceps was active before and during the braking period in all falls, and thus stabilized the elbow joint<sup>17</sup>. During forceful supination of the semiflexed forearm, involving active contraction of both supinator and biceps brachii, the triceps contracts synergistically to fix the position of semiflexion at the elbow joint<sup>193</sup>. In African apes, triceps is active during knuckle-walking and protraction or abduction, but not during humeral retraction or arm-hanging<sup>46, 185</sup>. The three heads of triceps act separately in *Homo*<sup>118, 178</sup>, while discrete action of the three heads is not common in *Gorilla*<sup>185</sup>.

The lateral head of triceps originates from the intermuscular septum in *Homo* and *Pan*, conferring additional soft tissue origin and spreading the force of the muscle at the point of origin.

In *Homo* the *extensor carpi ulnaris*, in association with extensor carpi radialis longus and brevis, acts synergistically with the digital flexors in order to extend and fix the

wrist when objects are being gripped, or when the fist is clenched<sup>113</sup>. It is impossible to grip strongly unless the wrist is extended. Acting with the extensores carpi radiales, it extends the wrist, while acting with the flexor carpi ulnaris, it adducts the hand<sup>193</sup>. The principal action of extensor carpi ulnaris is as a strong ulnar abductor, its antagonist being abductor pollicis longus<sup>51</sup>. In African apes, extensor carpi ulnaris is a strong carpal extensor and somewhat of an ulnar abductor. Its power of abduction is greatest in *Homo* and *Hylobates*, while in *Pongo*, the muscle acts not only as an ulnar abductor of the hand but also as a hyperpronator, and a comparatively slight alteration in the course of the tendon relative to the wrist joint in this species would produce a flexor action<sup>169</sup>.

The extension of the insertion of extensor carpi ulnaris to the proximal phalanx of digit V in *Homo* and *Pan* occurs as a variation. Larger sample sizes would be necessary in order to rule out its occurrence in other hominoids, before any functional inferences can be made.

The two parts of *pectoralis major* in *Homo*, sternocostal and clavicular, can act in combination or independently. As a whole, pectoralis major is active in adduction and medial rotation of the humerus<sup>51, 63</sup>, but the activity is only marked if resistance has to be overcome<sup>193</sup>. When the arm is drawn posterolaterally, that is to say, extended, pectoralis major draws it anteromedially<sup>193</sup>. All the parts of pectoralis major act together, forcibly and rapidly lowering the raised arm<sup>51</sup>. Pectoralis major is also active in deep forcible inspiration<sup>193</sup>. With the arm abducted the clavicular and sternal parts of pectoralis major can produce anteversion, a movement common in swimming. The sternocostal and abdominal parts together lower the shoulder anteriorly<sup>51</sup>, but pectoralis major is completely silent during abduction<sup>1</sup>. When the

arm is swung anteromedially, the sternocostal fibres take no part in the movement, which is carried out by the clavicular fibres along with the anterior fibres of deltoid and coracobrachialis<sup>193</sup>. The upper or clavicular fibres are active during flexion of the humerus<sup>1, 119</sup>, and their activity is proportional to the degree of shoulder movement, but unrelated to elbow motion in the long head of biceps and lateral head of triceps<sup>40</sup>. When posterolateral movement, usually with gravitational assistance, is resisted, the sternocostal part assists latissimus dorsi and teres major. When the raised arms are fixed, such as by gripping a branch of a tree, the same combination of muscles operates to draw the trunk upwards and forwards in climbing<sup>193</sup>.

EMG studies have shown that pectoralis major is active in static quadrupedal posture in great apes<sup>187</sup>. Both cranial and caudal parts are relatively large in *Pan*. Caudal pectoralis major is most active during humeral retraction in the support phase of vertical climbing, while cranial pectoralis major is active in rapid non-weight bearing protraction of the arm during climbing, and may also aid in reaching during feeding<sup>46</sup>.

Cranial extension of the costal origin of pectoralis major and the origin of the clavicular part of pectoralis major from the medial third of the clavicle are synapomorphies for *Homo* and *Pan*. In general terms, a clavicular origin may be necessary to promote flexion of the forelimb in animals in which the humeral insertion is on the same transverse plane as, or superior to, the manubrium, that is, in animals with a cranially displaced shoulder joint. Although present in *Homo* and *Pan*, the clavicular origin is far more extensive in Asian apes and *Gorilla*. Modern adult *Homo* has a relative shoulder height index less than 1<sup>145</sup>, and therefore their shoulder is on the same level as the manubrium, while higher values, indicating a

more cranial shoulder joint, characterize the other hominoids (*Hylobates* = 13; *Pongo* = 16; *Pan* = 17; *Gorilla* = 13). However, there is an ontogenetic descent to achieve this state in *Homo*, so the fetal condition suggests a high, mobile, shoulder in an arboreal human ancestor<sup>167</sup>. It is interesting to note that *Pan* possesses a reduced clavicular origin for pectoralis major, but has the most cranially displaced shoulder joint of all hominoids. This does not appear to conform with the assertion of Stern *et al.* that a strong link exists between a clavicular origin of pectoralis major and the cranial displacement of the shoulder<sup>167</sup>. In fact, a clavicular origin of pectoralis major is absent from 80% of *Pongo* and 30% of *Pan*, even though these are apparently the two hominoid species with the most cranially displaced shoulder joints.

A cranial extension of the costal origin of pectoralis major may be a response to demands for strength or rapidity of flexion of the adducted forelimb in animals with enhanced upper limb mobility<sup>167</sup>. Although *Homo* and *Pan* share this feature to the exclusion of *Gorilla*, it should be noted that it is also present in *Pongo* in combination with a caudal extension of the origin.

The *posterior interosseous* and *anterior interosseous* arteries originate from a common trunk in *Homo* and *Pan*. The posterior interosseous artery supplies the extensor digitorum, extensor digiti minimi and extensor carpi ulnaris in *Homo*, while the anterior interosseous artery supplies part of flexor digitorum profundus, flexor pollicis longus and pronator quadratus. Both vessels supply extensor indicis, extensor pollicis longus, abductor pollicis longus and extensor pollicis brevis equally<sup>132</sup>. As can be seen from this list, the development of the interosseous arteries is inherently linked to the development of many extrinsic and intrinsic muscles of the hand, forming another link between the evolution of the muscles of the hand in these

two species. In previous paragraphs, character 93 has shown a synapomorphy in the *Homo-Pan* clade of extensor carpi ulnaris, which is supplied in *Homo* by the posterior interosseous artery.

The *superficial palmar artery* in *Homo* supplies the area over the proximal parts of the abductor pollicis brevis and opponens pollicis muscles<sup>111</sup>. A branch of the radial artery, in hominoids other than *Homo* and *Pan*, its importance in the supply of the thenar part of the hand appears to be reduced, especially in *Hylobates* and *Gorilla*, as it continues to complete the superficial palmar arch in *Homo*, *Pan* and *Pongo*.

The *dorsalis pollicis* arteries in Asian apes and *Gorilla* are branches of the radial and ulnar arteries. In *Homo*, the dorsum of the pollex is supplied by directly by the radial artery before it descends through the first interosseous space into the palm<sup>193</sup>. In Asian apes, if not in *Gorilla*, the radial artery passes into the palm via the second interosseous space, and therefore bypasses the dorsum of the pollex.

#### 4.4.1.3 Others

##### 4.4.1.3.1 Skin

The *reduced total body hair density* in *Homo* and *Pan* is part of a general trend in primates for larger primates to have systematically sparser coats. Surface area, not phylogeny, is a better predictor of relative hair density<sup>152</sup>. Schwartz and Rosenblum report negative correlations between relative hair density and total body surface area, which may represent a thermal adaptation in anthropoid primates<sup>152</sup>. Both New World and Old World primates have converged upon a similar solution to the same biological problem. Thermal sweating may have evolved as a necessary compensation for the loss of body hair in the high radiant heat loads of the Pliocene

savannah in early hominids<sup>101, 107, 152</sup>. However, the possession of an axillary organ in African apes and *Homo*, as well as similarities in their cutaneous sweat glands<sup>171</sup> appears to indicate that cutaneous sweating as a method of heat loss predates the divergence of hominids from the ape-human lineage. Wheeler has stated that the hair coat of *Pan troglodytes* allows more heat to reach the skin surface than the coat of savannah mammals that rely on respiratory heat loss<sup>195</sup>. This may be explained by the general reduction of hair density present in all higher primates, resulting in the reduction of the insulatory properties of the hair coat<sup>152</sup>, both in the prevention of heat loss and of heat gain.

#### 4.4.1.3.2 Genital

A consistently *postpenial, dependant scrotum* is present in *Homo* and *Pan*. Developmentally, dilation of the scrotal sac is related to dilation of the gubernaculum testis via fluid uptake. The upper end of the gubernaculum testis attaches to the testis in its embryonic position on the posterior abdominal wall, and also to the adjacent part of the peritoneum and to the mesonephric duct (which later becomes the epididymis and vas deferens). At the time of descent, the attached structures are dragged behind the gubernaculum into the scrotum. Androgen sensitivity<sup>27</sup> and intra-abdominal pressure<sup>6, 34</sup> are the principal factors in testicular descent. If in *Homo* the scrotum is not well-formed, the gubernaculum has not dilated and there is probably a deficiency of interstitial cell testosterone production. The author has been unable to find data on androgen levels in fetal and infant hominoids. Such a study would be useful in order to ascertain whether the failure of the formation of a dependant scrotum is linked to hormone levels in these apes. Frey has suggested a link between extra-abdominal testes and a fast mode of locomotion in mammals<sup>34</sup>.



A retained testis in *Homo* has a smaller average testicular volume (10.5 ml) compared with those with normal descent (14.1 ml). Testicular volume correlates with total sperm count in the ejaculate, sperm penetration ability and normal sperm morphology<sup>74</sup>.

These facts may imply that the position of the scrotum in the hominoids has a developmental basis. Maldescent in *Homo* can result in testes positioned at the root of the penis or the upper part of the thigh<sup>193</sup>, similar to the para- or pre-penial conditions found in Asian apes and *Gorilla*. This is not to suggest that this is 'abnormal' for these species, although the testes of captive gorillas are often congenitally atrophied and poor in sperm quality<sup>122</sup>, but it may be that a postpenial, dependant scrotum allows the development of larger, more productive testes<sup>148</sup>. Relative to body size, *Homo* and *Pan*, particularly the latter species, have by far the largest testes among hominoids<sup>57</sup>. It has been suggested that the testes of hominoids with one-male mating systems, such as *Pongo*, *Gorilla* and *Homo*, are much smaller than those with multimale mating systems, such as *Pan*<sup>157</sup>. However, it seems that the monogamous gibbons and *Pongo* have similar relative testicle sizes, with those of *Gorilla* even smaller, while the testes of *Homo* are intermediate in size between the single-male and multi-male species<sup>57</sup>.

#### 4.4.2 Upper limb

Of Subset A1 consisting of 71 characters, 16 characters were synapomorphic for *Homo-Pan*. Of these, 7 characters had a CI of 1.0.

They are: 88 (0→1), 93 (0→1), 165 (0→1), 170 (0→1), 172 (0→1), 175 (0→1) and 182 (0→1).

In addition, two further characters had a relatively good CI, but less than 1.0; 73 (0→1, CI = 0.67) and 76 (0→1, CI = 0.67).

This clade is well supported by Subset A1, with a bootstrap value of 69%.

#### 4.4.3 Lower limb

Of Subset A2, consisting of seventy-one characters, twenty-four characters were synapomorphic for the *Pan-Homo* clade. Of these, 13 had a CI of 1.0.

They are: 5 (0→1), 29 (0→1), 34 (0→2), 36 (0→1), 41 (0→1), 43 (0→1), 45 (0→1), 51 (0→1), 52 (0→1), 155 (0→1), 157 (0→1), 195 (0→1) and 199 (0→1).

In addition, four characters had a relatively good CI, but less than 1.0; 10 (0→1, CI = 0.67), 30 (0→1, CI = 0.67), 33 (0→1, CI = 0.67) and 198 (0→1, CI = 0.67).

This clade is well supported by subset A2, with a bootstrap value of 73%.

### 4.5 CONCLUSIONS

"The morphological distance between humans and chimpanzees is large by frog standards" Cherty *et al.*(1978).

From the anatomical data in Chapter 3, and the listing of anatomical structures in Appendix 5, it is obvious that there remains a great deal to learn about the soft tissue anatomy of our closest living relatives, the Asian and African apes. Considerable gaps exist, especially for certain regions and species. In particular, I have been able to find surprisingly little information about the alimentary organs, heart, respiratory system, peripheral nervous system, urinary system, lymphatic system and veins.

*Hylobates* and *Pan paniscus* are the least-researched hominoids, while *Pan*

*troglydytes* is the most comprehensively studied. More work needs to be done, especially in these areas, for all species.

With regard to cladistic analysis, this thesis concludes that soft tissue anatomy, utilizing characters from the entire morphological pattern, can be used to reconstruct the phylogenetic relationships between the Hominoidea, based on the consensus molecular cladogram. Both *Homo-Pan* and *Homo-Gorilla-Pan* are significantly favoured, with bootstrap values of 92% and 85% respectively, while neither of the main alternative cladistic groupings (*Gorilla-Homo* or *Gorilla-Pan*) are significantly supported. This builds on the results obtained from the dataset of Shoshani *et al.*<sup>158</sup>. Their dataset, although containing some soft tissue characters, consisted mainly of skeletal and dental characters, that may be unreliable in reconstructing cladistic relationships between catarrhine species<sup>21</sup>.

Both regional subsets, A1 (upper limb) and A2 (lower limb) support a *Pan-Homo* clade, although A1 provides slightly weaker support than A2. Subset A1 does, however, strongly support an African ape-*Homo* clade, while A2 does not, due to homoplastic features in *Pongo* and *Gorilla*.

However, the branch-swapping technique shows that other phylogenetic groupings are within 5% of the tree length of the most parsimonious tree for Dataset A. These include *Gorilla-Homo*, *Gorilla-Pan* and *Pongo-Gorilla*. Of these, however, *Gorilla-Pan* creates the greatest difference from the most parsimonious tree.

From this analysis, there are four lower limb synapomorphies for the African ape-*Homo* clade, three related to muscles acting at the hip joint, and one related to a muscle acting on the foot. In the upper limb, thirteen synapomorphies exist for the

African ape-*Homo* clade. Of these, five relate to structures acting at the shoulder joint, three to antebrachial flexors, two to antebrachial extensors and three to intrinsic muscles of the hand. The integumentary, genital and alimentary systems show one synapomorphic character each.

For the *Homo-Pan* clade, twelve synapomorphies are present in the lower limb. Four relate to muscles acting on the hip and knee, one to a digital extensor and seven to intrinsic muscles of the foot. In the upper limb, there are seven synapomorphies for *Homo* and *Pan*. Two act at the shoulder, two are related to the extensor aspect of the forearm, one is an extensor of the wrist, and two are related to the arterial supply of the thenar region. Single synapomorphies are present in the genital and integumentary systems.

The putative synapomorphic lower limb characters for a *Pongo-Gorilla* clade may be explained in terms of convergent evolution, as shown by other lower limb features such as relative limb length<sup>137, 147</sup>, degree of sexual dimorphism<sup>93, 133</sup>, some measures of the talus<sup>7, 93, 155</sup> and the width of the lateral metatarsals<sup>93</sup>. However, most skeletal lower limb features do not indicate a close relationship, functional or otherwise, between these two hominoid species. In fact, in some aspects of lower limb morphology, *Pongo* is either unique among hominoids<sup>35, 77, 147, 150, 151, 188</sup>, or more closely linked with the hylobatids<sup>147, 151</sup>.

In general terms, it appears that the upper limb provides more synapomorphies for the African ape-*Homo* clade than the lower limb, while the reverse is true for the *Pan-Homo* clade.

The human lower limb and foot may bear a closer resemblance to the ape structures as used in arboreal than in terrestrial locomotion<sup>28, 47, 59, 60, 85, 108, 116, 134, 139, 168, 173, 198</sup>, but other authors suggest that hominid locomotor evolution has passed through a quadrupedal terrestrial phase<sup>36</sup>. The hominoid foot tolerates postural and locomotor stress in a wide range of ankle orientations. These patterns suggest that living and fossil hominoids are closer to the common ancestral design of the anthropoid foot<sup>67</sup>.

Based on the upper limb and shoulder girdle, it has been variously suggested that the prebipedal ancestors of modern humans were primarily adapted for suspension<sup>80, 81, 83, 84, 87, 114, 115, 182, 186</sup>, quadrupedal climbing<sup>18, 31, 33, 97, 126, 153, 154, 184, 194</sup>, terrestrial quadrupedality<sup>10, 11, 22, 23, 82, 140, 170</sup> or a combination of the three<sup>24, 136, 165</sup>, and certainly some features of the shoulder girdle in modern *Homo* resemble brachiating primates, while others are similar to quadrupedal primates<sup>5</sup>. Given the variation in locomotor behaviour among the extant great apes, this may be an unresolvable problem<sup>30</sup>. Biomechanically, vertical climbing promotes erect body posture and knee extension, and develops hip extensors. Bipedal walking on large branches requires a motion pattern of the knee joint similar to that of *Homo*, and demands strong knee joint extensors<sup>198</sup>, while some studies suggest that the vertical climbing performed by *Pan* and *Pongo* is more similar biomechanically to human bipedalism than more terrestrial primates such as Japanese macaques and baboons<sup>47, 59, 60, 108</sup>.

This thesis has assembled information about the soft tissue anatomy of the extant hominoids, and has compared the distribution pattern of the characters derived from that information with the consensus molecular phylogenetic tree. This procedure will hopefully provide a new perspective on the debate about whether, in the evolution of

Miocene hominoids, homoplasy is more likely in cranial, or in postcranial, skeletal characters<sup>121</sup>.

## BIBLIOGRAPHY

1. **Aiello, L and Dean, C** (1990): An introduction to human evolutionary anatomy. Academic Press, London.
2. **Akita, K; Sakamoto, J and Sato, T** (1993): Innervation of the anteromedial muscle bundles of the gluteus medius. *J.Anat.* 182(3), p433-438.
3. **Akita, K; Sakamoto, H and Sato, T** (1994): Arrangement and innervation of the glutei medius and minimus and the piriformis - a morphological analysis. *Anat.Rec.* 238(1), p125-130.
4. **Akita, K; Niiro, N; Murakami, G and Sato, T** (1999): First dorsal interosseous muscle of the foot and its innervation. *Clin.Anat.* 12(1), p12-15.
5. **Ashton, EH and Oxnard, CE** (1961): Functional variation in the primate shoulder girdle. *J.Anat.* 96, p415.
6. **Attah, AA and Hutson, JM** (1993): The role of intra-abdominal pressure in cryptorchidism. *J.Urol.* 150(3):994-6.
7. **Barnett, CH** (1955): Some factors influencing angulation of the neck of the mammalian talus. *J.Anat.* 89, p225-230.
8. **Basmajian, JV** (1967): *Muscles alive*. Williams and Wilkins, Baltimore.
9. **Basmajian, JV** (1972): Biomechanics of human and locomotion: Perspectives from electromyography. In: Tuttle, RH (ed); *Functional and evolutionary biology of primates*. Aldine, Chicago.
10. **Begun, DR** (1992a): Miocene fossil hominids and the chimp-human clade. *Science.* 247, p1929-1933.
11. **Begun, DR** (1994a): Relations among the great apes and humans: New interpretations based on the fossil great ape *Dryopithecus*. *Yearb. Phys.Anthropol.* 37, p11-63.

12. **Bogduk, N; Pearcy, M and Hadfield, G** (1992): Anatomy and biomechanics of psoas major. *Clin.Biomech.* 7(2), p109-119.
13. **Bohne, WHO; Lee ,KT and Peterson, MGE** (1997): Action of the peroneus longus tendon on the first metatarsal against metatarsus primus varus force. *Foot and Ankle Int.* 18(8), p510-512.
14. **Botte, MJ; Nakai, RJ; Waters, RL; McNeal, DR and Rubayi, S** (1991): Motor point delineation of the gluteus medius muscle for functional electrical-stimulation - an in vivo anatomic study. *Arch.Phys.Med.Rehab.* 72(2), p112-114.
15. **Brunelli, GA and Brunelli, GR** (1992): Anatomy of the extensor pollicis brevis muscle. *J.Hand Surg.* 17B(3), p267-269.
16. **Buchanan, TS and Lloyd, DG** (1997): Muscle activation at the human knee during isometric flexion-extension and varus-valgus loads. *J.Orthop.Res.* 15(1), p11-17.
17. **Carlsöö, S and Johansson, O** (1962): Stabilization of and load on the elbow joint in some protective movements. *Acta Anat.* 48, p224-231.
18. **Cartmill, M and Milton, M** (1977): The lorisiform wrist joint and the evolution of "brachiating" adaptations in the Hominoidea. *Am.J.Phys.Anthropol.* 47,p249-272.
19. **Cherty, LM; Case, SM and Wilson, AC** (1978): Frog perspective on the morphological difference between humans and chimpanzees. *Science.* 200(4338), p209-211.
20. **Cohen, MS and Hastings, H** (1997): Rotatory instability of the elbow - The anatomy and role of the lateral stabilizers. *J.Bone Jt.Surg.(Am.Vol.).* 79A(2), p225-233.
21. **Collard, M** (1998): Morphological evolution of the extant hominoids and papionins: Implications for palaeoanthropological cladistics. PhD Thesis, University of Liverpool.

22. **Conroy, GC and Fleagle, JG** (1972): Locomotor behavior in living and fossil pongids. *Nature*. 237, p103-104.
23. **Corruccini, RS** (1978): Comparative osteometrics of the hominoid wrist joint, with special reference to knuckle-walking. *J.Hum.Evol.* 7, p307-321.
24. **Corruccini, RS and Ciochon, RL** (1975): Morphometric affinities of the human shoulder. *Am.J.Phys.Anthropol.* 45, p19-38.
25. **Davidson, PA; Pink, M; Perry, J and Jobe, FW** (1995): Functional anatomy of the flexor pronator muscle group in relation to the medial collateral ligament of the elbow. *Am.J.Sports Med.* 23(2), p245-250.
26. **De Sousa, OM and Vitti, M** (1966): Estudio electromyografico de los músculos adductores largo y mayor. *Arch.Mex.Anat.* 7, p52-53. (Abstract).
27. **Elder, JS; Isaacs, JT and Walsh, PC** (1982): Androgenic sensitivity of the gubernaculum testis: Evidence for hormonal/mechanical interactions in testicular descent. *J.Urol.* 127:170-175.
28. **Elftman, H and Manter, J** (1935): The evolution of the human foot, with especial reference to the joints. *J.Anat.Phys.* 70, p56-67.
29. **Feistner, ATC** (1991): Scent marking in mandrills, *Mandrillus sphinx*. *Folia Primatol.* 57(1), p42-47.
30. **Feldesman, MR** (1982): Morphometric analysis of the distal humerus of some Cenozoic catarrhines: The late divergence hypothesis revisited. *Am.J.Phys.Anthropol.* 59, p73-95.
31. **Fleagle, JG** (1976): Locomotion and posture of the Malayan siamang and implications for hominoid evolution. *Folia Primatol.* 26, p245-269.
32. **Fleagle, JG; Stern, JT Jr; Jungers, WL and Susman, RL** (1981): Climbing: A biomechanical link with brachiation and with bipedalism. *Symp.Zool.Soc.Lond.* 48, p359-375.
33. **Fleckenstein, JL; Watumull, D; Bertocci, LA; Nurenburg, P; Peshock, RM; Payne, JA and Haller, RG** (1994): Muscle recruitment variations during



- wrist flexion exercise - MR evaluation. *J.Comput.Assist.Tomogr.* 18(3), p449-453.
34. **Frey, R** (1991): On the cause of the mammalian descent of the testes (Descensus testiculorum). *Z.Zool.Syst.Evolutionsforsch.* 29(1), p40-65.
  35. **Gebo, DL** (1989): Locomotor and phylogenetic considerations in anthropoid evolution. *J.Hum.Evol.* 18, p201-233.
  36. **Gebo, DL** (1992): Plantigrady and foot adaptation in African apes: Implications for hominid origins. *Am.J.Phys.Anthropol.* 89, p29-58.
  37. **Geissmann, T** (1987): A sternal gland in the Siamang gibbon. *Int.J.Primatol.* 8 (1), p1-15.
  38. **Gonzalez, MH; Weinzwieg, N; Kay, T and Grindel, S** (1996): Anatomy of the extensor tendons to the index finger. *J.Hand.Surg.(Am.Vol.).* 21A(6), p988-991.
  39. **Gray, EG and Basmajian, JV** (1968): Electromyography and cinematography of leg and foot ('normal' and flat) during walking. *Anat.Rec.* 161, p1-5.
  40. **Gribble, PL and Ostry, DJ** (1998): Independant coactivation of shoulder and elbow muscles. *Exp.Brain Res.* 123(3), p355-360.
  41. **Gunther, SF; Dipasquale, D and Martin, R** (1992): The internal anatomy of the median nerve in the region of the elbow. *J.Hand Surg.(Am.Vol.).* 17A(4), p648-656.
  42. **Hamrick, MW; Churchill, SE; Schmitt, D and Hylander, WL** (1998): EMG of the human flexor pollicis longus muscle: Implications for the evolution of hominid tool use. *J.Hum.Evol.* 34(2), p123-136.
  43. **Hanson, G and Montagna, W** (1962): The skin of primates. XII. The skin of the owl monkey (*Aotus trivirgatus*). *Am.J.Phys.Anthropol.* 20, p421-430.
  44. **Haxton, HA** (1947): Muscles of the pelvic limb: A study of the differences between bipeds and quadrupeds. *Anat.Rec.* 98, p337-346.
  45. **Hill, WCO and Sabater Pi, J** (1971): Anomaly of the hallux in a lowland gorilla (*Gorilla gorilla gorilla* Savage and Wyman). *Folia Primatol.* 14, p252-255.

46. **Hunt, KD** (1991): Mechanical implications of chimpanzee positional behavior. *Am.J.Phys.Anthropol.* 86, p521-536.
47. **Ishida, H; Kumakura, H and Kondo, S** (1985): Primate bipedalism and quadrupedalism: comparative electromyography. In: Kondo,S (ed); Primate morphophysiology, locomotor analysis and human bipedalism. University of Tokyo Press, Tokyo.
48. **Janda, V and Stará, V** (1965): The role of thigh adductors in movement patterns of the hip and knee joint. *Courrier, Centre Internat. de l'Enfance.* 15, p1-3.
49. **Jeffcoate, TNA** (1962): Principles of gynaecology. 2nd Ed. Butterworths, London.
50. **Jungers, WL; Meldrum, DJ and Stern, JT** (1993): The functional and evolutionary significance of the human peroneus tertius muscle. *J.Hum.Evol.* 25, p377-386.
51. **Kahle, W; Leonhardt, H and Platzer, W** (1992): Color atlas and text of human anatomy. Vol.1. Locomotor system. Thieme Verlag, Stuttgart/New York.
52. **Kaplan, EB** (1958a): The iliotibial tract. Clinical and morphological significance. *J.Bone Jt.Surg.* 40A, p817-831.
53. **Kaplan, EB** (1958b): Comparative anatomy of the extensor digitorum longus in relation to the knee joint. *Anat.Rec.* 131(2), p129-149.
54. **Keagy, RD; Brumlik, J and Bergan, JL** (1966): Direct electromyography of the psoas major muscle in man. *J.Bone Jt.Surg.* 48A, p1377-1382.
55. **Keith, A** (1929): The history of the human foot and its bearing on orthopaedic practice. *J.Bone Jt.Surg.* 11, p10-32.
56. **Kelly, IP; O'Byrne, JM; Mulcahy, D and Stephens, M** (1996): Surgical correction of a simian foot. *Foot Ankle Internat.* 17(3), p174-176.
57. **Kenagy, GJ and Trombulak, SC** (1986): Size and function of mammalian testes in relation to body size. *J.Mammal.* 67 (1), p1-22.

58. **Kilbreath, SL and Gandevia, SC** (1993): Neural and biomechanical specializations of human thumb muscles revealed by matching weights and grasping objects. *J.Physiol.* 472, p537-556.
59. **Kimura, T** (1985): Bipedal and quadrupedal walking of primates: comparative dynamics. In: Kondo,S (ed); *Primate morphophysiology, locomotor analysis and human bipedalism*. University of Tokyo Press, Tokyo.
60. **Kimura, T; Okada, M and Ishida, H** (1979): Kinesiological characteristics of primate walking: its significance in human walking. In: Morbeck,ME; Preuschoft,H and Gomberg,N (eds); *Environment, behavior and morphology: dynamic interactions in primates*. Gustav Fischer, New York.
61. **Klein, P; Mattys, S and Rooze, M** (1996): Moment arm length variations of selected muscles acting on talocrural and subtalar joints during movement: An in vitro study. *J.Biomech.* 29(1), p21-30.
62. **Kozin, SH; Porter, S; Clark, P and Thoder, JJ** (1999): The contribution of the intrinsic muscles to grip and pinch strength. *J.Hand.Surg.(Am.Vol.)*. 24A(1), p64-72.
63. **Kuechle, DK; Newman, SR; Itoi, E; Morrey, BF and An, KN** (1997): Shoulder muscle moment arms during horizontal flexion and elevation. *J.Shoulder Elbow Surg.* 6(5), p429-439.
64. **Kumagai, M; Shiba, N; Higuchi, F; Nishimura, H and Inoue, A** (1997): Functional evaluation of hip abductor muscles with use of magnetic resonance imaging. *J.Orthop.Res.* 15(6), p888-893.
65. **Kumakura, H** (1989): Functional analysis of the biceps femoris muscle during locomotor behavior in some primates. *Am.J.Phys.Anthropol.* 79, p379-391.
66. **Kura, J; Luo, ZP; Kitaoka, HB and An, KN** (1997): Quantitative analysis of the intrinsic muscles of the foot. *Anat.Rec.* 249(1), p143-151.
67. **Langdon, JH** (1983): Functional comparison of Miocene hominoid feet with those of living Old World anthropoids. *Am.J.Phys.Anthropol.* 60, p216(abst).

68. **Laroy, V; Spaans, F and Reulen, J** (1998): The sensory innervation pattern of the fingers. *J.Neurol.* 245(5), p294-298.
69. **Latimer, B and Lovejoy, CO** (1989): The calcaneus of *Australopithecus afarensis* and its implications for the evolution of bipedality. *Am.J.Phys.Anthropol.* 78, p369-386.
70. **Latimer, B and Lovejoy, CO** (1990): Hallucal tarsometatarsal joint in *Australopithecus afarensis*. *Am.J.Phys.Anthropol.* 82, p125-133.
71. **Latimer, BM, Lovejoy, CO; Johanson, DC and Coppens, Y** (1982): Hominid tarsal, metatarsal and phalangeal bones recovered from the Hadar formation: 1974-1977 collections. *Am.J.Phys.Anthropol.* 57, p701-719.
72. **Lehuc, JC; Liquois, F; Leger, O; Chauveaux, D; Midy, D and Lerebeller, A** (1995): A study of the fasciocutaneous vascularization of the arm - surgical applications. *Surg.Radiol.Anat.* 17(2), p121-128.
73. **Leijnse, JNAL** (1997): The controllability of the unloaded human finger with superficial or deep flexor. *J.Biomech.* 30(11-12), p1087-1093.
74. **Lenz, S; Giwercman, A; Elsborg, A; Cohr, KH; Jelnes, JE; Carlsen, E and Skakkeback, NE** (1993): Ultrasonic testicular texture and size in 444 men from the general population: correlation to semen quality. *Eur.Urol.* 24(2):231-238.
75. **Leutenegger, W** (1970a): Das Becken der Primaten und seine Beziehungen zur Lokomotion. *Z.Morphol.Anthropol.* 62, p328-333.
76. **Leutenegger, W** (1970b): Beziehungen zwischen der Neugeborengrösse und dem Sexualdimorphismus am Becken bei simischen Primaten. *Folia Primatol.* 12, p224-235.
77. **Leutenegger, W** (1973): Maternal-fetal weight relationships in primates. *Folia Primatol.* 20, p280-293.
78. **Leutenegger, W** (1974): Functional aspects of pelvic morphology in simian primates. *J.Hum.Evol.* 3, p207-222.

79. **Leutenegger, W** (1979): Evolution of litter size in primates. *Am.Nat.* 114, p525-531.
80. **Lewis, OJ** (1971): Brachiation and the early evolution of the Hominoidea. *Nature.* 230, p577-579.
81. **Lewis, OJ** (1972): Evolution of the hominoid wrist. In: Tuttle,RH (ed); *The functional and evolutionary biology of primates.* Aldine-Atherton, New York.
82. **Lewis, OJ** (1973): The hominoid os capitatum, with special reference to the fossil bones from Sterkfontein and Olduvai Gorge. *J.Hum.Evol.* 2, p1-13.
83. **Lewis, OJ** (1974): The wrist articulations of the Anthropeidea. In: Jenkins,FA (ed); *Primate locomotion.* Academic Press, New York.
84. **Lewis, OJ** (1977): Joint remodelling and the evolution of the human hand. *J.Anat.* 123, p157-201.
85. **Lewis, OJ** (1980c): The joints of the evolving foot. Part III. The fossil evidence. *J.Anat.* 131, p275-298.
86. **Lewis, OJ** (1989): *Functional morphology of the evolving hand and foot.* Oxford University Press, New York.
87. **Lisowski, FP; Albrecht, GH and Oxnard, CE** (1974): The form of the talus in some higher primates: A multivariate study. *Am.J.Phys.Anthropol.* 41, p195-216.
88. **Louwerens, JWK; van Linge, B; de Klerk, LWL; Mulder, PGH and Snijders, CJ** (1995): Peroneus longus and tibialis anterior muscle activity in the stance phase - A quantified electromyographic study in 10 controls and 25 patients with chronic ankle instability. *Acta Orthop.Scand.* 66(6), p517-523.
89. **Lovejoy, CO** (1988): Evolution of human walking. *Sci.Am.* 259(5), p118-125.
90. **Lovejoy, CO; Johanson, DC and Coppens, Y** (1982): Hominid lower limb bones recovered from the Hadar formation: 1974-1977 collections. *Am.J.Phys.Anthropol.* 57, p679-700.

91. **McFarland, GB Jr; Krusen, UL and Weathersby, HT** (1962): Kinesiology of selected muscles acting on the wrist: electromyographic study. Arch.Phys.Med. 43, p165-171.
92. **Mainoya, JR and Urasa, FM** (1982): Occurrence and histology of the sternal gland in the greater bushbaby, *Galago crassicaudatus*. Afr.J.Ecol. 20(3), p199-205.
93. **Manley-Buser, KA** (1991): Sexual dimorphism in the foot of *Gorilla* and *Pongo*. Paper for the AAPA 60th AM, Wisconsin.
94. **Mann, R and Inman, VT** (1964): Phasic activity of intrinsic muscles of the foot. J.Bone Jt.Surg. 46A, p469-481.
95. **Manners-Smith, T** (1912): The limb arteries of primates. Part 1. J.Anat.Phys. 44, p277-302.
96. **Markee, JE; Logue, JT; Williams, M; Stanton, WB; Wrenn, RN and Walker, LB** (1955): Two joint muscles of the thigh. J.Bone Jt.Surg. 37A, p125-142.
97. **Martin, CP** (1934): A comparison of the joints of the arm and leg and the significance of the structural differences between them. J.Anat. 68, p511-520.
98. **Marzke, MW; Toth, N; Schick, K; Reece, S; Steinberg, B; Hunt, K; Linscheid, RL and An, KN** (1998): EMG study of hand muscle recruitment during hard hammer percussion manufacture of Oldowan tools. Am.J.Phys.Anthropol. 105(3), p315-332.
99. **Matloub, HS; Ye, Z; Yousif, NJ and Sanger, JR** (1992): The medial arm flap. Ann.Plast.Surg. 29(6), p517-522.
100. **Miller, RA** (1934): Comparative studies upon the morphology and distribution of the brachial plexus. Am.J.Anat. 54(1), p143-175.
101. **Montagna, W** (1972): The skin of nonhuman primates. Am.Zool. 12, p109-121.
102. **Montagna, W** (1985): The evolution of human skin(?). J.Hum.Evol. 14, p3-22.

103. **Montagna, W and Ellis, RA** (1963): New approaches to the skin of primates. In: Buettner-Jansch, J (ed); Evolutionary and genetic biology of primates. Vol.1. Academic Press, New York; p179-196.
104. **Montagna, W and Yun, JS** (1962): The skin of primates. VIII. The skin of the anubis baboon (*Papio doguera*). Am.J.Phys.Anthropol. 20, p131-142.
105. **Montgomery, WH; Pink, M and Perry, J** (1994): Electromyographic analysis of hip and knee musculature during running. Am.J.Sports Med. 22(2), p272-278.
106. **Neumann, DA** (1996): Hip abductor muscle activity in persons with a hip prosthesis while carrying loads in one hand. Phys.Therapy. 76(12), p1320-1330.
107. **Newman, RW** (1970): Why man is such a sweaty and thirsty naked mammal: A speculative review. Human Biol. 42, p12-27.
108. **Okada, M** (1985): Primate bipedal walking: comparative kinematics. In: Kondo, S (ed); Primate morphophysiology, locomotor analysis and human bipedalism. University of Tokyo Press, Tokyo.
109. **Olave, R; Prates, JC; Gabrielli, C and Pardi, P** (1996): Morphometric studies of the muscular branch of the median nerve. J.Anat. 189(2), p445-449.
110. **Olave, E; Prates, JC; Gabrielli, C and Mandiola, E** (1998): Perforating branches: Important contribution to the formation of the dorsal metacarpal arteries. Scand.J.Plst.Reconstr.Surg.Hand.Surg. 32(2), p221-227.
111. **Omokawa, S; Ryu, JY; Tang, JB and Han, JS** (1997): Vascular and neural anatomy of the thenar area of the hand: Its surgical applications. Plast.Reconstr.Surg. 99(1), p116-121.
112. **van Oudenaarde, EV and Oostendorp, R** (1992): Significance of the innervation pattern of the human abductor pollicis longus muscle. J.Anat. 181(1), p155-159.

113. **van Oudenaarde, E; Brandsma, JW and Oostendorp, RAB** (1997): The influence of forearm, hand and thumb positions on extensor carpi ulnaris and abductor pollicis longus activity. *Acta Anat.* 158(4), p296-302.
114. **Oxnard, CE** (1969): Mathematics, shape and function: A study in primate anatomy. *Am.Sci.* 57(1), p75-96.
115. **Oxnard, CE** (1973): Functional inferences from morphometrics: Problems posed by uniqueness and diversity among the primates. *Syst.Zool.* 22(4), p409-424.
116. **Oxnard, CE and Lisowski, FP** (1980): Functional articulation of some hominoid foot bones: Implications for the Olduvai (Hominid 8) foot. *Am.J.Phys.Anthropol.* 52, 107-117.
117. **Pandey, SK; Tripathi, FM; Shukla, VK; Tripathi, CB and Sonoo, J** (1991): An anatomic basis for the clinical-application of the arterial supply of musculus-pectoralis major. *Acta Anat.* 141(4), p302-306.
118. **Pauly, JE; Rushing, JL and Scheving, LE** (1967): An electromyographic study of some muscles crossing the elbow joint. *Anat.Rec.* 159, p47-54.
119. **Pearl, ML; Perry, J; Torburn, L and Gordon, LH** (1992): An electromyographic analysis of the shoulder during cones and planes of arm motion. *Clin.Orthop.Relat.Res.* 284, p116-127.
120. **Perkins, EM Jr and Machida, H** (1967): The skin of primates. XXXIV. The skin of the golden spider monkey (*Ateles geoffroyi*). *Am.J.Phys.Anthropol.* 26, p35-43.
121. **Pilbeam, D** (1996): Genetic and morphological records of the Hominoidea and hominid origins: A synthesis. *Mol.Phyl.Evol.* 5(1), p155-168.
122. **Platz, CC; Wildt, DE; Bridges, CH; Seager, SW and Whitlock, BS** (1980): Electroejaculation and semen analysis in a male lowland gorilla, *Gorilla gorilla gorilla*. *Primates.* 21(1), p130-132.
123. **Popowsky, J** (1893): Phylogenesis des Arteriensystems der unteren Extremitäten bei den Primaten. *Anat.Anz.* 8, p657-665.



124. **Preuschoft, H** (1970): Functional anatomy of the lower extremity. In: Bourne, GH (ed); *The Chimpanzee* Vol.3. Karger, Basel; p221-294.
125. **Preuschoft, H** (1978): Recent results concerning the biomechanics of man's acquisition of bipedality. In: Chivers, J (ed); *Recent advances in primatology*. Academic Press, London and New York; p435-458.
126. **Prost, JH** (1980): Origin of bipedalism. *Am.J.Phys.Anthropol.* 52, p175-189.
127. **Raven, HC** (1950): Regional anatomy of the Gorilla. In: Gregory, WK(ed); *The anatomy of the Gorilla*. Columbia University Press, New York; p 15-188.
128. **Reber, L; Perry, J and Pink, M** (1993): Muscular control of the ankle in running. *Am.J.Sports Med.* 21(6), p805-810.
129. **Reddy, AS and Frederick, RW** (1998): Evaluation of the intraosseous and extraosseous blood supply to the distal femoral condyles. *Am.J.Sports Med.* 26(3), p415-419.
130. **Reeser, LA; Susman, RL and Stern, JT** (1983): Electromyographic studies of the human foot: experimental approaches to hominid evolution. *Foot and Ankle.* 3, p391-407.
131. **Reimann, R; Sodia, F and Klug, E** (1996): The disputed rotating function of certain muscles in the hip. *Anat.Anz.* 178(4), p353-359.
132. **Revol, MP; Lantieri, L; Loy, S and Guerinsurville, H** (1991): Vascular anatomy of the forearm muscles - a study of 50 dissections. *Plast.Reconstr.Surg.* 88(6), p1026-1033.
133. **Richmond, BG and Jungers, WL** (1995): Size variation and sexual dimorphism in *Australopithecus afarensis* and living hominoids. *J.Hum.Evol.* 29, p229-245.
134. **Riesenfeld, A** (1974): Metatarsal robusticity in primates and a few other plantigrade mammals. *Primates.* 15 (1), p1-25.
135. **Robinson, JT; Freedman, L and Sigmon, BA** (1972): Some aspects of pongid and hominid bipedality. *J.Hum.Evol.* 1, p361-369.

136. **Rose, MD** (1991): The process of bipedalization in hominids. In: Coppens, Y and Senut, B (eds): Origine(s) de la bipédie chez les hominides. Cah.Paleoanthropol.Paris. CNRS. p39-48.
137. **Ruff, C** (1987): Structural allometry of the femur and tibia in Hominoidea and *Macaca*. Folia Primatol. 48, p9-49.
138. **Santaguida, PL** and **McGill, SM** (1995): The psoas major muscle - A 3-dimensional geometric study. J.Biomech. 28(3), p339-345.
139. **Sarmiento, EE** (1983): The significance of the heel process in anthropoids. Int.J.Primatol. 4(2), p127-152.
140. **Sarmiento, EE** (1988): Anatomy of the hominoid wrist joint: Its evolutionary and functional implications. Int.J.Primatol. 9, p281-345.
141. **Schieppati, M; Nardone, A; Siliotto, R** and **Grasso, M** (1995): Early and late stretch responses of human foot muscles induced by perturbation of stance. Exp.Brain Res. 105(3), p411-422.
142. **von Schroeder, HP** and **Botte, MJ** (1993): The functional significance of the long extensors and juncturae tendinum in finger extension. J.Hand.Surg.(Am.Vol.). 18A(4), p641-647.
143. **von Schroeder, HP** and **Botte, MJ** (1995): Anatomy of the extensor tendons of the fingers - variations and multiplicity. J.Hand.Surg.(Am.Vol.). 20A(1), p27-34.
144. **von Schroeder, HP** and **Botte, MJ** (1997): Functional anatomy of the extensor tendons of the digits. Hand Clinics. 13(1), p51-64.
145. **Schultz, AH** (1926): Fetal growth of man and other primates. Q.Rev.Biol. 1, p465-521.
146. **Schultz, AH** (1930): The skeleton of the trunk and limbs of higher primates. Human Biol. 2, p303-438.
147. **Schultz, AH** (1937): Proportions, variability and asymmetries of the long bones of the limbs and the clavicles in man and apes. Human Biol. 5, p212-255.

148. **Schultz, AH** (1938): The relative weight of the testes in primates. *Anat.Rec.* 72, p387-394.
149. **Schultz, AH** (1949): Sex differences in the pelves of primates. *Am.J.Phys.Anthropol.* 7, p401-423.
150. **Schultz, AH** (1953): The relative thickness of the long bones and the vertebrae in primates. *Am.J.Phys.Anthropol.* 11, p277-311.
151. **Schultz, AH** (1963): Relations between the lengths of the main parts of the foot skeleton in primates. *Folia Primatol.* 1, p150-171.
152. **Schwartz, GG** and **Rosenblum, LA** (1981): Allometry of primate hair density and the evolution of human hairlessness. *Am.J.Phys.Anthropol.* 55, p9-12.
153. **Senut, B** (1982): Reflexions sur la brachiation et l'origine des hominides a la lumiere des hominoides Miocenes et des hominides Plio-Pleistocenes. *Geobios.* 6, p335-344.
154. **Senut, B** (1989): La locomotion des pre-hominids. *Proc. 2nd Int.Congr.Hum.Paleont.* 2, p53-60.
155. **Sewell, RBS** (1906): A study of the astragalus. Part IV. *J.Anat.Phys.* 40, p152-161.
156. **Sharkey, NA; Ferris, L; Smith, TS** and **Matthews, DK** (1995): Strain and loading of the 2nd metatarsal during heel-lift. *J.Bone Jt.Surg.(Am.Vol.)*. 77A(7), p1050-1057.
157. **Short, RV** (1977): Sexual selection and the descent of man. In: **Calaby, JH** and **Tyndale-Biscoe, CH**(eds); *Reproduction and Evolution*. Australian Academy of Sciences, Canberra; p3-19.
158. **Shoshani, J; Groves, CP; Simons, EL** and **Gunnell, GF** (1996): Primate phylogeny: morphological vs. molecular results. *Mol.Phyl.Evol.* 5, p101-153.
159. **Sigmon, BA** (1969): The scansorius muscle in pongids. *Primates.* 10, p247-261.
160. **Sigmon, BA** (1974): A functional analysis of pongid hip and thigh musculature. *J.Hum.Evol.* 3, p161-185.

161. **Sigmon, BA** (1975): Functions and evolution of hominid hip and thigh musculature. In: Tuttle,RH(ed); Primate functional morphology and evolution. Mouton, The Hague; p235-252.
162. **Smutz, WP; Kongsayreepong, A; Hughes, RE; Niebur, G; Cooney, WP and An, KN** (1998): Mechanical advantage of the thumb muscles. *J.Biomech.* 31(6), p565-570.
163. **Steindler, A** (1955): *Kinesiology of the human body.* Charles C.Thomas; Springfield, Illinois.
164. **Stern, JT** (1972): Anatomical and functional specializations of the human gluteus maximus. *Am.J.Phys.Anthropol.* 36, p315-340.
165. **Stern, JT Jr** (1975): Before bipedality. *Yearb.Phys.Anthropol.* 19, p59-68.
166. **Stern, JT Jr and Susman, RL** (1983): The locomotor anatomy of *Australopithecus afarensis.* *Am.J.Phys.Anthropol.* 60, p279-317.
167. **Stern, JT; Wells, JP; Jungers, WL; Vangor, AK and Fleagle, JG** (1980): An electromyographic study of the pectoralis major in atelines and *Hylobates* with special reference to the evolution of a pars clavicularis. *Am.J.Phys.Anthropol.* 52, p13-25.
168. **Straus, WL Jr** (1927): Growth of the human foot and its evolutionary significance. *Contr.Embryol.* 19, p93-124.
169. **Straus, WL Jr** (1941a): The phylogeny of the human forearm extensors. *Hum.Biol.* 13, p23-50.
170. **Straus, WL Jr** (1949): The riddle of man's ancestry. *Q.Rev.Biol.* 24, p200-223.
171. **Straus, WL Jr** (1950): Microscopic anatomy of the gorilla skin. In: Gregory,WK(ed); *The anatomy of the gorilla.* Columbia University Press, New York; p213-227.
172. **Tague, RG and Lovejoy, CO** (1986): The obstetric pelvis of A.L.288-1 (Lucy). *J.Hum.Evol.* 15, p237-255.

173. **Tappen, NC** (1955): Relative weights of some functionally important muscles of the thigh, hip and leg in a gibbon and in man. *Am.J.Phys.Anthropol.* 13(3), p415-420.
174. **Terry, GC and La Prade, RF** (1996): The biceps femoris muscle complex at the knee - Its anatomy and injury patterns associated with acute anterolateral- anteromedial rotatory instability. *Am.J.Sports Med.* 24(1), p2-8.
175. **Thomson, A** (1915): On the presence of genial tubercles on the mandible of man, and their suggested association with the faculty of speech. *J.Anat.Phys.* 50, p43-74.
176. **Thordarson, DB; Schmotzer, H; Chon, J and Peters, J** (1995): Dynamic support of the human longitudinal arch - a biomechanical evaluation. *Clin.Orthop.Relat.Res.* 316, p165-172.
177. **Tonks, AM; Lawrence, J and Lovie, MJ** (1995): Comparison of ulnar and radial arterial blood-flow at the wrist. *J.Hand.Surg.* 20B, p240-242.
178. **Travill, AA** (1962): Electromyographic study of the extensor apparatus of the forearm. *Anat.Rec.* 144, p373-376.
179. **Tuttle, RH** (1967): Knuckle-walking and the evolution of hominid hands. *Am.J.Phys.Anthropol.* 26, p171-206.
180. **Tuttle, RH** (1969a): Knuckle-walking and the problems of human origins. *Science.* 166, p953-961.
181. **Tuttle, RH** (1969b): Quantitative and functional studies on the hands of the Anthropoidea. *J.Morphol.* 128, p309-364.
182. **Tuttle, RH** (1969c): Terrestrial trends in the hands of Anthropoidea. *Proc.2nd Int.Congr.Primatol.* 2, p192-200.
183. **Tuttle, RH** (1974b): Darwin's apes, dental apes, and the descent of man: normal science in evolutionary anthropology. *Curr.Anthr.* 15, p389-398.
184. **Tuttle, RH** (1975): Parallelism, brachiation, and hominoid phylogeny. In: *Luckett,WP and Szalay,FS (eds); Phylogeny of the primates: A multidisciplinary approach.* Plenum Press, New York.

185. **Tuttle, RH and Basmajian, BV (1974a):** Electromyography of brachial muscles in *Pan gorilla* and hominoid evolution. *Am.J.Phys.Anthropol.* 41, p71-90.
186. **Tuttle, RH and Basmajian, JV (1974b):** Electromyography of forearm musculature in *Gorilla* and problems related to knuckle-walking. In: Jenkins,FA (ed); *Primate locomotion*. Academic Press, New York.
187. **Tuttle, RH and Basmajian, BV (1978b):** Electromyography of pongid shoulder muscles. III. Quadrupedal positional behaviour. *Am.J.Phys.Anthropol.* 49, p57-78.
188. **Tuttle, RH and Rogers, CM (1966):** Genetic and selective factors in reduction of the hallux in *Pongo pygmaeus*. *Am.J.Phys.Anthropol.* 24, p191-198.
189. **Tuttle, RH; Basmajian, BV and Ishida, H (1975):** Electromyography of the gluteus maximus in *Gorilla* and the evolution of bipedalism. In: Tuttle,RH (ed); *Primate functional morphology and evolution*. Mouton, The Hague.
190. **Tuttle, RH; Basmajian, BV and Ishida, H (1978):** Electromyography of pongid gluteal muscles and hominid evolution. *Recent Adv.Primatol.* 3, p463-468.
191. **Tuttle, RH; Cortright, GW and Buxhoeveden, DP (1979b):** Anthropology on the move: Progress in experimental studies of nonhuman primate positional behavior. *Yearb.Phys.Anthropol.* 22, p187-214.
192. **Valentino, B and Melito, F (1991):** Functional-relationships between the muscles of mastication and the muscles of the leg - an electromyographic study. *Surg.Radiol.Anat.* 13(1), p33-37.
193. **Warwick, P and Williams, PL (1973):** Gray's Anatomy. 35th British Edition. Saunders Co., Philadelphia.
194. **Washburn, SL (1973):** Primate field studies. In: Bourne,GH (ed): *Nonhuman primates and medical research*. Academic Press, London/New York.
195. **Wheeler, PE (1991):** The influence of bipedalism on the energy and water budgets of early hominids. *J.Hum.Evol.* 21, p117-136.

196. **Winkler, LA** (1991): Morphology and variability of masticatory structures in the orangutan. *Int.J.Primatol.* 12(9), p45-65.
197. **Wuringer, E; Mader, N; Posch, E and Holle, J** (1998): Nerve and vessel supplying ligamentous suspension of the mammary gland. *Plast.Reconstr.Surg.* 101(6), p1486-1493.
198. **Yamazaki, N and Ishida, H** (1984): A biomechanical study of vertical climbing and bipedal walking in gibbons. *J.Hum.Evol.* 13, p563-571.
199. **Yirga, S** (1987): Interrelation between ischium, thigh extending muscles and locomotion in some primates. *Primates.* 28 (1), p79-86.
200. **Ziegler, AC** (1964): Brachiating adaptations of chimpanzee upper limb musculature. *Am.J.Phys.Anthropol.* 22, p15-32.
201. **Zihlman, A and Bruner, L** (1979): Hominid bipedalism: Then and now. *Yearb.Phys.Anthropol.* 22, p132-162.

**APPENDICES**



## APPENDIX 1

### DATASET A

#### MUSCLES: HINDLIMB (Characters 1-53)

- 1 Piriformis fused with gluteus medius.  
Character states:- 0= Yes; 1= Variable
- 2 Origin of gluteus minimus is continuous.  
Character states:- 0= Yes; 1= Variable; 2= No
- 3 Gluteus medius origination from the fascia lata.  
Character states:- 0= No; 1= Yes
- 4 Gluteus medius is bipinnate.  
Character states:- 0= No; 1= Yes
- 5 Tensor fascia latae fused proximally with gluteus maximus.  
Character states:- 0= Yes; 1= Variable
- 6 Tensor fascia latae fused laterally with gluteus medius and minimus.  
Character states:- 0= Yes; 1= No
- 7 Gluteus maximus fused with biceps femoris.  
Character states:- 0= At origin, 1= No fusion, 2= More distally
- 8 Gluteus maximus insertion into the hypertrochanteric fossa.  
Character states:- 0= No; 1= Yes
- 9 Superior gemellus absent.  
Character states:- 0= Variable; 1= Yes; 2= No
- 10 Quadratus femoris split at insertion.  
Character states:- 0= Yes; 1= Variable; 2= No
- 11 Obturator externus fused at insertion with obturator internus.  
Character states:- 0= Yes; 1= Variable
- 12 Gracilis origin extends to the whole pubic body.  
Character states:- 0= Yes; 1= No
- 13 Single origin of adductor brevis.  
Character states:- 0= Yes; 1= Variable; 2= No
- 14 Adductor brevis origination from the superior pubic ramus.  
Character states:- 0= No; 1= Yes
- 15 Adductor brevis inserted between pectineus and upper part of adductor magnus.  
Character states:- 0= Yes; 1= No

16 Adductor magnus insertion into inferior border of quadratus femoris insertion.

Character states:- 0= Yes; 1= No

17 Adductor minimus absent.

Character states:- 0= Yes; 1= Variable; 2= Yes

18 Rectus femoris has two heads.

Character states:- 0= No; 1= Variable; 2= Yes

19 Vastus medialis origination from the intermuscular septa.

Character states:- 0= No; 1= Yes

20 Vastus medialis insertion onto the medial patellar surface.

Character states:- 0= No; 1= Variable; 2= Yes

21 Vastus lateralis origination from the iliofemoral ligament.

Character states:- 0= No; 1= Yes

22 Articularis genu present.

Character states:- 0= Yes; 1= Variable

23 Origin of short head of biceps femoris.

Character states:- 0= Posterolateral femur and lateral intermuscular septum; 1= Posterolateral femur only

24 Insertion of long head of biceps femoris into iliotibial tract.

Character states:- 0= No; 1= Yes

25 Insertion of short head of biceps femoris onto lateral intermuscular septum.

Character states:- 0= No; 1= Yes

26 Common origin of semitendinosus and semimembranosus in some specimens.

Character states:- 0= No; 1= Yes

27 Semimembranosus insertion into the popliteal fascia, and the posterior wall of knee capsule via oblique popliteal ligaments.

Character states:- 0= No; 1= Yes

28 Tibialis anterior origination from the crural fascia.

Character states:- 0= No; 1= Yes

29 Extensor digitorum origination from the crural fascia.

Character states:- 0= No; 1= Yes

30 Peroneus tertius present.

Character states:- 0= Yes (30-50%), 1= Yes (5%) or No; 2= Yes (95%)

31 Peroneus longus origination from the lateral tibial condyle.

Character states:- 0= Yes; 1= No

- 32 Peroneus brevis insertion onto second and third phalanges of digit V.  
Character states:- 0= No; 1= Variable
- 33 Tibial origin of soleus present.  
Character states:- 0= No; 1= Variable; 2= Yes
- 34 Plantaris absent.  
Character states:- 0= Yes; 1= Majority, 2= 50%, 3= 5-10%
- 35 Extensor digitorum brevis tendon to digit V present in some specimens.  
Character states:- 0= Yes; 1= No; 2= Variable
- 36 Slip from abductor hallucis into base of MI.  
Character states:- 0= Yes; 1= No
- 37 Both heads of flexor hallucis brevis fused with abductor hallucis.  
Character states:- 0= Yes; 1= No
- 38 Lateral head of flexor hallucis brevis fused with adductor hallucis.  
Character states:- 0= No; 1= Yes
- 39 Two heads of adductor hallucis fused.  
Character states:- 0= Yes; 1= Variable; 2= No
- 40 Oblique head of adductor hallucis origination from sheath of peroneus longus.  
Character states:- 0= No; 1= Yes
- 41 Insertion of abductor hallucis onto medial cuneiform in some specimens.  
Character states:- 0= No; 1= Yes
- 42 Medial and lateral heads of flexor hallucis brevis separated by septum.  
Character states:- 0= No; 1= Yes
- 43 Slip from abductor hallucis to base of MI present.  
Character states:- 0= Yes; 1= No
- 44 Both heads of flexor hallucis brevis fused with abductor hallucis.  
Character states:- 0= Yes; 1= No
- 45<sup>3</sup> Flexor hallucis brevis insertion into MI.  
Character states:- 0= Yes; 1= No
- 46 Heads of adductor hallucis fused.  
Character states:- 0= Variable; 1= No
- 47<sup>4</sup> Origin of transverse head of adductor hallucis.  
Character states:- 0= MIV, second, third and fourth metatarsophalangeal joints and ligaments; 1= Third, fourth (fifth) metatarsophalangeal joints and ligaments; 2= MIV; 3= Neither

~~48~~<sup>5</sup> Opponens hallucis present.

Character states:- 0= Variable; 1= Yes

~~49~~<sup>6</sup> Abductor os metatarsi digiti minimi present.

Character states:- 0= No; 1= Variable; 2= Yes

~~50~~<sup>47</sup> Fourth dorsal interosseous has two heads.

Character states:- 0= Yes; 1= No

~~51~~<sup>48</sup> Origin of first dorsal interosseous.

Character states:- 0= Medial side MII; 1= Lateral side MI, medial side MII, 2= Medial cuneiform, medial side MII

~~52~~<sup>49</sup> Flexor digitorum brevis origination from the plantar aponeurosis.

Character states:- 0= No; 1= Yes

~~53~~<sup>50</sup> Flexor digitorum brevis fused with abductor hallucis in some specimens.

Character states:- 0= No; 1= Yes

**MUSCLES: FORELIMB (Characters 54-99)**

54 Abductor pollicis brevis divides into slips.

Character states:- 0= No; 1= Variable; 2= Yes

55 Occasional reinforcement of abductor pollicis brevis by slips from flexor pollicis brevis.

Character states:- 0= Yes; 1= No

56 Abductor pollicis brevis insertion into MI.

Character states:- 0= Yes; 1= No

57 Site of origin of radial head of flexor pollicis brevis.

Character states:- 0= Flexor retinaculum and MI; 1= Flexor retinaculum, MI and trapezium; 2= Flexor retinaculum and trapezium

58 Opponens pollicis sends slips forward to radial side of the base of proximal and middle phalanges.

Character states:- 0= Yes; 1= No

59 Presence/absence of palmaris brevis.

Character states:- 0= Absent; 1= Variable; 2= Present

60 Site of origin of pronator teres.

Character states:- 0= Medial humeral epicondyle; 1= Medial humeral epicondyle; medial intermuscular septum

61 Humeral head of pronator teres fused with flexor carpi radialis.

Character states:- 0= No; 1= Yes

62 Humeroulnar head of flexor digitorum superficialis takes origin from the intermuscular septum.

Character states:- 0= No; 1= Yes

63 Flexor carpi radialis insertion into intermuscular septum.

Character states:- 0= No; 1= Yes

64 Flexor carpi radialis fused with flexor digitorum superficialis.

Character states:- 0= No; 1= Yes

65 Flexor carpi radialis insertion into palmar surface of base of MIII.

Character states:- 0= Variable; 1= Yes

66 Presence/absence of palmaris longus.

Character states:- 0= Variable; 1= Present

67 Flexor carpi ulnaris origination from the intermuscular septum.

Character states:- 0= No; 1= Yes

68 Flexor carpi ulnaris gives origin to some fibres for flexor digitorum superficialis.

Character states:- 0= No; 1= Yes

69 Orientation of pronator quadratus.

Character states:- 0= Strongly oblique; 1= Moderately oblique; 2= Weakly oblique

70 Extension of origin of flexor digitorum profundus.

Character states:- 0= None; 1= Medial coronoid process; 2= Medial humeral condyle; 3= Both

71 Flexor pollicis longus origination from the anterior radius and interosseous membrane.

Character states:- 0= No; 1= Yes

72 Flexor pollicis longus takes origin from the palmar fascia.

Character states:- 0= No; 1= Yes

73 Flexor pollicis longus gives origin to tendon to digit II.

Character states:- 0= No; 1= Variable; 2= Yes

74 Extensor carpi radialis brevis origination from the radial collateral ligament.

Character states:- 0= No; 1= Yes

75 Origin of extensor carpi radialis brevis from the intermuscular septum.

Character states:- 0= No; 1= Yes

76 Insertion of extensor carpi radialis brevis to MII.

Character states:- 0= Yes; 1= Variable; 2= No

77 Accessory tendon of extensor carpi radialis longus to MI.

Character states:- 0= No; 1= Variable (4-12%), 2= Variable (50%)

78 Fusion of brachioradialis with brachialis.

Character states:- 0= Yes; 1= Variable; 2= No

79 Extensor digitorum origination from the intermuscular septum.

Character states:- 0= No; 1= Yes

80 Origin of extensor digitorum from the radius and/or ulna in some specimens.

Character states:- 0= Ulna, 1= Radius and ulna, 2= Neither

81 Origin of extensor digitorum from the antebrachial fascia.

Character states:- 0= No; 1= Yes

82 Slips from extensor digitorum tendon for digit IV.

Character states:- 0= To digit V, 1= To digit II, digit V, 2= To digit III

83 Coracobrachialis origination from the intermuscular septum in some specimens.

Character states:- 0= No; 1= Yes

84 Coracobrachialis fused with brachialis.

Character states:- 0= No; 1= Yes

85 Multiple parts of coracobrachialis present in some specimens.

Character states:- 0= No; 1= Yes

86 Extension of insertion of coracobrachialis.

Character states:- 0= None; 1= Anteriorly, 2= Anteriorly and distally, 3= Distally

87 Brachialis origination from the intermuscular septa.

Character states:- 0= No; 1= Yes

88 Lateral head of triceps brachii origination from the lateral intermuscular septum.

Character states:- 0= No; 1= Yes

89 Insertion of extensor digitorum extends into middle or distal phalanges in some specimens.

Character states:- 0= No; 1= Yes

90 Insertion of extensor digitorum into interphalangeal joints.

Character states:- 0= No; 1= Yes

91 Ulnar origin for extensor digiti minimi in some specimens.

Character states:- 0= Yes; 1= No

92 Extensor digiti minimi absent from some specimens.

Character states:- 0= No; 1= Yes

93 Extension of extensor carpi ulnaris to first phalanx of digit V in some specimens.

Character states:- 0= No; 1= Yes

94 Supinator origination from the ligaments of elbow.

Character states:- 0= No; 1= Yes

95 Abductor pollicis longus origination from the intermuscular septum.

Character states:- 0= No; 1= Yes

96 Extensor pollicis brevis origination from the ulna and interosseous membrane.

Character states:- 0= No; 1= Yes

97 Extensor pollicis brevis insertion onto base of proximal phalanx of digit I.

Character states:- 0= No; 1= Yes

98 Extensor indicis origination from the interosseous membrane.

Character states:- 0= Yes; 1= No

99 Most common pattern of insertion of extensor indicis.

Character states:- 0= Digits II, III, IV, 1= Digits II and III, 2= Digit II

### SKIN (Characters 100-103)

197 ~~100~~ Ranked position of average total body hair density/cm<sup>2</sup>.

Character states:- 0= 3; 1= 8 or 9; 2= 12 or 13

198 ~~101~~ Sternal glands.

Character states:- 0= Present; 1= Absent

199 ~~102~~ Ratio of nipple position to horizontal height index of nipple position.

Character states:- 0= 2.625; 1= 1.654 and 1.783; 2= 1.011 and 1.070

200 ~~103~~ Axillary organ.

Character states:- 0= Absent; 1= Present

### CRANIAL (Characters 104-111)

125 ~~104~~ Number of bellies of omohyoid.

Character states:- 0= Three; 1= One; 2= Two or three; 3= One; two or three

126 ~~105~~ Anterior bellies of digastric in contact in midline.

Character states:- 0= Yes; 1= No

127 ~~106~~ Cricothyroid insertion onto the external surface of the posterior thyroid lamina.

Character states:- 0= Yes; 1= No

128 ~~107~~ Apex of tongue.

Character states:- 0= Rounded, 1= Square

129 ~~108~~ Apical lingual gland present/absent.

Character states:- 0= Absent; 1= Variable; 2= Present

130 ~~109~~ Filiform papillae on posterior third of tongue.

Character states:- 0= Present; 1= Absent

131 ~~110~~ Conical filiform predominate over cylindrical filiform.

Character states:- 0= Yes; 1= No

132 ~~111~~ Sublingual fold triangular.

Character states:- 0= Yes; 1= No

**BACK (Characters 112-119)**

100 ~~112~~ Deltoid origination from the infraspinous fascia.

Character states:- 0= No; 1= Yes

101 ~~113~~ Insertion of teres minor.

Character states:- 0= Greater tubercle; 1= Greater tubercle and shaft below; 2= Greater tubercle, shaft below and humeral head, 3= Greater tubercle and humeral head only;

102 ~~114~~ Origin of teres minor.

Character states:- 0= Lateral border; 1= Lateral border and intermuscular septum; 2= Lateral border and intermuscular septum, separated from teres major by long head of triceps

103 ~~115~~ Latissimus dorsi origination from the inferior scapular angle.

Character states:- 0= No; 1= Variable; 2= Yes

104 ~~116~~ Extent of costal origin of latissimus dorsi.

Character states:- 0= Five ribs; 1= Four or five ribs; 2= Six ribs; 3= Three ribs

105 ~~117~~ Extent of origin of teres major from the lateral scapular border.

Character states:- 0= 30%; 1= 50%; 2= More than 50%

106 ~~118~~ Insertion of subscapularis.

Character states:- 0= Lesser humeral tubercle; 1= Lesser humeral tubercle and shaft below; 2= Lesser humeral tubercle, shaft below and capsule of shoulder joint; 3= Lesser humeral tubercle and capsule of shoulder joint

107 ~~119~~ Accessory bundles of subscapularis absent/present.

Character states:- 0= Absent; 1= Variable

**THORAX (Characters 120-128)**

108 ~~120~~ Extent of costal origin of subclavius.

Character states:- 0= First; second, third ribs; 1= First and second ribs; 2= First rib

109 ~~121~~ Extent of costal origin of serratus anterior.

Character states:- 0= 1-9, 10 and 11; 1= 1-9, 10, 11 and last rib; 2= 1-9 (10)

110 ~~122~~ Pectoralis major insertion into tendon of short head of biceps brachii.

Character states:- 0= Yes; 1= No

111 ~~123~~ Extent of costal origin of pectoralis major.

Character states:- 0= None; 1= Cranial and caudal; 2= Caudal; 3= Cranial



- 112 ~~124~~ Cranial extent of costal origin of pectoralis major.  
Character states:- 0= Absent; 1= Second rib; 2= First rib
- 113 ~~125~~ Caudal extent of costal origin of pectoralis major.  
Character states:- 0= Absent; 1= Seventh rib; 2= Eighth rib
- 114 ~~126~~ Extent of clavicular origin of pectoralis major.  
Character states:- 0= Two-thirds; 1= Half; 2= Medial third
- 115 ~~127~~ Incidence of absence of clavicular head of pectoralis major.  
Character states:- 0= No; 1= Yes (30%); 2= Yes (80%)
- 116 ~~128~~ Divisions of pectoralis major.  
Character states:- 0= Two parts; 1= Variable

**ABDOMEN AND PELVIS (Characters 129-143)**

- 117 ~~129~~ Origin of psoas major extends to S1.  
Character states:- 0= Yes; 1= Variable; 2= No
- 118 ~~130~~ Origin of psoas minor from T12.  
Character states:- 0= Variable; 1= Yes
- 119 ~~131~~ Origin of psoas minor from L2.  
Character states:- 0= Variable (30%); 1= Variable (50%); 2= Variable (75%); 3= No
- 120 ~~132~~ Bulbospongiosus origination from the ischial ramus.  
Character states:- 0= Yes; 1= No
- 121 ~~133~~ Bulbospongiosus origination from the perineal body.  
Character states:- 0= No; 1= Variable; 2= Yes
- 122 ~~134~~ Coccygeus insertion into the anococcygeal raphe.  
Character states:- 0= Yes; 1= No
- 123 ~~135~~ Coccygeus insertion into the sacrum.  
Character states:- 0= No; 1= Yes

136. See 143 on p. 637.

- 190 ~~1387~~ Penile spines present/absent.  
Character states:- 0= Present; 1= Absent

GENITO-URINARY SYSTEM  
(Characters 137-143)

- 191 ~~1378~~ Ventral groove in glans penis present/absent.  
Character states:- 0= Present; 1= Absent
- 192 ~~1389~~ Scrotal position.  
Character states:- 0= Pre; para or postpenial; 1= Postpenial or para/postpenial; 2= Postpenial
- 193 ~~1390~~ Dependency of scrotum.  
Character states:- 0= Variable; 1= Dependant; 2= Non-dependant
- 194 ~~1401~~ Relative testes size (ratio of observed/predicted body testes size).

Character states:- 0= 0.31-0.33; 1= 0.14; 2= 0.50; 3= 1.53

145 ~~142~~ Urethral papilla present/absent.

Character states:- 0= Present; 1= Absent

146 ~~143~~ Transverse rugae of vagina.

Character states:- 0= Less developed; 1= More developed

124 ~~143~~ Number of taeniae coli.

Character states:- 0= Three; 1= Four; 2= Variable

**VESSELS: BACK (Character 144)**

133 ~~144~~ Origin of subscapular artery.

Character states:- 0= Common trunk; 1= Axillary artery

**VESSELS: THORAX (Characters 145-149)**

134 ~~145~~ Origin of lateral thoracic artery.

Character states:- 0= Thoracoacromial artery; 1= Axillary artery

135 ~~146~~ Pectoral branch of thoracoacromial artery present/absent.

Character states:- 0= Absent; 1= Variable; 2= Present

136 ~~147~~ Supreme thoracic artery present/absent.

Character states:- 0= Absent; 1= Present

137 ~~148~~ Thyroidea ima arises from the left common carotid in some specimens.

Character states:- 0= Yes; 1= No

138 ~~149~~ Most common form of branches from the aortic arch.

Character states:- 0= E; 1= B; 2= C

**VESSELS: HINDLIMB (Characters 150-158)**

139 ~~150~~ Perforating branch of peroneal artery anastomoses with anterior lateral malleolar artery.

Character states:- 0= Yes; 1= No

140 ~~151~~ Origin of peroneal artery.

Character states:- 0= Posterior tibial artery; 1= Popliteal artery; 2= Anterior tibial artery

141 ~~152~~ Digital branches of deep plantar arch to adjacent sides of II and III, present/absent.

Character states:- 0= Present; 1= Variable; 2= Absent

142 ~~153~~ Size of lateral plantar artery.

Character states:- 0= Absent; 1= Smaller than medial plantar; 2= Equal to medial plantar; 3= Larger than medial plantar

143 ~~154~~ Inferior medial and inferior lateral genicular branches of popliteal artery present/absent.

Character states:- 0= Present; 1= Absent

144 ~~155~~ Origin of medial femoral circumflex artery.

Character states:- 0= External iliac; 1= Variable; 2= Profunda femoris; 3= Femoral artery

145 ~~156~~ Number of perforating branches of profunda femoris.

Character states:- 0= Two; 1= None; 2= Three

146 ~~157~~ Muscular branches of profunda femoris for hamstrings.

Character states:- 0= No; 1= Yes

147 ~~158~~ Muscular branches of profunda femoris for quadriceps.

Character states:- 0= No; 1= Yes

**VESSELS: FORELIMB (Characters 159-175)**

148 ~~159~~ Perforating veins in cubital fossa.

Character states:- 0= Present; 1= Variable; 2= Absent

149 ~~160~~ Basilic vein.

Character states:- 0= Absent; 1= Variable; 2= Present

150 ~~161~~ Cephalic vein "short" in some specimens.

Character states:- 0= No; 1= Yes (20-25%); 2= Yes (80-100%)

151 ~~162~~ Origin of palmar metacarpal arteries.

Character states:- 0= Deep palmar arch; 1= Radial artery; 2= Absent

152 ~~163~~ Origin of radialis indicus.

Character states:- 0= Deep palmar arch; 1= First palmar metacarpal artery; 2= Radial artery

153 ~~164~~ Superficial palmar arch present/absent.

Character states:- 0= Variable; 1= Absent; 2= Present

154 ~~165~~ Origin of posterior interosseous artery.

Character states:- 0= Brachial artery; 1= Common interosseous

155 ~~166~~ Anterior and posterior ulnar recurrent arteries originate from the common trunk.

Character states:- 0= Yes; 1= Variable; 2= No

156 ~~167~~ Palmar carpal branch of ulnar artery.

Character states:- 0= Present; 1= Absent

157 ~~168~~ Dorsalis indicis and dorsal metacarpal branches of ulnar artery.

Character states:- 0= Absent; 1= Present

158 ~~169~~ Termination of superficial palmar artery.

Character states:- 0= Thenar muscles; 1= Superficial palmar arch

159

~~170~~ Superficial palmar artery passes over the thenar muscles in some specimens.

Character states:- 0= No; 1= Yes

160 ~~171~~ Origin of radial recurrent artery.

Character states:- 0= Radial artery; 1= Variable; 2= Brachial artery

161 ~~172~~ Dorsalis pollicis.

Character states:- 0= Present; 1= Absent

162 ~~173~~ Point at which radial artery enters palm.

Character states:- 0= Dorsum of second interosseous space; 1= Dorsum of first interosseous space

163 ~~174~~ Origin of superior ulnar collateral artery.

Character states:- 0= Profunda brachii; 1= Brachial artery

164 ~~175~~ Profunda brachii origination from the brachial artery in some specimens.

Character states:- 0= No; 1= Yes

**NERVES: BACK (Character 176-177)**

165 ~~176~~ Latissimus dorsi innervated in common with teres major.

Character states:- 0= Yes; 1= Variable; 2= No

166 ~~177~~ Origin of subscapular nerves.

Character states:- 0= C5, C6, C7; 1= C5, C6, C7, C8; 2= C5, C6, C7, C8, T1; 3= C5, C6

**NERVES: FORELIMB (Characters 178-187)**

180 ~~178~~ Number of lumbricals supplied by median nerve.

Character states:- 0= Two; 1= Two or three; 2= One or two

181 ~~179~~ Number of digits supplied by median nerve.

Character states:- 0= 2.5; 1= 3.5

182 ~~180~~ Digits supplied by radial nerve.

Character states:- 0= 1.5; 1= 2.5

183 ~~181~~ Radial nerve innervates brachioradialis.

Character states:- 0= No; 1= Yes

184 ~~182~~ Gangliform enlargement at junction of radial and posterior interosseous nerves.

Character states:- 0= Absent; 1= Present

185 ~~183~~ Axillary nerve innervates subscapularis.

Character states:- 0= No; 1= Yes

186 ~~184~~ Origin of axillary nerve.

Character states:- 0= C5, C6, C7, C8; 1= C5, C6, C7, C8, T1; 2= C5, C6, C7

187 ~~185~~ Number of lumbricals innervated by ulnar nerve.

Character states:- 0= Two; 1= One; 2= Three

188 ~~186~~ Ulnar nerve innervates flexor pollicis brevis in some specimens.

Character states:- 0= No; 1= Yes (~50%); 2= Yes (100%)

189 ~~187~~ Ulnar nerve supplies hypothenar muscles.

Character states:- 0= No; 1= Yes

**NERVES: THORAX (Character 188)**

167 ~~188~~ Intercostobrachial nerve includes elements from T3 in some specimens.

Character states:- 0= No; 1= Yes

**NERVES: ABDOMEN AND PELVIS (Character 189)**

168 ~~189~~ Psoas minor innervated by femoral nerve.

Character states:- 0= No; 1= Yes

**NERVES: HINDLIMB (Characters 190-200)**

169 ~~190~~ Origin of lateral cutaneous femoral nerve from L1 and L3.

Character states:- 0= No; 1= Variable; 2= Yes

170 ~~191~~ Femoral nerve origination from L1 and L4.

Character states:- 0= L4; 1= Variable; 2= L1

171 ~~192~~ Genitofemoral nerve origination from L2.

Character states:- 0= Yes; 1= No

172 ~~193~~ Genitofemoral nerve pierces psoas major.

Character states:- 0= Yes; 1= Variable

173 ~~194~~ Obturator nerve origination from L1.

Character states:- 0= No; 1= Yes

174 ~~195~~ Muscular branches of the obturator nerve.

Character states:- 0= Adductors, obturator externus, gracilis; 1= Adductors, obturator externus, gracilis, pectineus

175 ~~196~~ Muscular branches of the medial plantar nerve.

Character states:- 0= Two medial lumbricals; 1= Two medial lumbricals; adductor hallucis; 2= One medial lumbrical

176 ~~197~~ Digital branches of the lateral plantar nerve.

Character states:- 0= 1.5; 1= 2.5

177 ~~198~~ Muscular branches of the tibial nerve.

Character states:- 0= None of these; 1= Flexor digitorum longus; 2= Flexor digitorum longus, tibialis posterior, flexor hallucis longus

178 ~~199~~ Superficial peroneal nerve supplies medial side of digit II.

Character states:- 0= Yes; 1= No

179 200 Flexores femoris nerve present/absent.

Character states:- 0= Yes; 1= Variable; 2= No

## APPENDIX 2

### DATA MATRIX FOR DATASET A

	1 <sup>ii</sup>	2	3	4	5	6	7	8	9	10	11	12	13	14	15	16	17	18	19	20	21	22	
<i>Hylobates</i>	0	0	0	0	0	0	0	0	1	0	0	0	0	0	0	0	0	0	0	0	0	0	0
<i>Pongo</i>	0	2	1	0	0	1	2	1	0	0	1	1	2	1	1	0	1	1	1	0	1	1	1
<i>Gorilla</i>	1	2	1	1	0	0	0	1	0	2	1	0	1	1	1	1	1	1	0	1	1	1	0
<i>Pan</i>	1	2	1	1	1	0	0	1	2	1	0	0	2	1	1	1	1	1	0	0	0	1	0
<i>Homo</i>	1	1	0	0	1	1	1	0	0	2	?	1	1	0	0	1	2	2	1	2	0	1	1

	23	24	25	26	27	28	29	30	31	32	33	34	35	36	37	38	39	40	41	42	<del>43</del>	<del>44</del>
<i>Hylobates</i>	0	0	0	0	0	0	0	0	0	0	0	0	0	0	0	0	0	0	0	0	<del>0</del>	<del>0</del>
<i>Pongo</i>	1	1	1	1	0	1	0	1	1	0	0	1	1	0	1	0	2	1	0	1	<del>0</del>	<del>0</del>
<i>Gorilla</i>	1	1	0	0	1	0	0	0	1	1	1	0	1	0	1	1	2	0	0	1	<del>0</del>	<del>0</del>
<i>Pan</i>	0	1	1	1	0	0	1	1	0	1	1	2	0	1	0	0	1	1	1	0	<del>0</del>	<del>0</del>
<i>Homo</i>	0	0	0	1	1	1	1	2	0	1	2	3	2	1	1	1	2	1	1	0	<del>0</del>	<del>0</del>

3      44   45   46   47   48   49   50

	45	<del>46</del>	47	48	49	50	51	52	53	54	55	56	57	58	59	60	61	62	63	64	65	66
<i>Hylobates</i>	0	<del>0</del>	0	0	0	0	0	0	0	0	0	0	0	0	0	0	0	0	1	0	1	1
<i>Pongo</i>	0	<del>0</del>	3	1	2	0	2	0	1	0	1	1	2	1	0	1	1	0	0	1	0	1
<i>Gorilla</i>	0	<del>0</del>	2	1	2	1	2	0	0	2	1	0	1	2	1	0	0	1	0	1	1	0
<i>Pan</i>	1	<del>1</del>	0	0	0	1	1	1	1	1	0	0	0	2	1	1	1	1	1	1	0	0
<i>Homo</i>	1	<del>1</del>	1	0	1	0	1	1	0	0	1	1	0	2	2	1	0	1	1	0	1	0

<sup>ii</sup> The numbers refer to the characters listed in Appendix 1.

	67	68	69	70	71	72	73	74	75	76	77	78	79	80	81	82	83	84	85	86	87	88
<i>Hylobates</i>	0	0	0	2	0	0	1	0	0	0	2	0	0	0	0	0	0	0	0	0	0	0
<i>Pongo</i>	1	1	0	0	0	0	0	1	1	2	0	2	1	1	1	2	0	1	1	3	1	0
<i>Gorilla</i>	0	0	1	1	1	1	0	0	0	0	0	2	0	1	0	1	1	1	1	1	1	0
<i>Pan</i>	1	1	1	0	1	1	2	1	0	2	0	0	1	1	1	1	1	1	1	2	0	1
<i>Homo</i>	0	0	2	3	1	0	1	1	1	1	1	1	0	2	1	1	1	0	0	1	1	1

	89	90	91	92	93	94	95	96	97	98	99	100	101	102	103	104	105	106	107	108	109	110
<i>Hylobates</i>	0	0	0	0	0	0	0	0	0	0	0	0	0	0	0	0	0	0	0	0	0	0
<i>Pongo</i>	1	1	0	1	0	1	0	0	0	0	1	1	0	2	0	1	0	1	0	2	1	0
<i>Gorilla</i>	1	0	1	0	0	1	1	1	1	1	2	1	1	1	1	0	1	1	1	1	0	1
<i>Pan</i>	1	1	0	1	1	0	1	1	0	1	2	2	1	1	1	3	0	0	1	1	0	1
<i>Homo</i>	0	0	1	1	1	1	0	1	1	0	2	2	1	2	1	0	1	1	0	2	1	1

	111	112	113	114	115	116	117	118	119	120
<i>Hylobates</i>	0	0	0	0	0	0	0	0	0	0
<i>Pongo</i>	1	3	2	0	2	1	1	0	1	1
<i>Gorilla</i>	1	0	1	0	2	0	1	1	1	0
<i>Pan</i>	0	1	2	0	2	1	1	1	0	2
<i>Homo</i>	1	0	1	2	1	1	2	1	2	1

132-100 101 102 103 104 105 106 107 108 109 110 111 112 113 114 115 116 117 118 119 120  
 111 112 113 114 115 116 117 118 119 120 121 122 123 124 125 126 127 128 129 130 131 132



	121	122	123	124	125	126	127	128	129	130	131	132	133	134	135	136	137	138	139	140	141	142	143	144	145	146	147	148	149	150	151	152	153	154					
Hylobates	0	0	0	0	0	0	0	0	0	0	0	0	0	0	0	0	0	0	0	0	0	0	0	0	0	0	0	0	0	0	0	0	0	0	0				
Pongo	2	1	0	1	2	0	1	0	0	1	0	2	0	1	0	2	0	1	2	1	2	2	1	1	2	0	1	2	1	2	2	1	1	1	1	1			
Gorilla	1	0	1	1	2	1	0	1	2	1	0	1	1	0	1	0	1	0	1	0	0	0	0	0	1	0	1	0	0	0	0	0	0	0	0	0	0	0	
Pan	0	1	0	0	1	2	1	1	2	3	1	1	2	0	1	1	1	1	0	0	1	1	0	0	1	1	0	0	1	1	1	1	1	1	1	1	1	1	
Homo	2	1	1	1	2	1	1	2	1	2	1	1	0	1	2	1	1	1	1	0	0	0	0	1	2	1	1	0	0	0	0	0	0	0	0	0	0	0	0

	155	156	157	158	159	160	161	162	163	164	165	166	167	168	169	170	171	172	173	174	175	176	177	
Hylobates	0	0	0	0	0	0	0	0	0	0	0	0	0	0	0	0	0	0	0	0	0	0	0	0
Pongo	3	1	0	1	2	0	2	0	2	0	0	0	1	1	1	0	2	0	2	0	0	0	1	
Gorilla	3	2	0	0	1	2	0	1	1	0	2	1	1	0	1	1	0	0	0	1	1	0	2	
Pan	1	0	1	1	0	2	1	1	2	1	1	1	1	0	1	1	1	1	1	1	1	1	1	
Homo	2	2	1	1	0	2	1	0	2	2	1	1	1	0	1	1	1	0	1	1	1	1	0	

	178	179	180	181	182	183	184	185	186	187	188	189	190	191	192	193	194	195	196	197	198
Hylobates	1	0	0	0	0	0	0	0	0	0	0	0	0	0	0	0	0	0	0	0	0
Pongo	0	2	0	0	0	0	0	0	2	1	1	0	2	2	1	0	1	0	1	1	0
Gorilla	2	0	1	1	0	1	1	2	0	0	0	1	0	0	0	0	0	0	0	2	1
Pan	0	2	1	0	0	1	1	1	0	1	1	1	1	1	1	1	1	1	1	1	1
Homo	3	1	1	1	1	1	1	0	2	0	1	1	1	0	0	1	0	1	1	2	0

178 179

	<del>199</del>	200
<i>Hylobates</i>	0	0
<i>Pongo</i>	0	0
<i>Gorilla</i>	0	1
<i>Pan</i>	1	0
<i>Homo</i>	1	2

## APPENDIX 3

### DATASET B

This dataset is derived from the larger dataset of Shoshani *et al.* (1996). Numbers in parentheses at the end of the character name refer to the character number in the original paper. The criteria for character selection were as follows: Data must be available for all five species, at least two character states must be present, and one of these character states must be present in two, or more, species.

#### SKULL: MANDIBLE

1 Orientation of the mandibular symphysis - Angle in degrees (29).

Character states:- 0= Angle 170 to 155; 1= Angle 150 to 145; 2= Angle 137 to 115; 3= Angle 100 to 90 or less

#### SKULL: DENTITION

2 Honing (48).

Character states:- 0= Absent; 1= Present; 2= Reduced; 3= Further reduced

#### BODY: VERTEBRAL COLUMN AND APPENDAGES

3 Humeral supratrochlear foramen (61).

Character states:- 0= Absent; 1= Present

4 Ulnar styloid process (65).

Character states:- 0= Long; 1= Shortened; 2= Very short

5 Obturator groove or notch (70).

Character states:- 0= Absent; 1= Shallow; 2= Deep

#### CHARACTERS FROM GROVES (1986, 1995)

6 Middle ear (102).

Character states:- 0= Shallow; 1= Deepened

7 Axis of ear bones (103).

Character states:- 0= Acute angle; 1= Right angle or more

8 Area of inner ear (104).

Character states:- 0= Low; 1= Increased

9 Angle of manubrium mallei (105).

Character states:- 0= High; 1= More acute

10 Klinorhynch (106).

Character states:- 0= Airorhynch or straight; 1= More klinorhynch; 2= Strongly klinorhynch

11 Relative upper face height (108).

Character states:- 0= High; 1= Reduced

12 Facial index (109).

Character states:- 0= Low; 1= Increased

13 Mandibular symphysis (110).

Character states:- 0= Low; 1= Deepened

14 Frontal sinus (111).

Character states:- 0= Absent; 1= Present

15 Orientation of zygomatic bone (114).

Character states:- 0= More frontally; 1= More superolaterally; 2= Still further superolaterally

16 Frontal bone (115).

Character states:- 0= Flat; 1= More convex; 2= Strongly convex

17 Glabella prominence (116).

Character states:- 0= Strong; 1= Reduced; 2= Absent

18 Incisive foramen (117).

Character states:- 0= Double; 1= Single

19 Supraorbital development (119).

Character states:- 0= Weak; 1= More marked; 2= Torus-like

20 Supraorbital trigon (122).

Character states:- 0= Not developed; 1= Developed

21 Nasals (124).

Character states:- 0= Long; 1= Shortened

22 Size of incisive foramina (128).

Character states:- 0= Large; 1= Reduced; 2= Tiny

23 Premaxillary suture (130).

Character states:- 0= Patent in adult; 1= Obliterated in adult

24 Foramen lacerum medium (131).

Character states:- 0= Absent; 1= Present

25 Temporal lines (132).

Character states:- 0= Converge posteriorly; 1= Do not converge

26 Number of lumbar vertebrae (133).

Character states:- 0= High; 1= Reduced; 2= Further reduced

27 Lumbar region (134).

Character states:- 0= Long; 1= Shortened

28 Sacrum (135).

Character states:- 0= Short; 1= Enlarged

29 Relative chest girth (136).

Character states:- 0= Narrow; 1= Increased; 2= Very weak

30 Carpus (137).

Character states:- 0= No conjunct rotation; 1= Conjunct rotation

31 Os centrale (138).

Character states:- 0= Free; 1= Fused with scaphoid with age; 2= Always fused with scaphoid

32 Metacarpal heads (dorsal transverse ridges) (139).

Character states:- 0= Absent; 1= Present

33 Metacarpal heads (articular surfaces) (140).

Character states:- 0= Restricted; 1= Expanded

34 Humerus robusticity (141).

Character states:- 0= High; 1= Reduced; 2= Humerus slender

35 Radial neck (144).

Character states:- 0= Narrow; 1= Widened compared to head

36 Femur-humerus (145).

Character states:- 0= Index high; 1= Index reduced; 2= Index low

37 Talus (146).

Character states:- 0= Narrow; 1= Widened

38 Lower limb relative to trunk length (148).

Character states:- 0= Low; 1= Increased slightly; 2= Extremely elongated

39 Upper limb relative to lower limb (149).

Character states:- 0= Low; 1= Increased slightly; 2= Extremely elongated; 3= Increased even further

40 Foot length relative to trunk length (150).

Character states:- 0= Low; 1= Increased

41 Hand length relative to body height (151).

Character states:- 0= Low; 1= Increased; 2= Further lengthened

42 Power arm of foot (152).

Character states:- 0= Low; 1= Increased relative to lever; 2= Further increased

43 Dental development (153).

Character states:- 0= Early relative to epiphyseal; 1= Delayed relative to epiphyseal

44 Ankle epiphyses (154).

Character states:- 0= Delayed; 1= Not delayed

45 Trochlear keel (155).

Character states:- 0= Poor; 1= More prominent

- 46 Second cervical spine (157)  
Character states:- 0= Short; 1= Lengthened; 2= Greatly lengthened
- 47 Fifth cervical spine (158).  
Character states:- 0= Short; 1= Lengthened; 2= Greatly lengthened
- 48 I<sup>2</sup> occlusal edge (161).  
Character states:- 0= Slopes distally; 1= Does not slope distally
- 49 Basal keel of mandibular canine (163).  
Character states:- 0= Present; 1= Absent
- 50 Upper premolars; basal area of paracone (164).  
Character states:- 0= Subequal to protocone; 1= Smaller than protocone
- 51 Molar cingulum (165).  
Character states:- 0= Prominent; 1= Reduced, incomplete; 2= Fragmented or absent
- 52 Protoconid apex on dP<sub>3</sub> (166).  
Character states:- 0= More lingual from median axis; 1= Located buccally from median axis
- 53 Metaconid of dP<sub>3</sub> (167).  
Character states:- 0= Present; 1= Absent
- 54 Protocristid of dP<sub>3</sub> (168).  
Character states:- 0= Aligned with tooth mesiodistal; 1= Angled
- 55 Talonid basin of dP<sub>3</sub> (169).  
Character states:- 0= Open distally; 1= Closed
- 56 Metaconid of dP<sub>4</sub> (170).  
Character states:- 0= Subequal to protoconid; 1= Increased relative to protoconid
- 57 Crista obliqua on dP<sub>4</sub> (171).  
Character states:- 0= Does not reach protoconid apex; 1= Reaches protoconid apex
- 58 Talonid basin on dP<sub>4</sub> (172).  
Character states:- 0= Open distally; 1= Closed
- 59 Protocone of dP<sup>3</sup> in crown view (173).  
Character states:- 0= Larger than paracone; 1= Smaller than paracone
- 60 Postprotocristids of dP<sup>4</sup> (175).  
Character states:- 0= Poor; 1= More developed; 2= Still more developed
- 61 Molars; protocristid grooves (176).  
Character states:- 0= Prominent; 1= Barely visible
- 62 Enamel thickness on molars (178).

Character states:- 0= Thin; 1= Increased thickness; 2= Very thick

63 Long fibular flexor (181).

Character states:- 0= Extends to toe of digit IV, 1= Withdrawn from digit IV

64 Flexor pollicis brevis; deep head (183).

Character states:- 0= Large; 1= Reduced

65 Flexor pollicis longus (184).

Character states:- 0= Present; 1= Reduced; 2= Absent

66 Genioglossal insertion (185).

Character states:- 0= Above inferior transverse torus; 1= Shifted to inferior transverse torus

67 Geniohyoid insertion (186).

Character states:- 0= Basally on inferior transverse torus; 1= Higher on inferior transverse torus; 2= Above inferior transverse torus

68 Insertion of digastric (187).

Character states:- 0= Posterior to inferior transverse torus; 1= Inferior transverse torus; 2= Not on symphysis

69 Extrinsic pedal flexors (188).

Character states:- 0= Small; 1= Increased; 2= Enlarged

70 Relative mass of vasti (189).

Character states:- 0= Small; 1= Increased; 2= Further increased

71 Right lung (190).

Character states:- 0= Four lobes; 1= Fewer than four lobes

72 Laryngeal air sac (191).

Character states:- 0= Small or absent; 1= Enlarged

73 Tuberculum cuneiforme (192).

Character states:- 0= Large; 1= Reduced

74 Caecum (193).

Character states:- 0= Absent or short; 1= Lengthened relative to small intestine; 2= Very long

75 Vermiform appendix (194).

Character states:- 0= Absent or short; 1= Lengthened relative to caecum; 2= Very long

76 Vermiform appendix (195).

Character states:- 0= Spiral; 1= Straightened; 2= Straight

77 Kidney type (196).

Character states:- 0= Type C; 1= Type B; 2= Type E

78 Small intestine (197).

Character states:- 0= Short; 1= Lengthened relative to head and body

79 Valvulae conniventes (198).

Character states:- 0= Absent or develop early; 1= Found in adults only

80 Rectum flexure (199).

Character states:- 0= Absent; 1= Present

81 Parotid gland (200).

Character states:- 0= Postero-ventral to ear; 1= Shifted forward; 2= Shifted well forward

82 Accessory lobes of parotid gland (201).

Character states:- 0= None; 1= Developed

83 Parotid gland (202).

Character states:- 0= Overlies sternomastoid, 1= Freed from sternomastoid

84 Orifice of parotid gland (203).

Character states:- 0= Level with molars; 1= Shifted forwards

85 Foliate papillae (206).

Character states:- 0= On lateral tongue; 1= Shifted to dorsum of tongue

86 Frenulum (207).

Character states:- 0= Absent or poorly developed; 1= Developed

87 Palatine ridges (209).

Character states:- 0= On whole palate; 1= Restricted in extent; 2= Very reduced

88 Ileo-caecal valve (210).

Character states:- 0= Slit-like; 1= Widened, 2= Wide

89 Number of folds of ileocaecal valve (211).

Character states:- 0= One; 1= More than one

90 Tuberculum intervenosum in heart (213).

Character states:- 0= Large; 1= Reduced

91 Anterior papillary muscle of heart (214).

Character states:- 0= Multiple; 1= Reduced

92 Cranial end of heart (215).

Character states:- 0= Level with ribs 2-3; 1= Shifted upward; 2= Shifted further upward

93 Caudal end of heart (216).

Character states:- 0= Level with rib 6; 1= Shifted downward

94 Thoracalis suprema artery (217).



Character states:- 0= Present; 1= Absent

95 Recurrens radialis artery (218).

Character states:- 0= Origin from radial artery; 1= Shifted to brachial artery

96 Recurrens ulnaris artery (219).

Character states:- 0= Split to communis and interossea; 1= Split to anterior and posterior

97 Encephalization (220).

Character states:- 0= Low; 1= Increased; 2= High

98 Palaeocortex index (221).

Character states:- 0= Small; 1= Relatively enlarged; 2= Much enlarged

99 Frontal pole of cerebrum (222).

Character states:- 0= Narrow; 1= Broadened

100 Female receptivity (223).

Character states:- 0= Restricted; 1= Less restricted; 2= Unrestricted

101 Puberty (224).

Character states:- 0= Less than 3 years; 1= 3-5 years; 2= 6-7 years; 3= More than 7 years

102 Ovum (225).

Character states:- 0= Small; 1= Enlarged

103 Mitochondrial coils (226).

Character states:- 0= Many; 1= Reduced in number

104 Testes (227).

Character states:- 0= More than 0.5% body weight; 1= From 0.1 to 0.5%; 2= From 0.05 to 0.%; 3= Less than 0.05%

105 Scrotum (228).

Character states:- 0= Less pendulous; 1= Pendulous

106 Ovaries (230).

Character states:- 0= Small; 1= Enlarged; 2= Very large

107 Uterus (231)

Character states:- 0= Small; 1= Enlarged

108 Corona of glans penis (233).

Character states:- 0= Present; 1= Reduced

109 Baculum (234).

Character states:- 0= Long; 1= Reduced; 2= Tiny or absent

110 Penis; when erect (235).

Character states:- 0= Short; 1= Lengthened

111 Labia minora (236).

Character states:- 0= Small or absent; 1= Developed

112 Oestriol concentration in pregnancy (237).

Character states:- 0= Low level, 1= Raised concentration

113 Pregnanediol concentration in pregnancy (238)

Character states:- 0= Low level; 1= Raised

114 Fluorescent F body (239).

Character states:- 0= None; 1= Present in sperm

115 Oestrus swelling in female (241).

Character states:- 0= Large and prominent; 1= Reduced

116 Plantar pattern intensity (242).

Character states:- 0= Less than palmar; 1= Predominates over palmar

117 Thenar pattern intensity (243).

Character states:- 0= Less than hypothenar on sole; 1= Predominates over hypothenar; 2= Greatly predominates

118 Hypothenar pattern intensity (244).

Character states:- 0= Less than thenar on palm; 1= Predominates over thenar

119 Development of palmar and plantar transverse pattern groups (245).

Character states:- 0= Distal group less than proximal; 1= Distal group predominates

120 Ear breadth (246).

Character states:- 0= More than 75% of height; 1= Less relative to height

121 Ear lobe (247).

Character states:- 0= Absent; 1= Present

122 Upper ear height (248).

Character states:- 0= High; 1= Reduced; 2= Very reduced

123 Apocrine glands (249).

Character states:- 0= Many; 1= Reduced over body surface

124 Eccrine glands (250).

Character states:- 0= Few over body surface; 1= Increased over body surface; 2= Predominate over body surface

125 Axillary organ (251).

Character states:- 0= Absent; 1= Small; 2= Developed

126 Sebaceous glands (253).

Character states:- 0= Large; 1= Reduced in size

127 Hair density on scalp (254).

Character states:- 0= More than 450 per square cm; 1= Reduced; 2= Further reduced

128 Hair density on back (255).

Character states:- 0= More than 450 per square cm; 1= Reduced; 2= Further reduced

129 Hair density on chest (256).

Character states:- 0= More than 100 per square cm; 1= Reduced; 2= Very sparse

130 Sexual dimorphism in body size (257).

Character states:- 0= Male larger than female; 1= Reduced sexual dimorphism

## APPENDIX 4

### DATA MATRIX FOR DATASET B

	1 <sup>iii</sup>	2	3	4	5	6	7	8	9	10	11	12	13	14	15	16	17	18	19	20	21	22
<i>Hylobates</i>	2	2	1	0	0	0	1	0	1	1	1	0	0	0	0	1	2	0	1	0	1	0
<i>Pongo</i>	2	2	1	1	1	0	1	0	1	0	0	1	1	0	1	2	1	1	0	1	0	2
<i>Gorilla</i>	1	2	1	2	1	1	1	1	0	2	0	1	1	1	2	0	0	0	2	1	0	1
<i>Pan</i>	2	3	0	2	2	1	0	1	1	2	0	1	1	1	2	0	0	0	2	1	0	1
<i>Homo</i>	3	3	0	2	2	1	0	1	0	2	1	0	0	1	2	2	0	1	2	0	1	1

	23	24	25	26	27	28	29	30	31	32	33	34	35	36	37	38	39	40	41	42	43	44
<i>Hylobates</i>	0	0	1	1	0	0	1	0	1	0	0	2	1	2	0	2	3	1	2	0	0	0
<i>Pongo</i>	0	1	0	2	1	1	2	0	1	0	0	1	0	2	0	0	3	1	2	0	0	0
<i>Gorilla</i>	0	0	0	2	1	1	2	1	2	1	1	0	1	2	1	1	2	0	1	2	1	0
<i>Pan</i>	1	0	0	2	1	1	1	1	2	1	1	0	0	1	0	1	2	1	2	1	1	1
<i>Homo</i>	1	1	1	1	0	0	1	1	2	1	0	2	0	0	1	2	1	0	1	2	1	1

	45	46	47	48	49	50	51	52	53	54	55	56	57	58	59	60	61	62	63	64	65	66
<i>Hylobates</i>	0	1	0	0	0	1	1	0	0	0	0	0	1	1	0	1	1	0	1	1	0	0
<i>Pongo</i>	0	2	2	0	0	1	2	1	0	1	1	0	1	1	1	1	1	1	0	0	1	1
<i>Gorilla</i>	1	2	2	0	0	0	1	0	1	0	0	1	0	0	0	2	0	0	0	1	2	1
<i>Pan</i>	1	1	1	1	1	0	2	0	1	0	0	1	0	0	0	2	1	0	0	1	2	1
<i>Homo</i>	1	0	0	1	1	0	2	1	0	1	1	0	1	1	1	2	0	2	1	0	0	0

<sup>iii</sup> These numbers refer to characters listed in Appendix 2.

	67	68	69	70	71	72	73	74	75	76	77	78	79	80	81	82	83	84	85	86	87	88
<i>Hylobates</i>	1	0	2	2	0	0	0	0	1	1	0	0	0	0	1	0	0	0	0	0	1	2
<i>Pongo</i>	0	2	2	0	1	1	0	1	2	2	0	0	1	0	2	1	0	1	1	0	1	2
<i>Gorilla</i>	1	0	1	1	0	1	1	0	1	2	1	1	1	1	2	0	1	1	1	1	2	0
<i>Pan</i>	2	1	1	1	1	0	1	1	2	1	0	1	0	0	1	0	1	1	0	1	2	1
<i>Homo</i>	2	1	0	2	1	0	1	0	1	1	2	1	1	1	2	1	1	0	0	1	2	1

	89	90	91	92	93	94	95	96	97	98	99	100	101	102	103	104	105	106	107	108	109	110
<i>Hylobates</i>	1	1	0	2	0	1	0	0	1	2	1	2	2	0	0	0	1	0	0	0	1	0
<i>Pongo</i>	0	0	0	2	0	1	1	0	0	0	0	0	2	?	?	3	0	1	0	1	1	0
<i>Gorilla</i>	1	1	1	0	1	0	0	1	0	1	0	0	2	1	?	3	0	2	1	0	1	0
<i>Pan</i>	0	0	1	1	1	0	1	1	2	1	1	1	3	?	1	1	1	1	1	1	2	1
<i>Homo</i>	1	0	1	1	1	0	0	1	2	2	1	2	3	1	1	2	1	2	1	0	2	1

	111	112	113	114	115	116	117	118	119	120	121	122	123	124	125	126	127	128	129	130
<i>Hylobates</i>	1	0	0	0	0	0	1	1	0	0	0	1	0	0	0	0	0	0	0	1
<i>Pongo</i>	0	1	0	0	0	0	2	0	0	0	1	2	0	1	1	?	2	1	1	0
<i>Gorilla</i>	0	0	1	1	1	1	0	1	1	1	0	1	1	2	2	1	1	2	2	0
<i>Pan</i>	1	0	1	0	1	1	0	0	1	0	0	1	1	2	2	1	2	2	1	1
<i>Homo</i>	1	1	1	1	0	1	2	1	1	1	1	2	1	2	2	0	1	2	2	1

## APPENDIX 5

### INDEX TO ANATOMICAL STRUCTURES

Structure	<i>Homo</i>	<i>Pan</i>	<i>Gorilla</i>	<i>Pongo</i>	<i>Hylobates</i>	Section
<b>ALIMENTARY SYSTEM</b>						
<b>Cavitas oris</b>						
Caruncula sublingualis					*	3.2.4.2
Corpus adiposum buccae		*	*			3.2.4.1
Frenulum labii						
Gingivae						
Labia oris						
Palatum molle	*	*	*	*	*	3.2.4.1.1
Papilla incisiva						
Papilla parotidea						
Philtrum	*	*	*	*		3.2.4.1
Plica palatinae transversae						
Plica sublingualis						
Raphe palati						
Tunica mucosa oris						
Vestibulum oris						
<b>Glandulae oris</b>						
Lingualis anterior	*	*	*	*	*	3.2.4.2
Parotidea	*	*				3.2.4.2
Salivariae minores						
Sublingualis	*	*	*	*	*	3.2.4.2
Submandibularis	*	*	*	*		3.2.4.2
<b>Lingua</b>						
Apex	*	*	*	*	*	3.2.4.3
Aponeurosis linguae						
Corpus	*	*	*	*	*	3.2.4.3
Dorsum	*	*	*	*	*	3.2.4.3
Ductus thyroglossus						
Facies inferior linguae						
Folliculi linguales						
Foramen caecum linguae	*	*	*		*	3.2.4.3
Frenulum						
Papillae linguales	*	*	*	*	*	3.2.4.3.2
Radix						
Septum linguae						
Sulcus medianus linguae						
Sulcus terminalis						
Tonsilla lingualis						
Tunica mucosa linguae						
<b>Fauces</b>						
Fossa supratonsillaris						
Fossa tonsillaris						
Isthmus faucium						
Plica salpingopalatina						
Plica semilunaris						
Plica triangularis						
Tonsilla palatina	*	*	*			3.2.4.4.2
<b>Cavitas pharyngis</b>						
Fascia buccopharyngealis						
Fascia pharyngobasilaris	*			*		3.2.4.4.2
Fornix pharyngis						
Pars laryngea pharyngis						
Pars nasalis pharyngis						

Structure	<i>Homo</i>	<i>Pan</i>	<i>Gorilla</i>	<i>Pongo</i>	<i>Hylobates</i>	Section
Pars oralis pharyngis						
Raphe pharyngis						
Raphe pterygomandibularis						
Recessus piriformis						
Tela submucosa						
Tonsilla pharyngealis	*	*			*	3.2.4.4.2
Tunica mucosa						
Vallecula epiglottica						
<b>Oesophagus</b>						
Pars abdominalis						
Pars cervicalis	*	*		*		3.2.4.5
Pars thoracica	*	*	*	*		3.3.4.1
Tela submucosa						
Tunica adventitia						
Tunica mucosa						
Tunica muscularis						
<b>Gaster</b>	*	*	*	*	*	3.6.4.1.2
Corpus gastricum						
Curvatura gastrica major						
Curvatura gastrica minor						
Fornix gastricus						
Fundus gastricus						
Paries anterior						
Paries posterior						
Pars cardiaca						
Pars pylorica						
Pylorus						
Tela submucosa						
Tela subserosa						
Tunica mucosa						
Tunica muscularis						
Tunica serosa						
<b>Intestinum tenue</b>	*	*	*	*	*	3.6.4.1.3
Tela submucosa						
Tela subserosa						
Tunica mucosa						
Tunica muscularis						
Tunica serosa						
Duodenum	*	*	*	*		3.6.4.1.3.1
Jejunum						
Ileum	*	*	*	*		3.6.4.1.3.2
<b>Intestinum crassum</b>						
Caecum						
Appendix vermiformis	*	*	*	*	*	3.6.4.1.4.1
Frenulum valvae ilealis						
Ostium ileocaecale						
Ostium valvae ilealis						
Papilla ileocaecalis						
Valva ileocaecalis	*	*		*		3.6.4.1.4.1
<b>Colon</b>						
Appendices epiploicae	*	*				3.6.4.1.4
Colon ascendens	*	*	*	*		3.6.4.1.4
Colon descendens	*	*	*	*		3.6.4.1.4
Colon sigmoideum	*	*	*	*		3.6.4.1.4
Colon transversum	*	*	*	*		3.6.4.1.4

Structure	Homo	Pan	Gorilla	Pongo	Hylobates	Section
Flexura coli sinistra						
Haustra coli	*	*	*	*		3.6.4.1.4
Plicae semilunares coli						
Stratum circulare						
Taeniae coli	*	*	*	*	*	3.6.4.1.4
Tunica muscularis						
Rectum	*	*	*			3.6.4.1.5
Ampulla recti						
Flexura perinealis						
Flexura sacralis						
Plicae transversales recti						
Tunica muscularis						
Canalis analis	*	*	*			3.6.4.1.6
Anus						
Columnae analis	*	*	*			3.6.4.1.6
Linea anocutanea						
Linea anorectalis						
Pecten analis						
Sinus anales	*		*			3.6.4.1.6
Valvulae anales	*	*				3.6.4.1.6
<b>Hepar</b>	*	*	*	*		3.6.4.2.1
Arteriae interlobulares						
Ductuli biliferi						
Ductuli interlobulares						
Ductus hepaticus communis						
Ductus hepaticus dexter						
Ductus hepaticus sinister						
Ductus lobi caudati dexter						
Ductus lobi caudati sinister						
Facies diaphragmatica						
Area nuda						
Fissura ligamenti venosi						
Impressio cardiaca						
Ligamentum venosum						
Sulcus venae cavae						
Fascies visceralis						
Fissura ligamenti teretis						
Fossa vesicae biliaris						
Impressio colica						
Impressio duodenalis						
Impressio gastrica						
Impressio oesophageale						
Impressio renalis						
Impressio suprarenalis						
Ligamentum teres hepatis						
Porta hepatis						
Tuber omentale						
Lobi hepatis dexter	*	*	*			3.6.4.2.1
Segmentum anterius						
Segmentum posterius						
Lobi hepatis sinister	*		*			3.6.4.2.1
Lobus caudatus	*	*	*	*		3.6.4.2.1
Lobus quadratus	*	*	*			3.6.4.2.1
Pars quadratus						
Processus caudatus	*	*	*			3.6.4.2.1



Structure	Homo	Pan	Gorilla	Pongo	Hylobates	Section
Processus papillaris						
Segmentum laterale						
Margo inferior						
Incisura ligamenti teretis						
Tela subserosa						
Tunica fibrosa						
Tunica subserosa						
Venae centrales						
Venae interlobulares						
<b>Vesica biliaris</b>	*	*	*			3.6.4.2.2
Ampulla hepatopancreatica						
Collum vesicae biliaris						
Corpus vesicae biliaris						
Ductus choledochus						
Ductus cysticus	*		*			3.6.4.2.2
Fundus vesicae biliaris						
Tela subserosa vesicae biliaris						
Tunica mucosa vesicae biliaris						
Tunica muscularis vesicae biliaris						
Tunica serosa vesicae biliaris						
<b>Pancreas</b>	*	*	*		*	3.6.4.2.3
Caput pancreatis	*	*	*		*	3.6.4.2.3
Incisura pancreatis						
Processus uncinatus						
Cauda pancreatis	*	*	*		*	3.6.4.2.3
Corpus pancreatis						
Ductus pancreaticus	*	*	*	*	*	3.6.4.2.3
Ductus pancreaticus accessorius	*	*			*	3.6.4.2.3
Tuber omentale						
<b>ARTERIES</b>						
Alveolaris inferior	*	*		*		3.2.2.1.1
Alveolares superiores anteriores						
Alveolaris superior posterior	*	*		*		3.2.2.1.1
Aorta	*	*	*	*		3.3.2.2.1
Arcus aortae	*	*	*	*		3.3.2.2.1.2
Ascendens	*	*	*	*		3.3.2.2.1.1
Descendens						
Thoracica	*	*	*	*		3.3.2.2.1.3
Abdominalis	*	*	*	*	*	3.6.2.1.1
Appendicularis						
Arcus palmaris profundus	*	*	*	*	*	3.4.2.1.5
Arcus palmaris superficialis	*	*	*	*	*	3.4.2.1.5
Arcus plantaris profundus	*	*	*	*	*	3.7.2.1.5
Auricularis posterior	*	*		*		3.2.2.1.1
Auricularis profunda						
Axillaris	*	*	*	*	*	3.4.2.1.1
Basilaris	*	*		*	*	3.2.2.1.3
Brachialis	*	*	*	*	*	3.4.2.1.2
Buccalis	*	*		*		3.2.2.1.1
Bulbi penis						
Bulbi vestibulae						
Caecalis anterior						
Caecalis posterior						
Callosomarginalis						
Canalis pterygoidei						
Caroticotympanicae						

Structure	Homo	Pan	Gorilla	Pongo	Hylobates	Section
Carotis communis	*	*	*	*	*	3.3.2.2.1.2
Carotis externa	*	*	*	*		3.2.2.1.1
Carotis interna	*	*		*	*	3.2.2.1.2
Carpalis dorsalis (radialis)	*		*	*		3.4.2.1.3
Carpalis dorsalis (ulnaris)	*	*	*	*	*	3.4.2.1.4
Carpalis palmaris (radialis)	*		*	*	*	3.4.2.1.3
Carpalis palmaris (ulnaris)	*	*		*	*	3.4.2.1.4
Caudae pancreatis						
Centrales anterolaterales						
Centrales anteromediales						
Centrales posterolaterales						
Centrales posteromediales						
Centralis brevis						
Centralis longa						
Centralis retinae						
Cerebri anterior	*	*	*	*	*	3.2.2.1.2
Cerebri media						
Cerebri posterior	*	*		*	*	3.2.2.1.3
Cervicalis ascendens						
Cervicalis profunda						
Choroidea anterior						
Ciliares anteriores						
Ciliares posteriores breves/longae	*			*		3.2.2.1.2
Circulus arteriosus cerebri	*	*		*	*	3.2.2.1.2
Circumflexa anterior/posterior humeri	*	*	*	*	*	3.4.2.1.1
Circumflexa femoris lateralis	*	*	*	*	*	3.7.2.1.1.2
Circumflexa femoris medialis	*	*	*	*	*	3.7.2.1.1.2
Circumflexa iliaca profunda						
Circumflexa iliaca superficialis	*	*	*	*		3.7.2.1.1.1
Circumflexa scapulae						
Colica dextra						
Colica media	*		*			3.6.2.1.1.1.2
Colica sinistra	*	*				3.6.2.1.1.1.3
Collateralis media						
Collateralis radialis						
Collateralis ulnaris inferior	*	*	*	*	*	3.4.2.1.2
Collateralis ulnaris superior	*	*	*	*	*	3.4.2.1.2
Comitans nervi ischiadici						
Comitans nervi mediani						
Communicans anterior	*	*		*	*	3.2.2.1.2
Communicans posterior	*			*		3.2.2.1.2
Conjunctivales anteriores						
Conjunctivales posteriores						
Coronaria dextra	*	*	*	*		3.3.2.2.1.1
Coronaria sinistra	*	*	*	*		3.3.2.2.1.1
Cremasterica						
Cystica	*	*	*		*	3.6.2.1.1.1.1
Descendens genicularis	*	*		*		3.7.2.1.1.2
Digitales dorsales(foot)						
Digitales dorsales(hand)						
Digitales palmares communes	*	*	*	*	*	3.4.2.1.5
Digitales palmares propriae						
Digitales plantares communes						
Digitales plantares propriae						
Dorsalis clitoridis						
Dorsalis nasi	*			*		3.2.2.1.2
Dorsalis pedis	*	*	*	*		3.7.2.1.3

<b>Structure</b>	<b>Homo</b>	<b>Pan</b>	<b>Gorilla</b>	<b>Pongo</b>	<b>Hylobates</b>	<b>Section</b>
Dorsalis penis						
Dorsalis scapulae						
Ductus deferentis						
Epigastrica inferior						
Epigastrica superficialis	*	*	*	*		3.7.2.1.1.1
Epigastrica superior						
Episclerales						
Ethmoidalis anterior						
Ethmoidalis posterior						
Facialis						
Femoralis	*	*	*		*	3.7.2.1.1
Fibularis						
Frontobasalis lateralis						
Frontobasalis medialis						
Gastrica dextra	*	*				3.6.2.1.1.1.1
Gastrica posterior						
Gastrica sinistra	*	*	*			3.6.2.1.1.1.1
Gastricae breves	*	*	*			3.6.2.1.1.1.1
Gastroduodenalis						
Gastro-omentalis dexter	*	*				3.6.2.1.1.1.1
Gastro-omentalis sinistra	*	*				3.6.2.1.1.1.1
Glutea inferior	*	*	*	*		3.6.2.1.2.1
Glutea superior	*	*	*	*		3.6.2.1.2.2
Gyri angularis						
Hepatica communis						
Hepatica propria						
Hypophysialis inferior						
Hypophysialis superior						
Ileales						
Ileocolica						
Iliaca communis						
Iliaca externa						
Iliaca interna	*	*				3.6.2.1.2
Iliolumbalis	*	*	*	*		3.6.2.1.2.2
Inferior anterior cerebelli	*			*		3.2.2.1.3
Inferior lateralis genus						
Inferior medialis genus						
Inferior posterior cerebelli	*			*		3.2.2.1.3
Infraorbitalis	*	*		*		3.2.2.1.1
Insulares						
Intercostales	*	*	*	*		3.3.2.2.1.3
Interossea anterior	*	*	*	*	*	3.4.2.1.4
Interossea communis	*	*	*	*	*	3.4.2.1.4
Interossea posterior	*	*	*	*	*	3.4.2.1.4
Interossea recurrens						
Jejunales						
Labialis inferior	*	*		*		3.2.2.1.1
Labialis superior	*	*		*		3.2.2.1.1
Labyrinthi	*			*		3.2.2.1.3
Lacrimalis	*	*	*	*		3.2.2.1.2
Laryngea inferior						
Laryngea superior	*	*	*			3.2.2.1.1
Ligamenti teretis uteri						
Lingualis	*	*		*		3.2.2.1.1
Lobi caudati						
Lumbales	*	*	*			3.6.2.1.1.3.1

Structure	Homo	Pan	Gorilla	Pongo	Hylobates	Section
Lumbales imae						
Malleolaris anterior lateralis						
Malleolaris anterior medialis						
Masseterica	*			*		3.2.2.1.1
Maxillaris	*	*		*		3.2.2.1.1
Media genus						
Meningea media	*	*	*	*		3.2.2.1.1
Meningea posterior						
Mesencephalicae						
Mesenterica inferior	*	*	*			3.6.2.1.1.1.3
Mesenterica superior	*	*	*			3.6.2.1.1.1.2
Metacarpales dorsales						
Metacarpales palmares	*	*	*	*	*	3.4.2.1.5
Metatarsales dorsales						
Metatarsales plantares	*	*	*		*	3.7.2.1.5
Musculophrenica	*	*				3.3.2.2.1.2
Nasales posteriores laterales						
Nutriciae femoris						
Nutriciae fibulae						
Nutriciae humeri						
Nutriciae tibiae						
Obturatoria	*	*	*	*		3.6.2.1.2.1
Occipitalis	*	*		*		3.2.2.1.1
Occipitalis lateralis						
Occipitalis medialis						
Ophthalmica	*	*		*		3.2.2.1.2
Ovarica	*	*				3.6.2.1.1.2.3
Palatina ascendens						
Palatina descendens	*	*		*		3.2.2.1.1
Palatina major						
Palatinae minores						
Palmaris profundus	*	*	*	*	*	3.4.2.1.4
Palmaris superficialis	*	*	*	*	*	3.4.2.1.3
Palpebrales laterales						
Palpebrales mediales						
Pancreatica dorsalis/inferior/magna	*	*				3.6.2.1.1.1.1
Pancreaticoduodenalis inferior						
Pancreaticoduodenalis superior anterior						
Pancreaticoduodenalis superior posterior						
Paracentralis						
Parietales anterior et posterior						
Parieto-occipitalis						
Pericardiacophrenica						
Perinealis						
Peronealis	*	*	*	*	*	3.7.2.1.4
Pharyngea ascendens	*	*		*		3.2.2.1.1
Phrenica inferior	*	*		*		3.6.2.1.1.2.1
Phrenicae superiores						
Plantaris lateralis	*	*	*	*	*	3.7.2.1.4
Plantaris medialis	*	*	*	*	*	3.7.2.1.4
Plantaris profundus						
Pontis	*			*		3.2.2.1.3
Poplitea	*	*	*	*	*	3.7.2.1.2
Precunealis						
Princeps pollicis	*	*	*	*	*	3.4.2.1.3

<b>Structure</b>	<b>Homo</b>	<b>Pan</b>	<b>Gorilla</b>	<b>Pongo</b>	<b>Hylobates</b>	<b>Section</b>
Profunda brachii	*	*	*	*	*	3.4.2.1.2
Profunda clitoridis						
Profunda femoris	*	*	*	*	*	3.7.2.1.1.2
Profunda linguae						
Profunda penis						
Pterygomeningea						
Pudenda externa	*	*	*	*		3.7.2.1.1.2
Pudenda interna	*	*	*	*		3.6.2.1.2.1
Pulmonalis dextra	*	*		*	*	3.3.2.2.2
Pulmonalis sinistra	*	*		*	*	3.3.2.2.2
Radialis	*	*	*	*	*	3.4.2.1.3
Radialis indicis	*	*	*	*	*	3.4.2.1.3
Rectalis inferior						
Rectalis media	*	*				3.6.2.1.2.1
Rectalis superior	*	*				3.6.2.1.1.1.3
Recurrans radialis	*	*	*	*	*	3.4.2.1.3
Recurrans tibialis anterior						
Recurrans tibialis posterior						
Recurrans ulnaris	*	*	*	*	*	3.4.2.1.4
Renalis	*	*	*			3.6.2.1.1.2.2
Rete articulare cubitii						
Rete articulare genus						
Rete malleolare laterale						
Rete patellae						
Retroduodenales						
Sacrales laterales	*	*				3.6.2.1.2.2
Sacralis mediana	*	*		*		3.6.2.1.1.3.2
Saphena	*	*	*	*	*	3.7.2.1.1.2
Segmenti anterioris						
Segmenti anterioris superioris						
Segmenti anterioris inferioris						
Segmenti lateralis						
Segmenti medialis						
Segmenti posterioris						
Segmenti superioris						
Sigmoideae						
Sphenopalatina	*	*		*		3.2.2.1.1
Spinalis anterior	*			*		3.2.2.1.3
Spinalis posterior						
Splenica	*	*	*	*		3.6.2.1.1.1.1
Stylomastoidea						
Subclavia	*	*	*	*		3.3.2.2.1.2
Subcostalis	*	*		*		3.3.2.2.1.3
Sublingualis						
Submentalis	*	*				3.2.2.1.1
Subscapularis	*	*	*	*	*	3.5.2.1.2
Sulci centralis						
Sulci postcentralis						
Sulci precentralis						
Superior cerebelli	*			*		3.2.2.1.3
Superior lateralis genus						
Superior medialis genus						
Suprarenalis inferior	*	*	*			3.6.2.1.1.2.2
Suprarenalis media	*	*	*	*		3.6.2.1.1.2.1
Suprarenales superiores						
Suprascapularis	*	*	*	*		3.5.2.1.1

Structure	Homo	Pan	Gorilla	Pongo	Hylobates	Section
Supratrochlearis						
Surales						
Tarsalis lateralis						
Tarsalis medialis						
Temporalis anterior						
Temporalis media						
Temporalis posterior						
Temporalis profunda anterior/posterior	*	*		*		3.2.2.1.1
Temporalis superficialis	*	*		*		3.2.2.1.1
Testicularis	*	*			*	3.6.2.1.1.2.3
Thoracica interna	*	*	*			3.3.2.2.1.2
Thoracica lateralis	*	*	*	*	*	3.3.2.2.3
Thoracica superior	*	*	*	*	*	3.3.2.2.3
Thoracoacromialis	*	*	*	*	*	3.3.2.2.3
Thoracodorsalis						
Thyrocerivicalis						
Thyroidea inferior						
Thyroidea superior	*	*	*	*		3.2.2.1.1
Tibialis anterior	*	*	*	*		3.7.2.1.3
Tibialis posterior	*	*	*	*	*	3.7.2.1.4
Transversa cervicis	*	*		*		3.5.2.1.1
Transversa facialis	*	*		*		3.2.2.1.1
Truncus brachiocephalicus	*	*	*	*		3.3.2.2.1.2
Truncus coeliacus	*	*	*			3.6.2.1.1.1.1
Truncus costocervicalis						
Truncus pulmonalis						
Tympanica anterior						
Tympanica inferior						
Tympanica posterior						
Tympanica superior						
Ulnaris	*	*	*	*	*	3.4.2.1.4
Umbilicalis						
Urethralis						
Uterina	*	*	*	*		3.6.2.1.2.1
Vaginalis	*	*		*		3.6.2.1.2.1
Vertebralis	*	*	*	*	*	3.2.2.1.3
Vesicales inferior/superiores	*	*	*	*		3.6.2.1.2.1
Zygomatic-orbitalis						

#### BURSAE

Bicipitoradialis
Infrahyoidea
Infrapatellaris profunda
Intermusculares musculorum gluteorum
Ischiadica musculi glutei maximi
Ischiadica musculi obturatoris interni
Musculi bicipitis femoris superior
Musculi piriformis
Musculi semimembranosi
Musculi tensoris veli palatini
Retrohyoidea
Subacromialis
Subcutanea infrapatellaris
Subcutanea malleoli lateralis
Subcutanea malleoli medialis
Subcutanea olecrani

<b>Structure</b>	<b>Homo</b>	<b>Pan</b>	<b>Gorilla</b>	<b>Pongo</b>	<b>Hylobates</b>	<b>Section</b>
Subcutanea prepatellaris						
Subcutanea prominentiae laryngealis						
Subcutanea trochanterica						
Subcutanea tuberositatis tibiae						
Subdeltoidea						
Subtendinea calcanea						
Subtendinea iliaca						
Subtendinea musculi gastrocnemius lateralis						
Subtendinea musculi gastrocnemius medialis						
Subtendinea musculi infraspinatus						
Subtendinea musculi latissimus dorsi						
Subtendinea musculi obturatoris interna						
Subtendinea musculi subscapularis						
Subtendinea musculi teretis majoris						
Subtendinea musculi trapezii						
Subtendinea musculi tricipitis brachii						
Subtendinea prepatellaris						
Suprapatellaris						
Tendinis calcanei						
Trochanterica musculi glutei maximi						
Trochanterica musculi glutei medii						
Trochanterica musculi glutei minimi						

<b>COR</b>						
Annuli fibrosi						3.3.2.1
Apex cordis	*	*	*	*	*	3.3.2.1
Atrium dextrum	*	*		*		3.3.2.1.2.2
Auricula dextra	*			*		3.3.2.1.2.2
Crista terminalis	*	*		*		3.3.2.1.2.2
Foramina venarum minimarum						
Fossa ovalis	*	*		*		3.3.2.1.2.2
Limbus fossae ovalis						
Musculi pectinati	*	*		*		3.3.2.1.2.2
Ostium sinus coronarii						
Ostium venae cavae inferioris	*	*		*		3.3.2.1.2.2
Ostium venae cavae superioris						
Sinus venarum cavarum						
Sulcus terminalis						
Tuberculum intervenosum						
Valvula venae cavae inferioris	*	*		*		3.3.2.1.2.2
Valvula sinus coronarii	*			*		3.3.2.1.2.2
Atrium sinistrum	*	*		*		3.3.2.1.2.1
Auricula sinistra	*	*		*		3.3.2.1.2.1
Musculi pectinati	*	*		*		3.3.2.1.2.1
Ostia venarum pulmonalium						
Valvula foraminis ovalis						
Endocardium						
Myocardium						
Septum atrioventriculare						
Septum interatriale						
Septum interventriculare						
Sulcus coronarius						
Sulcus interventricularis anterior						

Structure	Homo	Pan	Gorilla	Pongo	Hylobates	Section
Sulcus interventricularis posterior						
Tendo infundibulum						
Trigonum fibrosum dextrum						
Trigonum fibrosum sinistrum						
Ventriculus dexter	*	*		*		3.3.2.1.3.2
Conus arteriosus	*	*		*		3.3.2.1.3.2
Crista supraventricularis	*	*		*		3.3.2.1.3.2
Musculus papillaris anterior						
Musculus papillaris posterior						
Ostium atrioventriculare dextrum	*	*		*		3.3.2.1.3.2
Ostium trunci pulmonalis						
Trabecula septomarginalis	*	*				3.3.2.1.3.2
Trabeculae carnae						
Valva atrioventricularis dextra	*	*		*		3.3.2.1.3.2
Valva trunci pulmonalis	*	*				3.3.2.1.3.2
Ventriculus sinister	*	*		*		3.3.2.1.3.1
Musculus papillaris anterior						
Musculus papillaris posterior						
Ostium aortae						
Ostium atrioventriculare sinistrum	*			*		3.3.2.1.3.1
Trabeculae carnae	*	*				3.3.2.1.3.1
Valva aortae						
Vortex cordis						
<b>ENDOCRINE GLANDS</b>						
Corpus pineale	*	*	*	*		3.2.6.2
Glandula parathyroidea inferior/superior	*	*	*			3.2.6.1
Glandula suprarenalis	*	*	*			3.6.6.1
Cortex						
Facies anterior						
Facies posterior						
Facies renalis						
Hilum						
Margo medialis						
Margo superior						
Medulla						
Glandula thyroidea	*	*	*	*		3.2.6.4
Hypophysis	*	*	*	*	*	3.2.6.3
Thymus	*	*	*	*		3.3.6.1
<b>INTEGUMENT</b>						
Cornu						
Dermis						
Epidermis						
Glandulae cutis						
Glandula mammaria						
Mamma						
Pilus						
Tela subcutanea						
Unguis						
<b>LYMPHATICS</b>						
Ductus						
Cisterna chyli						
Ductus lymphaticus dexter						



Structure	Homo	Pan	Gorilla	Pongo	Hylobates	Section
Ductus thoracicus						
Pars thoracica	*	*	*			3.3.2.4
Pars abdominalis	*	*		*		3.6.2.3
<b>Nodes</b>						
Aortici laterales						
Appendiculares						
Axillaris	*	*		*		3.4.2.3
Buccinatorius						
Cavales laterales						
Cervicales anteriores superficiales/profundi	*	*	*	*		3.2.2.3
Cervicales laterales superficiales/profundi	*	*	*	*		3.2.2.3
Coeliaci						
Colici						
Epigastrici inferiores						
Gastrici	*	*				3.6.2.3
Gastro-ommentales						
Gluteales						
Hepatici						
Ileocolici						
Iliaci communes	*	*				3.6.2.3
Iliaci externi	*		*			3.6.2.3
Iliaci interni						
Infra-auriculares						
Inguinales	*	*				3.6.2.3
Intercostales						
Interiliaci						
Intraglandulares						
Jugulares anteriores						
Jugulares laterales						
Jugulodigastricus						
Jugulo-omohyoideus						
Juxta-esophageales pulmonales						
Lumbales dextri						
Lumbales intermedii						
Lumbales sinistri						
Malaris						
Mandibularis						
Mastoidei						
Mediastinales anteriores						
Mediastinales posteriores	*		*			3.3.2.4
Mesenterici	*	*				3.6.2.3
Mesocolici						
Nasolabialis						
Obturatorii						
Occipitales	*	*		*		3.2.2.3
Pancreatici						
Pancreaticoduodenales						
Paramammarii						
Paracolici						
Pararectales						
Parasternales						
Paratracheales						
Para-uterini						
Paravaginalis						

Structure	Homo	Pan	Gorilla	Pongo	Hylobates	Section
Paravesiculares						
Parotidei superficialis/profundi	*	*	*	*		3.2.2.3
Phrenici inferiores						
Phrenici superiores						
Popliteales	*	*	*	*		3.7.2.3
Postaortici						
Postcavales						
Postvesiculares						
Pre-aortici						
Preauriculares						
Precaecales						
Precavales						
Prelaryngeales	*	*		*		3.2.2.3
Prepericardiales laterales						
Pretracheales	*		*			3.2.2.3
Prevertebrales						
Prevesiculares						
Promontorii						
Pylorici						
Rectales superiores						
Retrocaecales						
Retropharyngeales	*	*		*		3.2.2.3
Sacrales						
Sigmoidei						
Splenici						
Subaortici						
Submandibulares						
Submentalis	*	*		*		3.2.2.3
Supraclaviculares						
Thyroidei						
Tracheobronchiales						
Vesicales laterales						
<b>Splen</b>	*	*	*	*		3.6.4.2.3
Extremitas anterior						
Extremitas posterior						
Facies diaphragmatica						
Facies visceralis						
Folliculi lymphatici splenici						
Hilum splenicum						
Margo inferior						
Margo superior						
Penicilli						
Pulpa splenica						
Rami splenici						
Sinus splenicus						
Splen accessorius	*	*		*		3.6.4.2.3
Trabeculae splenicae						
Tunica fibrosa						
Tunica serosa						
<b>Trunks</b>						
Bronchomediastinales dexter/sinister						
Intestinales						
Jugularis dexter/sinister						
Lumbaris dexter/sinister						
Subclavius dexter/sinister						

Structure	Homo	Pan	Gorilla	Pongo	Hylobates	Section
<b>MUSCLES</b>						
Abductor digiti minimi(foot)	*	*	*	*	*	3.7.1.4.2.1
Abductor digiti minimi(hand)	*	*	*	*	*	3.4.1.4.1
Abductor hallucis	*	*	*	*	*	3.7.1.4.2.1
Abductor os metatarsi digiti minimi*	*	*	*	*		3.7.1.4.2.1
Abductor pollicis brevis	*	*	*	*	*	3.4.1.4.2
Abductor pollicis longus	*	*	*	*	*	3.4.2.3.2.2
Adductor brevis	*	*	*	*	*	3.7.1.2.2
Adductor hallucis	*	*	*	*	*	3.7.1.4.2.3
Adductor longus	*	*	*	*	*	3.7.1.2.2
Adductor magnus	*	*	*	*	*	3.7.1.2.2
Adductor minimus	*	*	*	*	*	3.7.1.2.2
Adductor pollicis						
Anconeus	*	*	*	*	*	3.4.1.2.2
Antitragicus						
Arrectores pilorum						
Articularis genu	*	*	*	*	*	3.7.1.2.1
Aryepiglotticus	*	*				3.2.5.2.1
Arytenoideus obliquus/transversus	*	*	*	*		3.2.5.2.1
Auriculares	*	*	*	*		3.2.7.1.2.1
Biceps brachii	*	*	*	*	*	3.4.1.2.1
Biceps femoris	*	*	*	*	*	3.7.1.2.3
Brachialis	*	*	*	*	*	3.4.1.2.1
Brachioradialis	*	*	*	*	*	3.4.1.3.2.1
Bronchooesophageus						
Buccinator	*	*	*	*		3.2.1.2.4
Bulbospongiosus	*	*	*	*	*	3.6.1.3.2.2
Chondroglossus						
Coccygeus	*	*	*	*	*	3.6.1.3.1
Compressor urethrae						
Constrictor pharyngis inferior	*	*				3.2.4.4.1
Constrictor pharyngis medius	*	*				3.2.4.4.1
Constrictor pharyngis superior	*	*	*	*		3.2.4.4.1
Coracobrachialis	*	*	*	*	*	3.4.1.2.1
Corrugator supercilii	*	*	*	*		3.2.1.2.2
Cremaster	*	*	*	*	*	3.6.1.1.2
Cricoarytenoideus lateralis	*	*		*		3.2.5.2.1.
Cricoarytenoideus posterior	*	*		*		3.2.5.2.1
Cricothyroideus	*	*	*	*	*	3.2.5.2.1
Dartos						
Deltoid	*	*	*	*	*	3.4.1.1
Depressor anguli oris	*	*	*	*		3.2.1.2.4
Depressor labii inferioris	*	*	*	*		3.2.1.2.4
Depressor septi						
Depressor supercilii	*	*	*	*		3.2.1.2.2
Detrusor vesicae						
Diaphragm	*	*	*		*	3.2.1.3
Digastric	*	*	*	*	*	3.2.1.4.3
Dilator pupillae						
Dorso-epitrochlearis	*	*	*	*	*	3.4.1.2.2
Extensor carpi radialis brevis	*	*	*	*	*	3.4.1.3.2.1
Extensor carpi radialis longus	*	*	*	*	*	3.4.1.3.2.1
Extensor carpi ulnaris	*	*	*	*	*	3.4.1.3.2.1
Extensor digiti minimi	*	*	*	*	*	3.4.1.3.2.1
Extensor digitorum	*	*	*	*	*	3.4.1.3.2.1
Extensor digitorum brevis	*	*	*	*	*	3.7.1.4.1

Structure	Homo	Pan	Gorilla	Pongo	Hylobates	Section
Extensor digitorum longus	*	*	*	*	*	3.7.1.3.1
Extensor hallucis brevis	*	*	*	*	*	3.7.1.4.1
Extensor hallucis longus	*	*	*	*	*	3.7.1.3.1
Extensor indicis	*	*	*	*	*	3.4.1.3.2.2
Extensor pollicis brevis	*	*	*	*	*	3.4.1.3.2.2
Extensor pollicis longus	*	*	*	*	*	3.4.1.3.2.2
Flexor carpi radialis	*	*	*	*	*	3.4.1.3.1.1
Flexor carpi ulnaris	*	*	*	*	*	3.4.1.3.1.1
Flexor digiti minimi(foot)	*	*	*	*	*	3.7.1.4.2.3
Flexor digiti minimi brevis	*	*	*	*	*	3.4.1.4.1
Flexor digitorum brevis	*	*	*	*	*	3.7.1.4.2.1
Flexor digitorum longus	*	*	*	*	*	3.7.1.3.3.2
Flexor digitorum profundus	*	*	*	*	*	3.4.1.3.1.2
Flexor digitorum superficialis	*	*	*	*	*	3.4.1.3.1.1
Flexor hallucis brevis	*	*	*	*	*	3.7.1.4.2.3
Flexor hallucis longus	*	*	*	*	*	3.7.1.3.3.2
Flexor pollicis brevis	*	*	*	*	*	3.4.1.4.2
Flexor pollicis longus	*	*	*	*	*	3.4.1.3.1.2
Galea aponeurotica						
Gastrocnemius	*	*	*	*	*	3.7.1.3.3.1
Gemellus inferior	*	*	*	*	*	3.7.1.1.2
Gemellus superior	*	*	*	*	*	3.7.1.1.2
Genioglossus	*	*				3.2.4.3.1
Geniohyoideus	*	*	*			3.2.1.4.3
Gluteus maximus	*	*	*	*	*	3.7.1.1.1
Gluteus medius	*	*	*	*	*	3.7.1.1.1
Gluteus minimus	*	*	*	*	*	3.7.1.1.1
Gracilis	*	*	*	*	*	3.7.1.2.2
Helicis major						
Helicis minor						
Hyoglossus	*	*		*		3.2.4.3.1
Iliococcygeus	*	*	*	*	*	3.6.1.3.1
Iliocostalis	*	*	*	*	*	3.5.1.2.1.1
Infraspinatus	*	*	*	*	*	3.5.1.1.5
Inguinal canal	*	*	*	*	*	3.6.1.1.3
Intercostales externi	*	*	*			3.3.1.2
Intercostales interni						
Intercostales intimi						
Interossei dorsales(hand)	*	*	*	*	*	3.4.1.4.3
Interossei palmares	*	*	*	*	*	3.4.1.4.3
Interossei dorsales(foot)	*	*	*	*	*	3.7.1.4.2.4
Interossei plantares	*	*	*	*	*	3.7.1.4.2.4
Interspinales	*		*			3.5.1.2.2.2
Intertransversarii	*	*	*	*		3.5.1.2.2.3
Ischiocavernosus	*	*	*			3.6.1.3.2.2
Latissimus dorsi	*	*	*	*	*	3.5.1.1.4
Levator anguli oris	*	*	*	*		3.2.1.2.4
Levator ani	*	*	*	*		3.6.1.3.1
Levator claviculae	*	*	*	*		3.2.1.4.2
Levatores costarum	*	*	*			3.3.1.1
Levator labii superioris	*	*	*	*		3.2.1.2.4
Levator labii superioris alaeque nasi	*	*	*	*		3.2.1.2.4
Levator palpebrae superioris	*	*		*		3.2.7.2.2.1
Levator prostatae[pubovaginalis]						
Levator scapulae	*	*	*	*		3.5.1.1.4
Levator veli palatini	*	*	*	*		3.2.4.1.1

Structure	Homo	Pan	Gorilla	Pongo	Hylobates	Section
Longissimus	*	*	*	*		3.5.1.2.1.2
Longitudinalis inferior						
Longitudinalis superior						
Longus capitis	*	*	*	*		3.2.1.4.1
Longus colli	*	*	*	*		3.2.1.4.1
Lumbricales(foot)	*	*	*	*	*	3.7.1.4.2.2
Lumbricales(hand)	*	*	*	*	*	3.4.1.4.3
Masseter	*	*	*	*	*	3.2.1.3
Mentalis	*	*	*	*		3.2.1.2.4
Multifidus	*	*	*			3.5.1.2.2.1
Mylohyoideus	*	*	*	*		3.2.1.4.3
Nasalis	*	*	*	*		3.2.1.2.3
Obliquus auriculae						
Obliquus capitis inferior	*	*	*	*		3.2.1.1
Obliquus capitis superior	*	*	*			3.2.1.1
Obliquus externus abdominis	*	*	*	*	*	3.6.1.1.2
Obliquus inferior	*	*		*		3.2.7.2.2.1
Obliquus internus abdominis	*	*	*	*	*	3.6.1.1.2
Obliquus superior	*	*		*		3.2.7.2.2.1
Obturator externus	*	*	*	*	*	3.7.1.1.2
Obturator internus	*	*	*	*	*	3.7.1.1.2
Occipitofrontalis	*	*	*	*		3.2.1.2.1
Omohyoideus	*	*	*	*	*	3.2.1.4.4
Opponens digiti minimi(foot)	*	*	*	*		3.7.1.4.2.3
Opponens digiti minimi(hand)	*	*	*	*	*	3.4.1.4.1
Opponens hallucis*	*	*	*	*	*	3.7.1.4.2.3
Opponens pollicis	*	*	*	*	*	3.4.1.4.2
Orbicularis oculi	*	*	*	*		3.2.1.2.2
Orbicularis oris	*	*	*	*		3.2.1.2.4
Orbitalis						
Palatoglossus	*	*				3.2.4.1.1
Palatopharyngeus						
Palmaris brevis	*	*	*	*	*	3.4.1.4.1
Palmaris longus	*	*	*	*	*	3.4.1.3.1.1
Pectineus	*	*	*	*	*	3.7.1.2.2
Pectoralis major	*	*	*	*	*	3.3.1.1
Pectoralis minor	*	*	*	*	*	3.3.1.1
Peroneus brevis	*	*	*	*	*	3.7.1.3.2
Peroneus longus	*	*	*	*	*	3.7.1.3.2
Peroneus tertius	*	*	*	*	*	3.7.1.3.1
Piriformis	*	*	*	*	*	3.7.1.1.2
Plantaris	*	*	*	*	*	3.7.1.3.3.1
Platysma	*	*	*	*		3.2.1.4.2
Pleurooesophageus						
Popliteus	*	*	*	*	*	3.7.1.3.3.2
Procerus	*	*	*			3.2.1.2.3
Pronator quadratus	*	*	*	*	*	3.4.1.3.1.2
Pronator teres	*	*	*	*	*	3.4.1.3.1.1
Psoas major	*	*	*	*	*	3.6.1.2
Psoas minor	*	*	*	*	*	3.6.1.2
Pterygoideus lateralis	*		*	*		3.2.1.3
Pterygoideus medialis	*		*	*		3.2.1.3
Pubococcygeus	*	*	*	*	*	3.6.1.3.1
Puboprostaticus	*		*			3.6.1.3.1
Puborectalis	*	*	*	*		3.6.1.3.1
Pubovaginalis						

Structure	Homo	Pan	Gorilla	Pongo	Hylobates	Section
Pubovesicalis	*		*			3.6.1.3.1
Pyramidalis	*	*	*			3.6.1.1.1
Pyramidalis auriculae						
Quadratus femoris	*	*	*	*	*	3.7.1.1.2
Quadratus lumborum	*	*	*			3.6.1.2
Quadratus plantae	*	*	*	*	*	3.7.1.4.2.2
Quadriceps femoris	*	*	*	*	*	3.7.1.2.1
Rectococcygeus	*		*			3.6.4.1.5
Rectourethralis	*		*			3.6.4.1.5
Rectouterinus						
Rectovesicalis						
Rectus abdominis	*	*	*		*	3.6.1.1.1
Rectus capitis anterior	*	*	*	*		3.2.1.1
Rectus capitis lateralis	*	*	*	*		3.2.1.1
Rectus capitis posterior major	*	*	*	*		3.2.1.1
Rectus capitis posterior minor	*	*	*	*		3.2.1.1
Rectus femoris	*	*	*	*	*	3.7.1.2.1
Rectus inferior	*	*		*		3.2.7.2.2.1
Rectus lateralis	*	*		*		3.2.7.2.2.1
Rectus medialis						
Rectus superior	*			*		3.2.7.2.2.1
Rhomboideus major and minor	*	*	*	*		3.5.1.1.4
Risorius	*	*	*	*		3.2.1.2.4
Rotatores	*	*	*			3.5.1.2.2.1
Salpingopharyngeus						
Sartorius	*	*	*	*	*	3.7.1.2.1
Scalenus anterior	*	*	*	*	*	3.2.1.4.1
Scalenus medius	*	*	*	*		3.2.1.4.1
Scalenus minimus						
Scalenus posterior	*	*	*	*		3.2.1.4.1
Scansorius*	*	*	*	*	*	3.7.1.1.1
Semimembranosus	*	*	*	*	*	3.7.1.2.3
Semispinalis	*	*	*	*		3.5.1.2.2.1
Semitendinosus	*	*	*	*	*	3.7.1.2.3
Serratus anterior	*	*	*	*	*	3.3.1.1
Serratus posterior inferior	*	*	*	*		3.5.1.1.3
Serratus posterior superior	*	*	*	*		3.5.1.1.2
Soleus	*	*	*	*	*	3.7.1.3.3.1
Sphincter ani externus	*	*	*	*	*	3.6.1.3.2.1
Sphincter ani internus						
Sphincter ductus choledochi						
Sphincter ductus pancreatici						
Sphincter pupillae						
Sphincter pyloricus						
Sphincter urethrae	*		*			3.6.1.3.2.2
Spinalis	*	*	*			3.5.1.2.1.3
Splenius capitis	*	*	*	*		3.5.1.1.1
Splenius cervicis	*	*	*	*		
Stapedius						
Sternalis	*	*		*		3.3.1.1
Sternocleidomastoideus	*	*	*	*	*	3.2.1.4.2
Sternohyoideus	*	*	*	*		3.2.1.4.4
Sternothyroideus	*	*	*			3.2.1.4.4
Styloglossus	*	*	*	*		3.2.4.2.1
Stylohyoideus	*	*	*	*		3.2.1.4.3
Stylopharyngeus	*	*		*		3.2.4.4.1

Structure	Homo	Pan	Gorilla	Pongo	Hylobates	Section
Subclavius	*	*	*	*	*	3.3.1.1
Subcostales						
Subscapularis	*	*	*	*	*	3.5.1.1.5
Supinator	*	*	*	*	*	3.4.1.3.2.2
Supraspinatus	*	*	*	*	*	3.5.1.1.5
Suspensorius duodeni						
Tarsalis inferior						
Tarsalis superior						
Temporalis	*	*	*	*		3.2.1.3
Temporoparietalis	*	*				3.2.1.2.1
Tendo calcanei						
Tensor fasciae latae	*	*	*	*	*	3.7.1.2.1
Tensor linea semilunaris			*			3.6.1.1.1
Tensor tympani						
Tensor veli palatini	*	*	*	*		3.2.4.1.1
Teres major	*	*	*	*	*	3.5.1.1.5
Teres minor	*	*	*	*	*	3.5.1.1.5
Thyroarytenoideus	*	*		*		3.2.5.2.1
Thyroepiglotticus	*	*				3.2.5.2.1
Thyrohyoideus	*	*	*	*		3.2.1.4.4
Tibialis anterior	*	*	*	*	*	3.7.1.3.1
Tibialis posterior	*	*	*	*	*	3.7.1.3.3.2
Thyrohyoideus						
Tracheales						
Tragicus	*	*		*		3.2.7.1.2.1
Transversus abdominis	*	*	*	*	*	3.6.1.1.2
Transversus auriculae						
Transversus linguae						
Transversus perinei profundus	*	*	*			3.6.1.3.2.2
Transversus perinei superficialis	*	*	*			3.6.1.3.2.2
Transversus menti						
Transversus thoracis	*	*	*			3.3.1.2
Trapezius	*	*	*	*	*	3.5.1.1.4
Triceps brachii	*	*	*	*	*	3.4.1.2.2
Uvulae	*	*		*		3.2.4.1
Vasti	*	*	*	*	*	3.7.1.2.1
Verticalis linguae						
Vocalis	*	*				3.2.5.2.1
Zygomaticus major	*	*	*	*		3.2.1.2.4
Zygomaticus minor	*	*	*	*		3.2.1.2.4

## MEDIASTINUM

### NERVES

Abducens(VI)	*	*				3.2.3.1
Accessorius(XI)	*	*	*			3.2.3.1
Alveolares superiores						
Alveolaris inferior						
Ampullaris anterior						
Ampullaris lateralis						
Ampullaris magnus						
Ampullaris posterior						
Auriculares anteriores						
Auricularis magnus	*		*			3.2.3.2
Auricularis posterior	*			*		3.2.3.1
Auriculotemporalis						

Structure	Homo	Pan	Gorilla	Pongo	Hylobates	Section
Autonomica						
Plexus aorticus abdominalis						
Plexus aorticus thoracicus						
Plexus hypogastricus superior						
Axillaris	*	*	*	*	*	3.4.3.3.2.7
Buccalis						
Canalis pterygoidei						
Caroticotympanici						
Cervicales						
Chorda tympani	*	*		*		3.2.3.1
Ciliares breves	*	*				3.2.3.1
Ciliares longi						
Clunium inferiores						
Clunium medii						
Cochlearis						
Cutanei cruris mediales						
Cutaneous antebrachii lateralis	*	*	*	*	*	3.4.3.3.2.2
Cutaneous antebrachii medialis	*	*	*	*	*	3.4.3.3.2.3
Cutaneous antebrachii posterior						
Cutaneous brachii lateralis inferior						
Cutaneous brachii lateralis superior						
Cutaneous brachii medialis	*	*	*	*	*	3.4.3.3.2.3
Cutaneous brachii posterior						
Cutaneous dorsalis intermedius						
Cutaneous dorsalis lateralis						
Cutaneous dorsalis medialis						
Cutaneous femoris lateralis	*	*	*	*	*	3.7.3.2.3
Cutaneous femoris posterior	*	*	*	*	*	3.7.3.2.8
Cutaneous surae lateralis						
Cutaneous surae medialis						
Digitales dorsales manus						
Digitales dorsales pedis						
Digitales palmares communes/proprii	*	*	*	*	*	3.4.3.3.2.4-5
Digitales plantares communes						
Digitales plantares proprii						
Dorsalis clitoridis						
Dorsalis penis						
Dorsalis scapulae	*		*			3.4.3.3.1
Ethmoidalis anterior						
Ethmoidalis posterior						
Facialis(VII)	*	*		*		3.2.3.1
Femoralis	*	*	*	*	*	3.7.3.2.4
Fibularis communis[peroneus]	*	*	*	*	*	3.7.3.2.9.2
Fibularis profundus	*	*	*	*		3.7.3.2.9.2.1
Fibularis superficialis	*	*	*	*	*	3.7.3.2.9.2.2
Frontalis						
Ganglion caudalis						
Ganglion ciliare	*	*		*		3.2.3.1
Ganglion cochleare						
Ganglion geniculi						
Ganglion oticum						
Ganglion pterygopalatinum	*			*		3.2.3.1
Ganglion rostralis						
Ganglion submandibulare						
Ganglion trigeminale	*			*		3.2.3.1
Ganglion vestibulare						



Structure	Homo	Pan	Gorilla	Pongo	Hylobates	Section
Geniofemoralis	*	*	*	*	*	3.6.3.2
Glossopharyngeus(IX)	*	*				3.2.3.1
Gluteus inferior	*	*		*		3.7.3.2.7
Gluteus superior	*	*	*	*	*	3.7.3.2.6
Hypoglossus(XII)	*	*	*	*		3.2.3.1
Iliohypogastricus	*	*	*			3.6.3.2
Ilio-inguinalis	*	*	*		*	3.6.3.2
Infraorbitalis	*	*				3.2.3.1
Infratrochlearis						
Intercostales	*	*	*			3.3.3.1
Intercostobrachialis	*	*	*	*	*	3.4.3.2
Intermedius						
Interosseous anterior	*	*	*	*	*	3.4.3.3.2.4
Interosseous cruris						
Interosseous posterior	*	*	*	*	*	3.4.3.3.2.6
Ischiadicus[sciatic]	*	*	*	*	*	3.7.3.2.9
Labiales anteriores						
Labiales posteriores						
Lacrimalis						
Laryngeus inferior	*	*				3.2.3.1
Laryngeus recurrens						
Laryngeus superior	*	*				3.2.3.1
Lingualis	*	*				3.2.3.1
Lumbales						
Mandibularis	*			*		3.2.3.1
Massetericus						
Maxillaris	*	*		*		3.2.3.1
Meatus acustici externi						
Medianus	*	*	*	*	*	3.4.3.3.2.4
Mentalis						
Musculi quadrati femoris	*	*	*	*	*	3.7.3.2.1
Musculi tensoris tympani						
Musculi tensoris veli palatini						
Mylohyoideus						
Musculocutaneus	*	*	*	*	*	3.4.3.3.2.2
Nasociliares						
Obturatorius	*	*	*	*	*	3.7.3.2.5
Obturatorius accessorius						
Obturatorius internus	*	*	*	*	*	3.7.3.2.1
Occipitalis major						
Occipitalis minor	*	*	*			3.2.3.2
Occipitalis tertius						
Oculomotorius(III)	*	*		*		3.2.3.1
Olfactorii(I)						
Ophthalmicus	*			*		3.2.3.1
Opticus(II)	*	*		*		3.2.3.1
Palatinus major						
Palatini minores						
Parasympathica						
Pectoralis lateralis/medialis	*	*	*	*	*	3.4.3.3.2.1
Perineales						
Petrosus major						
Petrosus minor						
Petrosus profundus						
Phrenicus	*	*	*	*		3.3.3.2
Piriformis	*	*	*	*		3.7.3.2.1

Structure	Homo	Pan	Gorilla	Pongo	Hylobates	Section
Plantaris lateralis	*	*	*	*	*	3.7.3.2.9.1.2
Plantaris medialis	*	*	*	*	*	3.7.3.2.9.1.1
Plexus brachialis	*	*	*	*	*	3.4.3.3
Plexus dentalis inferior						
Plexus dentalis superior						
Plexus intraparotideus						
Plexus lumbalis	*	*	*	*	*	3.7.3.1
Plexus lumbosacralis	*	*	*	*	*	3.7.3.1
Plexus oesophageus						
Plexus pharyngeus						
Plexus sacralis	*	*	*	*	*	3.7.3.1
Plexus tympanicus						
Pterygoideus lateralis						
Pterygoideus medialis						
Pudendus	*	*	*			3.6.3.3
Radialis	*	*	*	*	*	3.4.3.3.2.6
Rectales inferiores						
Saccularis						
Saphenus						
Scrotales anteriores						
Scrotales posteriores						
Stapedius						
Subclavius						
Subcostalis	*	*	*			3.3.3.1
Sublingualis						
Suboccipitalis						
Subscapulares	*	*	*	*	*	3.4.3.3.2.8
Supraclaviculares	*	*	*			3.3.3.2
Supraorbitalis						
Suprascapularis	*	*	*	*	*	3.4.3.3.1
Suralis						
Sympathetica						
Ganglion cervicale medium	*	*				3.2.3.3
Ganglion cervicale superius						
Ganglion cervicothoracicum	*	*				3.2.3.3
Ganglion lumbalia						
Ganglion sacralia	*	*	*	*	*	3.6.3.4
Ganglion thoracica						
Plexus caroticus internus	*	*				3.2.3.3
Temporalis profundi						
Thoracici						
Thoracicus longus	*	*	*	*	*	3.4.3.3.1
Thoracodorsalis	*		*			3.4.3.3.2.8
Tibialis	*	*	*	*	*	3.7.3.2.9.1
Transversus colli	*	*	*			3.2.3.2
Trigeminus(V)	*			*		3.2.3.1
Trochlearis(IV)	*	*				3.2.3.1
Tympanicus						
Ulnaris	*	*	*	*	*	3.4.3.3.2.5
Utricularis						
Utriculoampullaris						
Vagus(X)	*	*	*	*		3.2.3.1
Vestibularis						
Vestibulocochlearis(VIII)						
Zygomaticus						

Structure	<i>Homo</i>	<i>Pan</i>	<i>Gorilla</i>	<i>Pongo</i>	<i>Hylobates</i>	Section
<b>PERICARDIUM</b>	*	*	*	*	*	3.3.2.1.1
Cavitas pericardialis						
Sinus obliquus pericardii	*		*			3.3.2.1.1
Sinus transversus pericardii	*		*			3.3.2.1.1
Pericardium fibrosum						
Ligamenta sternopericardiaca						
Pericardium serosum						
Lamina parietalis						
Lamina visceralis						
<b>PERITONEUM</b>						
Bursa omentalis						
Cavitas peritonealis						
Foramen omentale						
Ligamenta hepatis						
Ligamentum coronarium						
Ligamentum falciforme						
Ligamentum hepatorenale						
Ligamentum triangulare dextrum						
Ligamentum triangulare sinister						
Mesenterium						
Mesocolon						
Omentum majus						
Ligamentum gastrocolicum						
Ligamentum gastrophrenicum						
Ligamentum gastrosplenicum						
Ligamentum splenorenale						
Omentum minus						
Ligamentum hepatogastricum						
Ligamentum hepatoduodenale						
Peritoneum parietale anterius						
Fossa inguinalis lateralis						
Fossa inguinalis medialis						
Fossa paravesicalis						
Fossa supravesicalis						
Plica umbilicis lateralis						
Plica umbilicis medialis						
Plica umbilicis mediana						
Plica vesicalis transversa						
Trigonum inguinal						
Peritoneum urogenitale						
Fossa ovarica						
Fossa paravesicales						
Excavatio rectouterine						
Excavatio rectovesicalis						
Excavatio vesicouterina						
Ligamenta latum uteri	*	*	*	*	*	3.6.5.2.2.3
Mesometrium						
Mesovarium						
Mesosalpinx	*	*	*		*	3.6.5.2.2.2
Ligamenta suspensorium ovarii						
Peritoneum viscerale						
Plicae et fossae						
Fascia retinens rostralis						
Plica caecalis vascularis						
Plicae caecales						

## Structure

## Homo Pan Gorilla Pongo Hylobates Section

Plica duodenalis inferior  
 Plica duodenalis superior  
 Plica ileocaecalis  
 Recessus duodenalis inferior  
 Recessus duodenalis superior  
 Recessus hepatorenalis  
 Recessus ileocaecalis inferior  
 Recessus ileocaecalis superior  
 Recessus intersigmoideus  
 Recessus retrocaecalis  
 Recessus subhepatici  
 Recessus subphrenici  
 Sulci paracolici

Spatium extraperitoneale

**RESPIRATORY SYSTEM**

## Bronchi

Bronchus principalis	*		*			3.3.5.2
Bronchi lobares et segmentales						
Rami bronchiales segmentorum						
Tela submucosa						
Tunica mucosa						
Tunica muscularis						

## Cavitas nasi

Agger nasi						
Atrium meatus medii						
Bulla ethmoidalis						
Choanae						
Hiatus semilunaris						
Infundibulum ethmoidale						
Limen nasi						
Meatus nasi inferior						
Meatus nasi medius						
Meatus nasi superior						
Meatus nasopharyngeus						
Nares						
Organum vomeronasale						
Plexus cavernosi concharum						
Recessus sphenoidalis						
Septum nasi	*	*	*	*	*	3.2.5.1.1
Sulcus olfactorius						

## Cavitas laryngis

Aditus laryngis						
Cavitas infraglottica						
Conus elasticus						
Glottis						
Ligamentum vestibulare	*	*	*	*		3.2.5.2
Ligamentum vocale	*	*		*	*	3.2.5.2
Membrana quadrangularis	*	*				3.2.5.2
Rima glottidis	*	*				3.2.5.2
Rima vestibuli						
Sacculus laryngis						
Tunica mucosa						
Ventriculus laryngis						
Vestibulum laryngis						

Structure	Homo	Pan	Gorilla	Pongo	Hylobates	Section
Larynx						
Cartilago arytenoidea	*	*		*		3.2.5.2.2
Capsula articularis cricoarytenoidea						
Ligamentum cricoarytenoideum posterius						
Ligamentum cricopharyngeum						
Cartilago corniculata	*	*		*		3.2.5.2.2
Cartilago cricoidea	*	*	*	*		3.2.5.2.2
Ligamentum ceratocricoideum						
Ligamentum cricothyroideum medianum	*	*		*		3.2.5.2.2
Ligamentum cricotracheale	*	*		*		3.2.5.2.2
Cartilago cuneiformis	*	*	*	*	*	3.2.5.2.2
Cartilago thyroidea	*	*	*	*	*	3.2.5.2.2
Cartilago triticea		*		*		3.2.5.2.2
Membrana thyrohyoidea	*	*		*		3.2.5.2.2
Epiglottis						
Ligamentum hyoepiglotticum	*	*				3.2.5.2.2
Ligamentum thyroepiglotticum						
Nasus externus						
Alae nasi						
Apex nasi						
Cartilago alares minores						
Cartilago alaris major	*	*	*	*	*	3.2.5.1.1
Cartilago nasales accessoriae		*	*	*		3.2.5.1.1
Cartilago nasi lateralis						
Cartilago septi nasi	*	*	*	*	*	3.2.5.1.1
Cartilago vomeronasalis						
Pars mobilis septi nasi						
Radix nasi						
Pulmones						
Apex pulmonis						
Basis pulmonis						
Bronchioli						
Facies costalis						
Facies diaphragmatica						
Facies interlobaris						
Facies mediastinalis						
Fissura horizontalis						
Fissura obliqua						
Hilum pulmonis						
Incisura cardiaca						
Lingula pulmonaris sinistri						
Lobus inferior						
Lobus medius						
Lobus superior						
Margo anterior						
Margo inferior						
Pleura	*		*			3.3.5.5
Pulmo dexter	*	*	*	*	*	3.3.5.4
Pulmo sinister	*	*	*	*	*	3.3.5.3
Radix pulmonalis						
Recessus costodiaphragmaticus						
Recessus costomediastinalis						
Recessus phrenicomediastinalis						
Segmenta bronchopulmonalia						

Structure	Homo	Pan	Gorilla	Pongo	Hylobates	Section
Trachea						
Bifurcatio trachea	*		*			3.3.5.1
Carina trachea						
Cartilagine tracheales	*		*			3.3.5.1
Lig.annularia						
Paries membranaceus						
Pars cervicalis						
Pars thoracica						
Tunica mucosa						
<b>SENSORY ORGANS</b>						
Ear						
Auricula	*	*	*	*	*	3.2.7.1
Labyrinthus cochlearis						
Labyrinthus membranaceus						
Labyrinthus vestibularis						
Ligamenta auricularia						
Ligamentum ossiculorum auditus						
Meatus acusticus externus						
Membrana tympani	*	*				3.2.7.1.1
Pars cartilaginea tubae auditive						
Tunica mucosa cavitatis tympani						
Vasa auris internae						
Eye						
Apparatus lacrimalis	*	*		*		3.2.7.2.2.3
Camera anterior bulbi						
Camera posterior bulbi						
Camera vitrea bulbi						
Choroidea	*	*				3.2.7.2.1
Cornea	*	*	*	*		3.2.7.2.1
Corpus ciliare						
Iris						
Lens						
Ligamentum palpebrale laterale						
Ligamentum palpebrale mediale						
Palpebra inferior/superior	*	*		*		3.2.7.2.2.2
Pupilla						
Raphe palpebralis lateralis						
Retina	*	*				3.2.7.2.1
Sclera						
Tarsus						
Tunica conjunctiva	*	*		*		3.2.7.2.2.2
Tunica fibrosa bulbi						
Tunica interna bulbi						
Tunica vasculosa bulbi						
Vasa sanguinea retinae						
<b>UROGENITAL SYSTEM</b>						
Ren	*	*	*	*	*	3.6.5.1.1
Area cribrosa						
Arteriae renis						
Capsula adiposa						
Capsula fibrosa						
Columnae renales						
Cortex renalis						
Extremitas inferior						

Structure	Homo	Pan	Gorilla	Pongo	Hylobates	Section
Extremitas superior						
Facies anterior						
Facies posterior						
Fascia renalis						
Hilum renale						
Margo lateralis						
Margo medialis						
Medulla renalis						
Lobi renales						
Papillae renales	*	*	*	*	*	3.6.5.1.1
Pelvis renalis						
Pyramides renales	*	*	*	*	*	3.6.5.1.1
Segmenta renalia						
Sinus renalis						
Venae renis						
Ureter	*		*	*		3.6.5.1.2
Pars abdominalis						
Pars pelvica						
Tunica adventitia						
Tunica mucosa						
Tunica muscularis						
Vesica urinaria	*		*			3.6.5.1.3
Apex vesicae						
Cervix vesicae						
Corpus vesicae						
Fundus vesicae						
Ligamentum umbilicale medianum						
Tela submucosa						
Tela subserosa						
Trigonum vesicae						
Tunica mucosa						
Tunica muscularis						
Tunica serosa						
Uvula vesicae						
<b>Organa genitalia masculina</b>						
<b>  Interna</b>						
Ductus deferens	*	*	*	*	*	3.6.5.2.1.2
Ampulla ductus deferens						
Ductus ejaculatorius	*	*	*			3.6.5.2.1.2
Tunica adventitia						
Tunica mucosa						
Tunica muscularis						
Epididymis	*		*		*	3.6.5.2.1.1
Caput epididymidis	*		*		*	3.6.5.2.1.1
Cauda epididymidis	*		*		*	3.6.5.2.1.1
Corpus epididymidis						
Ductulis aberrantes						
Ductus epididymidis						
Lobuli epididymidis						
Paradidymis						
Funiculus spermaticus			*		*	3.6.5.2.1.2
Fascia cremasterica						
Fascia spermatica externa						
Fascia spermatic interna						
Glandula bulbourethralis	*	*	*	*	*	3.6.5.2.1.3

Structure	Homo	Pan	Gorilla	Pongo	Hylobates	Section
Prostata	*	*	*	*	*	3.6.5.2.1.3
Apex prostatae	*		*		*	3.6.5.2.1.3
Basis prostatae	*				*	3.6.5.2.1.3
Capsula prostatici						
Ductuli prostatici						
Facies anterior						
Facies inferolateralis						
Facies posterior						
Isthmus prostatae	*	*			*	3.6.5.2.1.3
Lobus dexter/sinister/medius						
Parenchyma						
Substantia muscularis						
Testis	*	*	*	*	*	3.6.5.2.1.1
Ductuli efferentes testis						
Lobuli testis						
Mediastinum testis						
Parenchyma testis						
Rete testis						
Septula testis						
Tubuli seminiferi contorti						
Tubuli seminiferi recti						
Tunica albuginea						
Tunica vaginalis testis	*	*	*	*	*	3.6.5.2.1.1
Vesicula seminalis	*		*	*	*	3.6.5.2.1.3
Ductus excretorius						
Tunica adventitia						
Tunica mucosa						
Tunica muscularis						
<b>Organa genitalia masculina</b>						
<b>    Externa</b>						
Penis	*	*	*	*	*	3.6.5.2.1.5.1
Arteriae helicinae						
Bulbus penis						
Cavernae corporis spongiosi						
Cavernae corporum cavernosum						
Corpus cavernosum penis	*	*	*		*	3.6.5.2.1.5.1
Corpus penis	*	*	*	*	*	3.6.5.2.1.5.1
Corpus spongiosum penis						
Crus penis						
Dorsum penis						
Facies urethralis						
Fascia penis profunda						
Fascia penis superficialis						
Glandulae preputiales						
Glans penis	*	*	*	*	*	3.6.5.2.1.5.1
Preputium penis	*	*	*	*	*	3.6.5.2.1.5.1
Tunica albuginea corporis spongiosi						
Tunica albuginea corporum cavernosorum						
Trabeculae corporis spongiosi						
Trabeculae corporum cavernosorum						
Venae cavernosae						
Urethra masculina	*	*	*		*	3.6.5.1.4.1
Lacunae urethrales						
Ostium urethrae externum	*	*	*		*	3.6.5.2.1.5.1



Structure		<i>Homo</i>	<i>Pan</i>	<i>Gorilla</i>	<i>Pongo</i>	<i>Hylobates</i>	Section
	Pars membranacea						
	Pars prostatica						
	Pars spongiosa						
Scrotum		*	*	*	*	*	3.6.5.2.1.5.2
	Raphe scroti	*	*	*	*	*	3.6.5.2.1.5.2
	Septum scroti						
	Tunica dartos						
<b>Organa genitalia feminina</b>							
<b>Interna</b>							
Epoöphoron							
Ovarium		*	*	*	*	*	3.6.5.2.2.1
	Corpus albicans						
	Corpus luteum						
	Cortex ovarii						
	Extremitas tubaria						
	Extremitas uterina						
	Facies lateralis						
	Facies medialis						
	Folliculi ovarici primarii						
	Folliculi ovarici vesiculosi						
	Hilum ovarii						
	Ligamentum ovarii proprium	*	*	*	*	*	3.6.5.2.2.1
	Margo liber						
	Margo mesovaricus						
	Medulla ovarii						
	Stroma ovarii						
	Tunica albuginea						
Paroöphoron							
Tuba uterina		*	*	*		*	3.6.5.2.2.2
	Ampulla tubae uterinae	*	*	*			3.6.5.2.2.2
	Fimbriae tubae	*	*	*		*	3.6.5.2.2.2
	Infundibulum tubae uterinae						
	Isthmus tubae uterinae						
	Ostium abdominale tubae uterinae	*		*			3.6.5.2.2.2
	Ostium uterinum tubae	*		*			3.6.5.2.2.2
	Pars uterina						
	Plicae tubariae						
	Tela subserosa						
	Tunica mucosa						
	Tunica muscularis	*		*			3.6.5.2.2.2
	Tunica serosa						
Uterus		*	*	*	*	*	3.6.5.2.2.3
	Canalis cervicis uteri						
	Cavitas uteri						
	Cervix uteri	*	*	*	*	*	3.6.5.2.2.3
	Cornu uteri						
	Corpus uteri						
	Facies intestinalis						
	Facies vesicalis						
	Fundus uteri	*	*	*		*	3.6.5.2.2.3
	Isthmus uteri						
	Ligamentum teres uteri	*	*	*		*	3.6.5.2.2.3
	Margo uteri						
	Ostium uteri						
	Paracervix						

Structure	Homo	Pan	Gorilla	Pongo	Hylobates	Section
Parametrium						
Tela subserosa						
Tunica mucosa[Endometrium]						
Tunica muscularis[Myometrium]	*	*	*			3.6.5.2.2.3
Tunica serosa[Perimetrium]						
Vagina	*	*	*	*	*	3.6.5.2.2.4
Fornix vaginae	*	*	*		*	3.6.5.2.2.4
Hymen	*	*	*			3.6.5.2.2.4
Tunica mucosa						
Tunica muscularis						
Tunica spongiosa						
<b>Organa genitalia feminina</b>						
<b>Externa</b>						
Bulbus vestibuli	*	*	*	*		3.6.5.2.2.4
Clitoris	*	*	*		*	3.6.5.2.2.5.1
Corpus cavernosum clitoridis	*	*			*	3.6.5.2.2.5.1
Corpus clitoridis	*	*	*		*	3.6.5.2.2.5.1
Crus clitoridis						
Fascia clitoridis						
Frenulum clitoridis	*	*	*		*	3.6.5.2.2.5.1
Glans clitoridis	*	*	*		*	3.6.5.2.2.5.1
Preputium clitoridis	*	*	*		*	3.6.5.2.2.5.1
Septum corporum cavernosorum						
Labium majus pudendi	*	*	*	*	*	3.6.5.2.2.5.2
Commissura labiorum anterior						
Commissura labiorum posterior						
Labium minus pudendi	*	*	*	*	*	3.6.5.2.2.5.3
Frenulum labiorum pudendi						
Mons pubis	*	*	*	*	*	3.6.5.2.2.5.3
Ostium vaginae						
Urethra feminina	*	*				3.6.5.1.4.2
Crista urethralis						
Ostium urethrae externum	*	*	*	*	*	3.6.5.1.4.2
Tunica mucosa						
Tunica muscularis						
Tunica spongiosa						
<b>Perineum</b>						
Arcus tendineus fasciae pelvis						
Centrum tendineum perinei						
Diaphragma pelvis						
Fascia diaphragmatis pelvis						
Fascia diaphragmatis pelvis superior						
Fascia pelvis parietalis						
Fascia obturatoria						
Fascia pelvis visceralis						
Fascia peritoneoperinealis						
Fascia prostatae						
Fascia perinei superficialis						
Ligamentum anococcygeum						
Ligamentum puboprostaticum						
Ligamentum transversum perinei						
Membrana perinei						
Musculi perinei						
Raphe perinealis						

Structure	<i>Homo</i>	<i>Pan</i>	<i>Gorilla</i>	<i>Pongo</i>	<i>Hylobates</i>	Section
<b>VEINS</b>						
Anastomotica inferior						
Anastomotica superior						
Angularis						
Anterior septi pellucidi						
Anteriores cerebri						
Appendicularis						
Aqueductus cochleae						
Arcus venae azygos						
Arcus venosus dorsalis pedis	*	*	*	*		3.7.2.2.1.1
Arcus venosus jugularis						
Arcus venosus palmaris profundus						
Arcus venosus palmaris superficialis						
Arcus venosus plantaris						
Articulares anteriores						
Atriales						
Atrioventriculares						
Auricularis posterior						
Axillaris						
Azygos	*	*	*	*	*	3.3.2.3.5
Basilica	*	*	*	*	*	3.4.2.2.1
Basilis						
Basilis communis						
Basilis inferior						
Basilis superior						
Basivertebrales						
Brachialis	*	*	*	*	*	3.4.2.2.2
Brachiocephalica						
Bronchiales						
Bulbi penis						
Bulbi vestibuli						
Bulbus inferior venae jugularis						
Bulbus superior venae jugularis						
Canalis pterygoideus						
Cardiaca magna	*		*			3.3.2.3.2
Cardiaca media	*		*			3.3.2.3.2
Cardiaca parva	*		*			3.3.2.3.2
Cardiacae anteriores	*		*			3.3.2.3.2
Cardiacae minimiae						
Centralis retinae						
Cephalica	*	*	*	*	*	3.4.2.2.1
Cervicalis profundus						
Choroidea inferior						
Choroidea superior						
Ciliares						
Ciliares anteriores						
Circumflexa iliac profunda						
Circumflexa superficialis ilium						
Circumflexae mediales femoris						
Circumflexae laterales femoris						
Colica dextra						
Colica media						
Colica sinistra						
Comitans nervi hypoglossi						
Conjunctivales						
Cystica						

**Structure****Homo Pan Gorilla Pongo Hylobates Section**

Digitales palmares					
Digitales plantares					
Diploica frontalis					
Diploica occipitalis					
Diploica temporalis anterior					
Diploica temporalis posterior					
Directae laterales					
Dorsales superficiales clitoridis					
Dorsales superficiales penis					
Dorsalis corporis callosi					
Dorsalis linguae					
Dorsalis profunda clitoris					
Dorsalis profunda penis					
Emissaria condylaris					
Emissaria mastoidea					
Emissaria occipitalis					
Emissaria parietalis					
Epigastrica inferior					
Epigastrica superficialis					
Epigastricae superioris					
Episclerales					
Ethmoidales					
Facialis	*			*	3.2.2.2.4
Femoralis					
Fibulares					
Frontales					
Gastrica dextra					
Gastrica sinistra					
Gastricae breves					
Gastro-omentalis dextra					
Gastro-omentalis sinistra					
Geniculares					
Gluteae inferioris					
Gluteae superioris					
Gyri olfactorii					
Hemiazygos	*	*	*	*	3.3.2.3.5
Hemiazygos accessoria	*	*	*	*	3.3.2.3.5
Hepaticae dextrae					
Hepaticae intermediae					
Hepaticae sinistrae					
Ileales					
Ileocolica					
Iliaca communis					
Iliaca externa					
Iliaca interna					
Iliolumbalis					
Inferior vermis					
Inferiores cerebri					
Inferiores hemispherii cerebelli					
Insulares					
Intercapitulares					
Intercostales anteriores					
Intercostales posteriores					
Intercostalis superior dextra					
Intercostalis superior sinistra					
Intercostalis suprema					

Structure	Homo	Pan	Gorilla	Pongo	Hylobates	Section
Intermedia antebrachii						
Intermedia basilica						
Intermedia cephalica						
Intermedia cubitii						
Internae cerebri						
Intervertebralis						
Jejunales						
Jugularis anterior	*			*		3.2.2.2.1
Jugularis externa	*	*		*		3.2.2.2.1
Jugularis interna	*	*	*	*		3.2.2.2.2
Labiales anteriores						
Labiales posteriores						
Labialis inferiores						
Labialis superiores						
Labyrinthi						
Lacrimalis						
Laryngea inferior						
Laryngea superior						
Lateralis atrii						
Lingualis						
Lumbales						
Lumbalis ascendens						
Magna cerebri						
Marginalis lateralis	*	*	*	*		3.7.2.2.1.1
Marginalis medialis	*	*	*	*		3.7.2.2.1.1
Maxillares						
Mediastinales						
Media profunda cerebri						
Mediae superficiales cerebri						
Medialis atrii						
Mediastinales						
Medulla oblongatae						
Meningeae						
Meningeae mediae						
Mesenterica inferior						
Mesenterica superior						
Metacarpales dorsales						
Metacarpales palmares						
Metatarsales plantares						
Musculophrenicae						
Nasales externae						
Nuclei caudati						
Obliqua atrii sinistri						
Obturatoriae						
Occipitales						
Occipitalis						
Oesophageales						
Ophthalmica inferior						
Ovarica dextra						
Palatina externa						
Palpebrales						
Palpebrales inferiores						
Palpebrales superiores						
Pancreaticae						
Pancreaticoduodenales						
Paraumbilicales						

Structure	Homo	Pan	Gorilla	Pongo	Hylobates	Section
Parietales						
Parotideae						
Pectorales						
Pedunculares						
Perforantes	*	*	*	*	*	3.4.2.2.3
Pericardiacae						
Pericardiacophrenicae						
Pericardiales						
Petrosa						
Pharyngeales						
Phrenicae inferiores						
Phrenicae superiores						
Plexus pampiniformis						
Plexus pharyngeus						
Plexus pterygoideus	*	*				3.2.2.2.4
Plexus venosus areolaris						
Plexus venosus canalis hypoglossi						
Plexus venosus caroticus internus						
Plexus venosus foraminis ovalis						
Plexus venosus prostaticus						
Plexus venosus rectalis						
Plexus venosus sacralis						
Plexus venosus suboccipitali						
Plexus venosus uterinus						
Plexus venosus vaginalis						
Plexus venosus vertebralis externus anterior						
Plexus venosus vertebralis externus posterior						
Plexus venosus vertebralis internus anterior						
Plexus venosus vertebralis internus posterior						
Plexus venosus vesicalis						
Pontis						
Pontomesencephalica anterior	*	*	*			3.6.2.2.2
Porta hepatis	*	*	*			
Posterior corporis callosi						
Posterior septi pellucidi						
Posterior ventriculi sinistri	*		*			3.3.2.3.2
Precentralis cerebelli						
Prefrontales						
Prepylorica						
Profunda faciei						
Profunda femoris						
Profunda linguae						
Profundae cerebri						
Profundae clitoridis						
Profundae penis						
Pudenda externae						
Pudenda interna						
Pulmonalis dextra inferior	*	*		*	*	3.3.2.3.1
Pulmonalis dextra superior	*	*		*	*	3.3.2.3.1
Pulmonalis sinistra inferior	*	*		*	*	3.3.2.3.1
Pulmonalis sinistra superior	*	*		*	*	3.3.2.3.1
Radiales	*	*	*	*	*	3.4.2.2.2

Structure	<i>Homo</i>	<i>Pan</i>	<i>Gorilla</i>	<i>Pongo</i>	<i>Hylobates</i>	Section
Recessus lateralis ventriculi quarti						
Rectales inferiores						
Rectales mediae						
Rectalis superior						
Rete venosum dorsale manus						
Rete venosum dorsale pedis						
Sacralis laterales						
Sacralis mediana						
Saphena accessorius						
Saphena parva	*	*	*	*		3.7.2.2.1.3
Saphena magna	*	*	*	*		3.7.2.2.1.2
Scapularis dorsalis						
Scrotales anteriores						
Scrotales posteriores						
Sigmoideae						
Sinus cavernosus	*	*		*	*	3.2.2.3
Sinus coronarius	*		*			3.3.2.3.2
Sinus occipitalis						
Sinus petrosquamosus	*	*		*	*	3.2.2.2.3
Sinus petrosus inferior						
Sinus rectus						
Sinus sagittalis inferior						
Sinus sagittalis superior						
Sinus sigmoideus						
Sinus sphenoparietalis	*	*	*	*	*	3.2.2.2.3
Sinus transversus						
Spinales anteriores/posteriores						
Splenica						
Sternocleidomastoidea						
Stylomastoidea						
Subclavia						
Subcostalis						
Subcutaneae abdominis						
Sublingualis						
Submentalis						
Superficialis cerebri						
Superior vermis						
Superiores cerebri						
Superiores hemispherii cerebelli						
Supraorbitalis						
Suprarenalis dextra						
Suprarenalis sinistra						
Suprascapularis						
Supratrochleares						
Temporales profundae						
Temporales superficiales						
Temporalis media						
Testicularis dextra						
Thalamostriatae inferiores						
Thalamostriatae superior						
Thoracica lateralis						
Thoracicae internae						
Thoracicoepigastricae						
Thoracoacromialis						
Thymicae						
Thyroidea inferior						

<b>Structure</b>	<b>Homo</b>	<b>Pan</b>	<b>Gorilla</b>	<b>Pongo</b>	<b>Hylobates</b>	<b>Section</b>
Thyroidea mediae						
Thyroidea superior	*	*		*		3.2.2.2.2
Thyroideus impar						
Tibialis anteriores						
Tibialis posteriores						
Tracheales						
Transversa faciei						
Transversae cervicis						
Tympanicae						
Ulnares	*	*	*	*	*	3.4.2.2.2
Umbilicalis sinistra						
Unci						
Uterinae						
Vena cava inferior	*	*		*		3.3.2.3.4
Vena cava superior	*	*		*		3.3.2.3.3
Ventriculares						
Ventricularis inferior						
Vertebralis						
Vertebralis anterior						
Vesicales						
Vorticosae						